

# ACTUALIZACIÓN EN PATOLOGÍA FÚNGICA. MORFOPATOLOGÍA DE LAS MICOSIS SUBCUTÁNEAS Y SISTÉMICAS

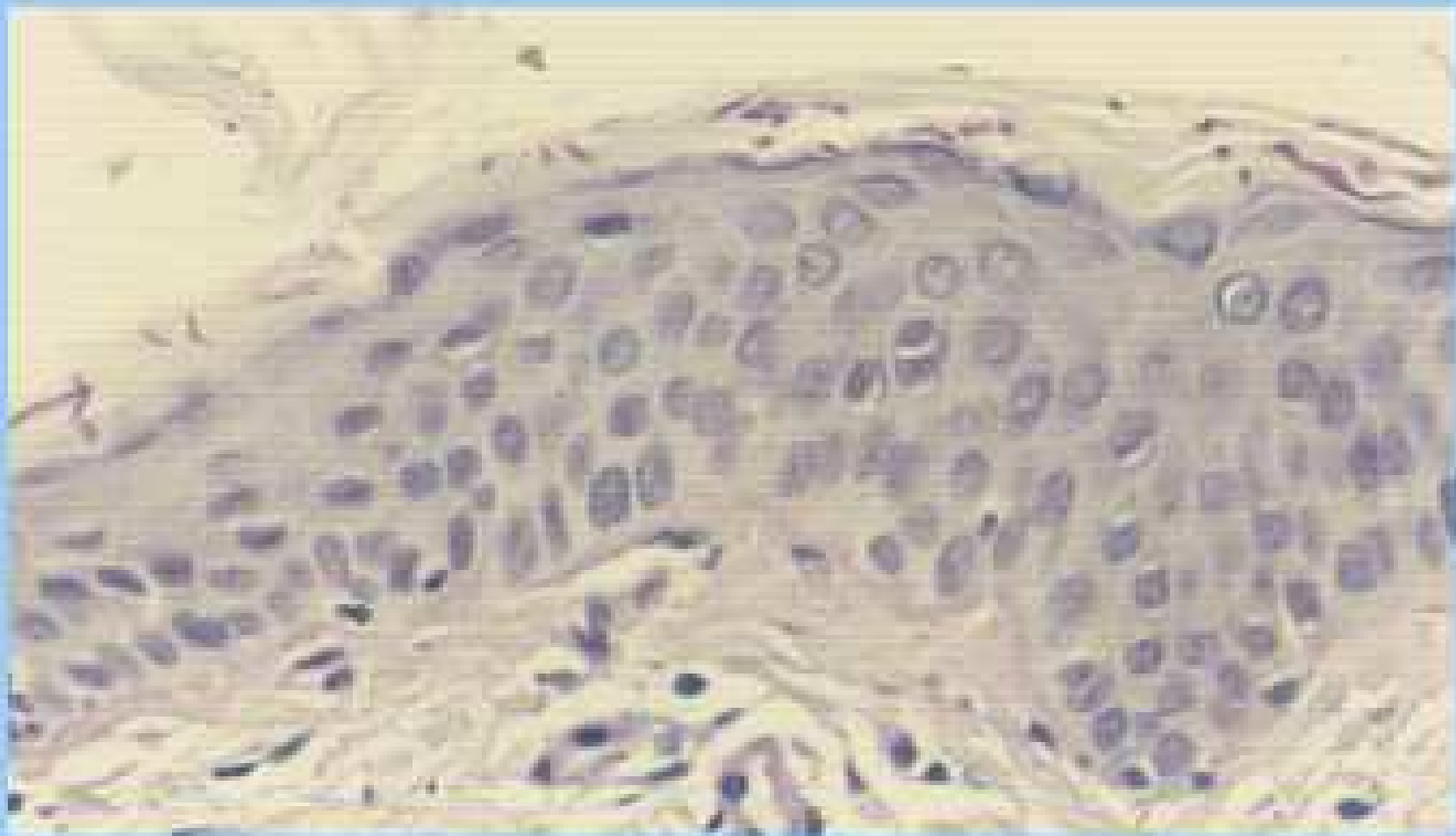
DR. EMILIO MAYAYO ARTAL  
HOSPITAL UNIVERSITARIO  
JUAN XXIII TARRAGONA  
UNIVERSIDAD ROVIRA Y VIRGILI



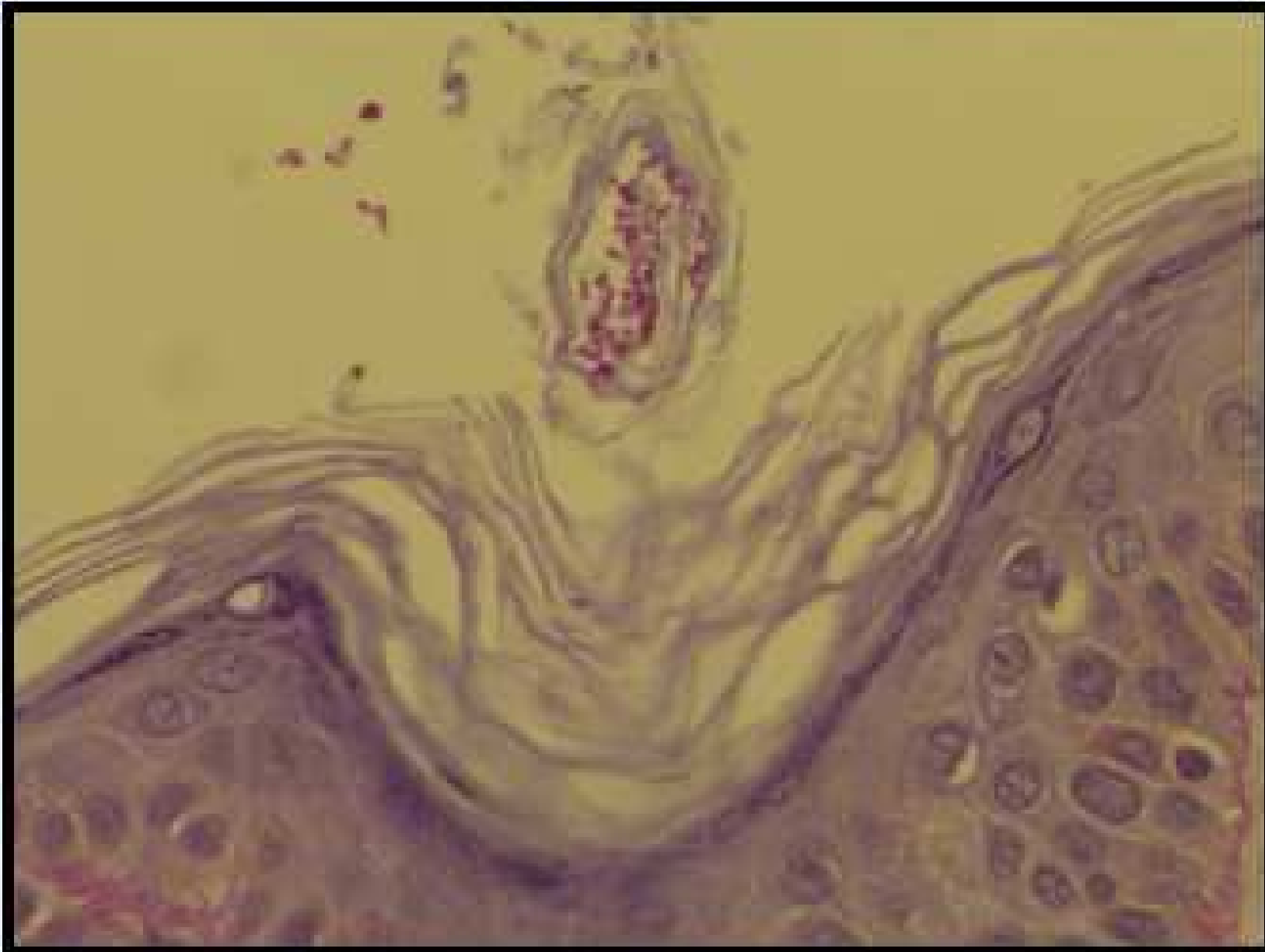
# HONGOS



- **LESIONES POR HONGOS:**
  - ENVENENAMIENTO.
  - MICOTOXICOSIS.
  - HIPERSENSIBILIDAD.
  - **MICOSIS** (Superf/Sistémicas)

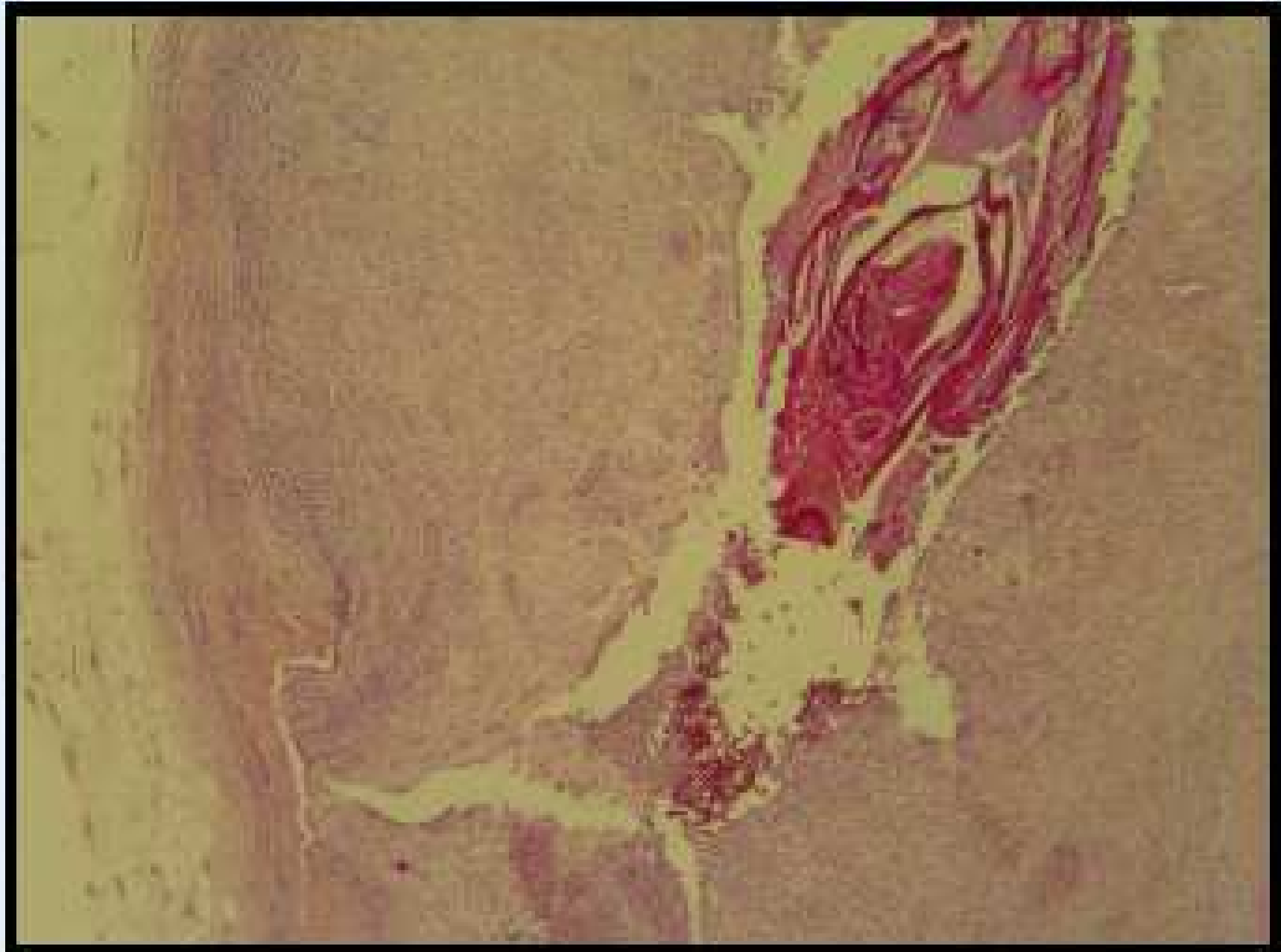


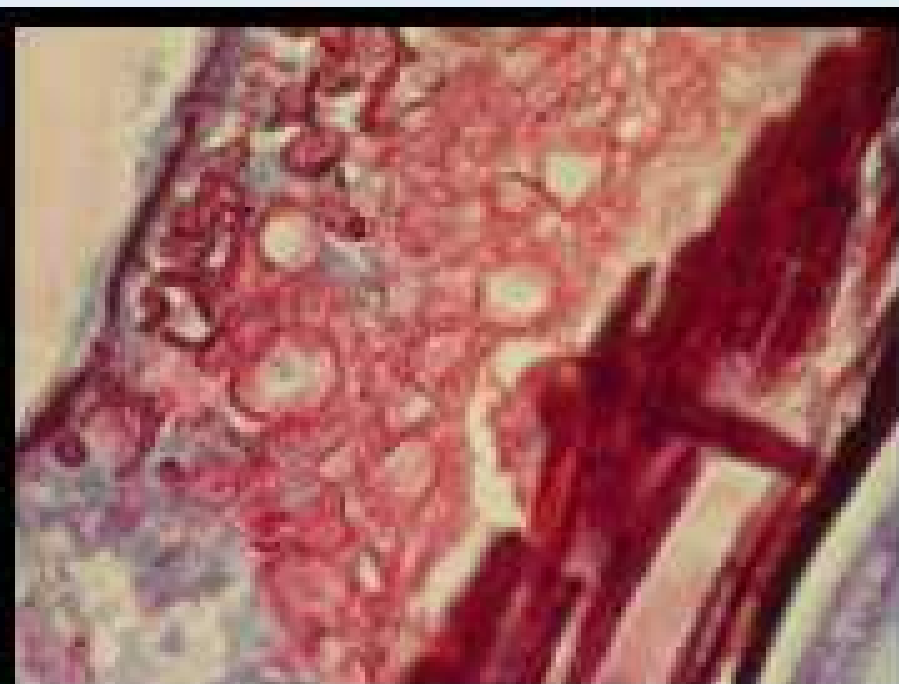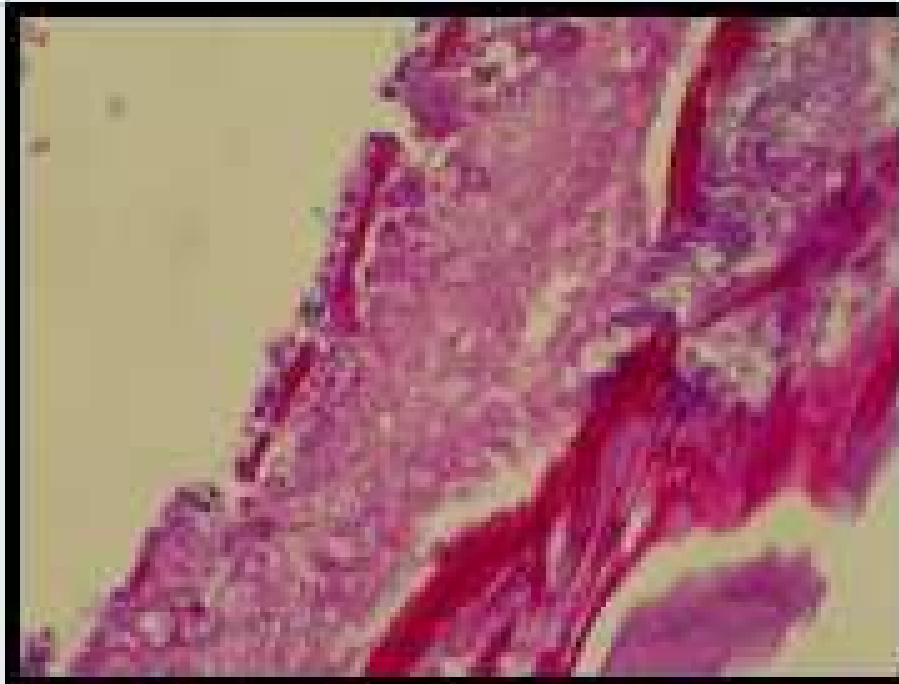
**Biopsia de piel mostrando micosis superficial. En la capa córnea de epidermis se observan varias hifas. P.A.S. X100.**

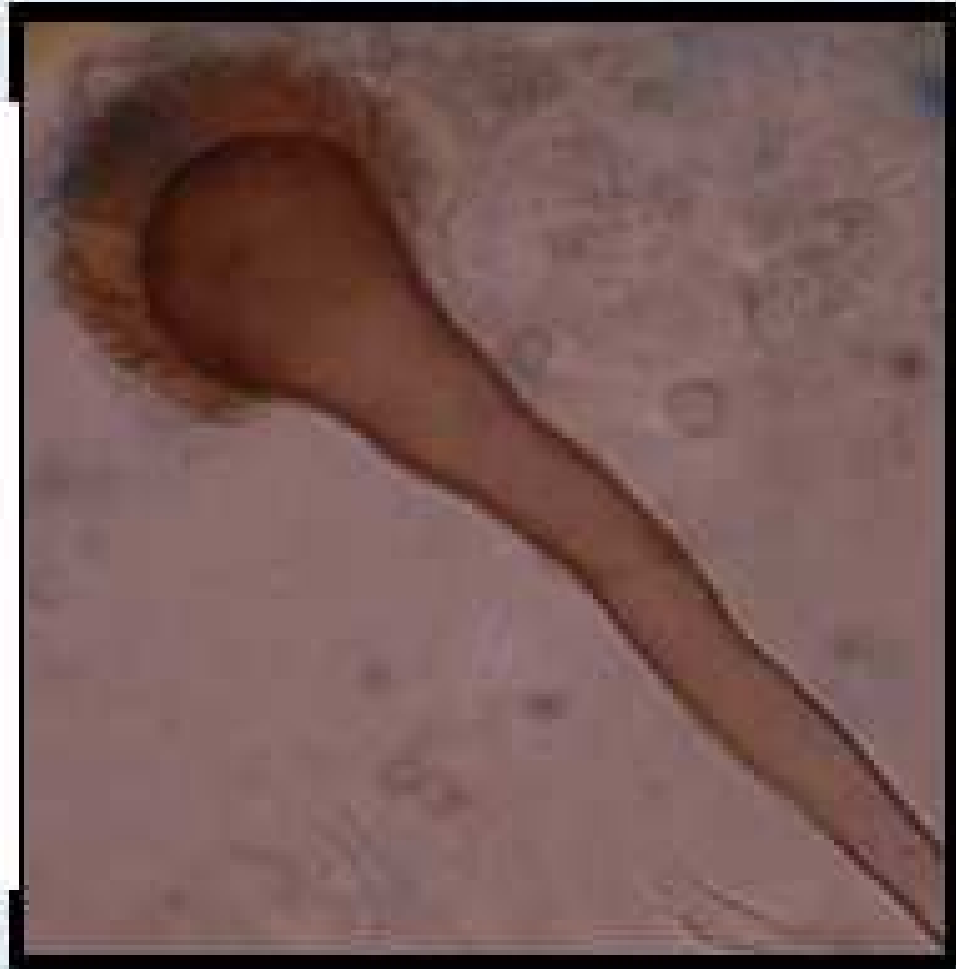

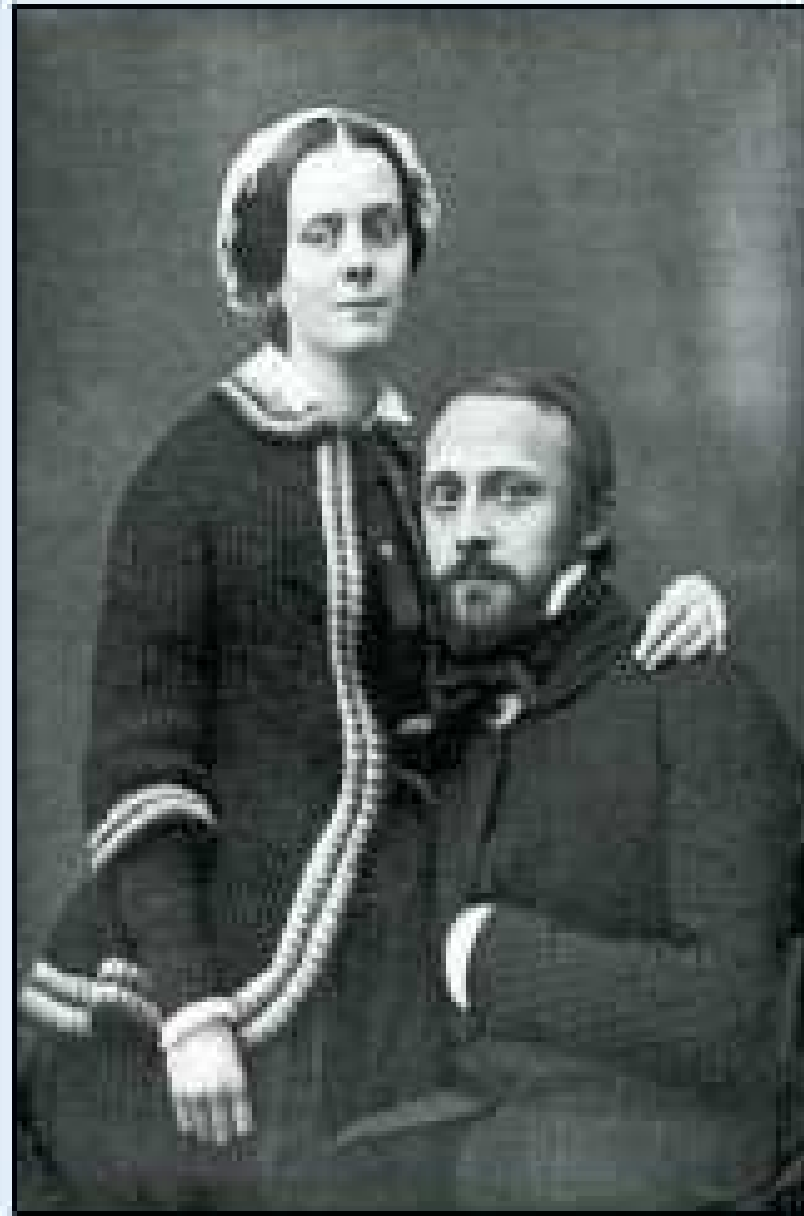# MICOSIS

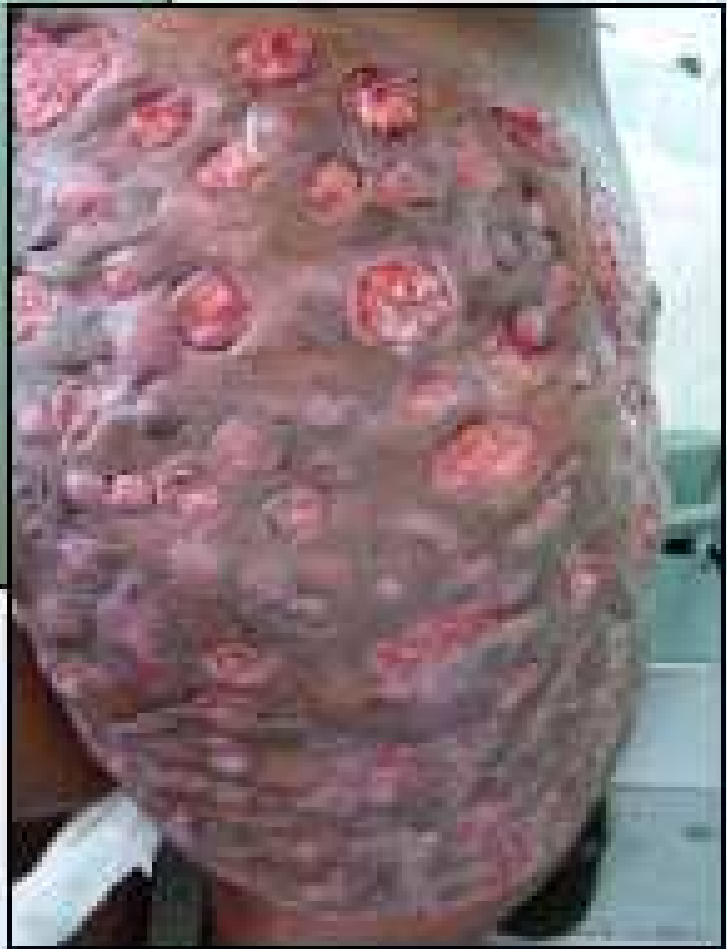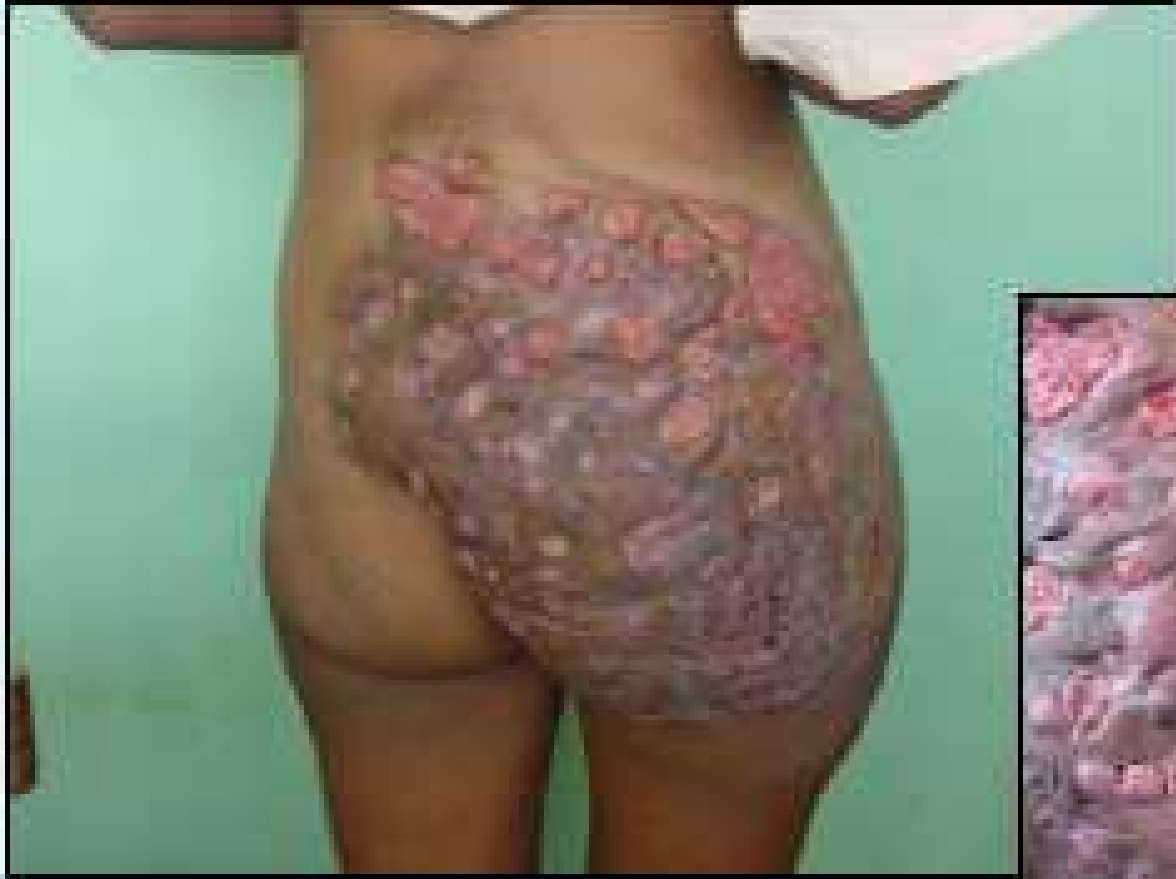- **LESIÓN INTERCELULAR:**
  - ACCIÓN TÓXICA.
  - ACCIÓN IRRITATIVA.
  - POR HIPERSENSIBILIDAD.
  - **OCUPANTE DE ESPACIO.**

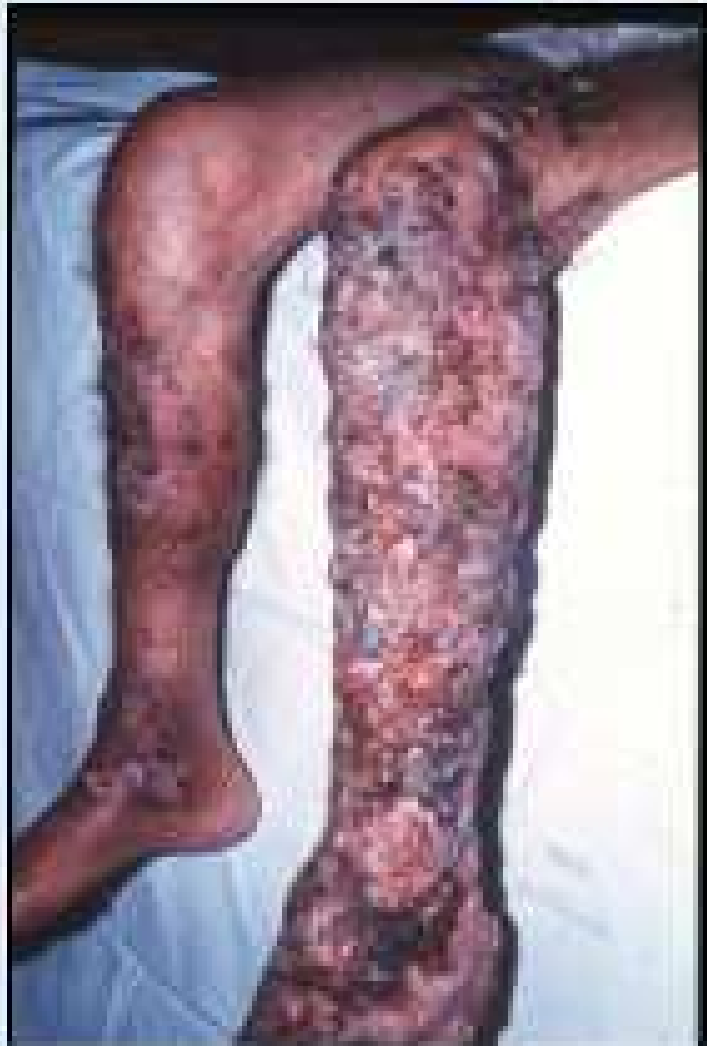
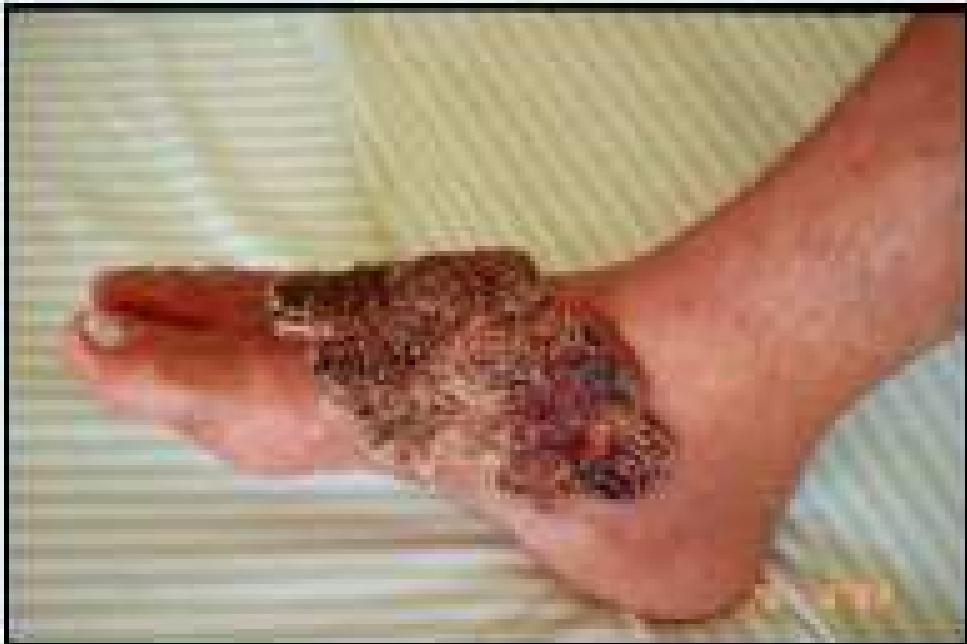
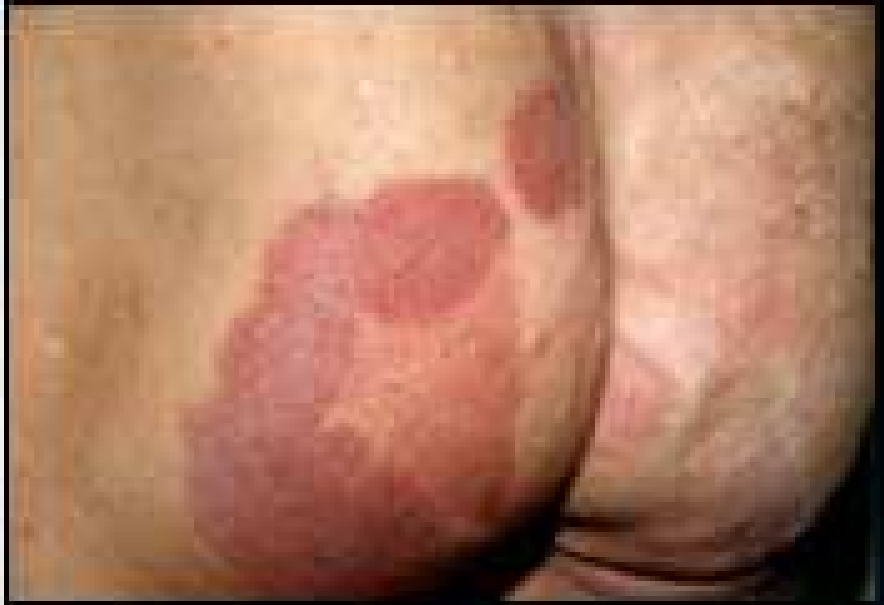

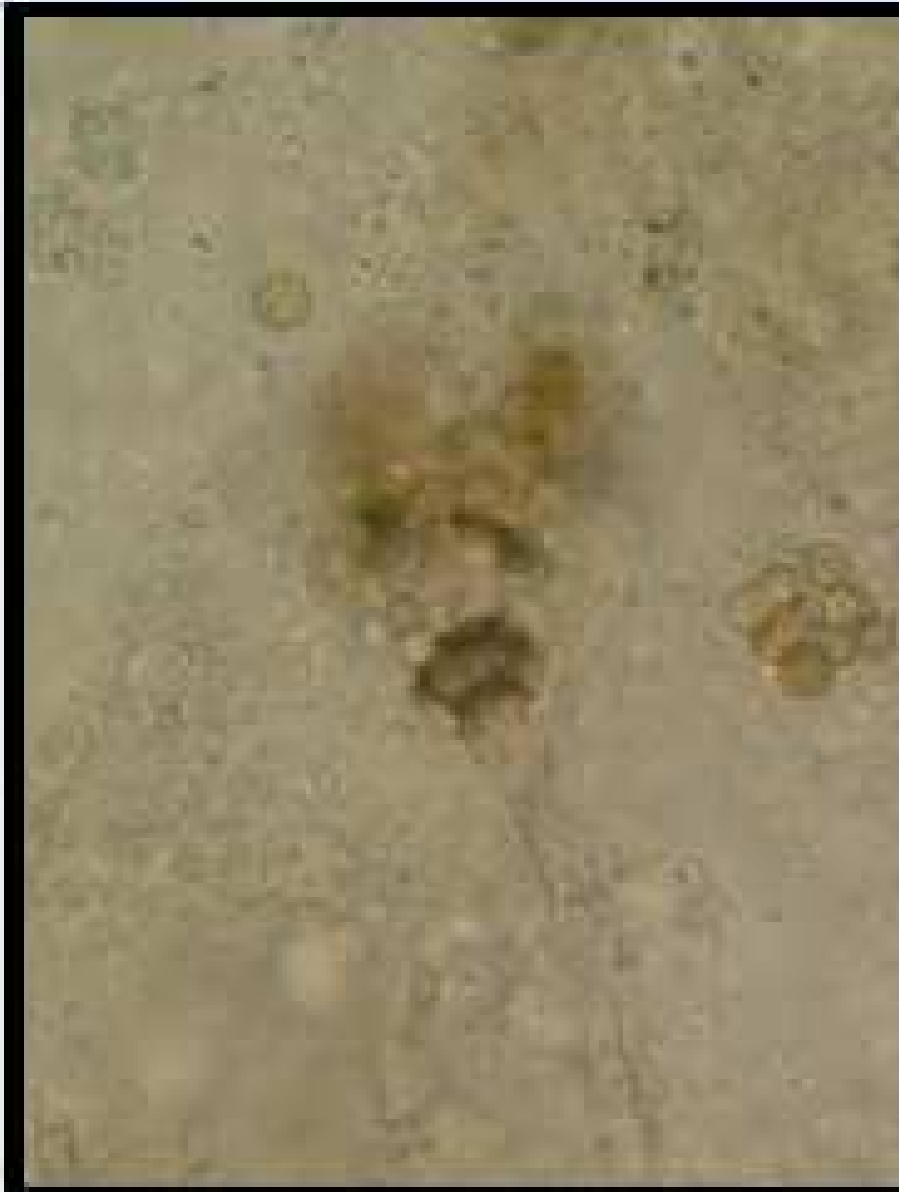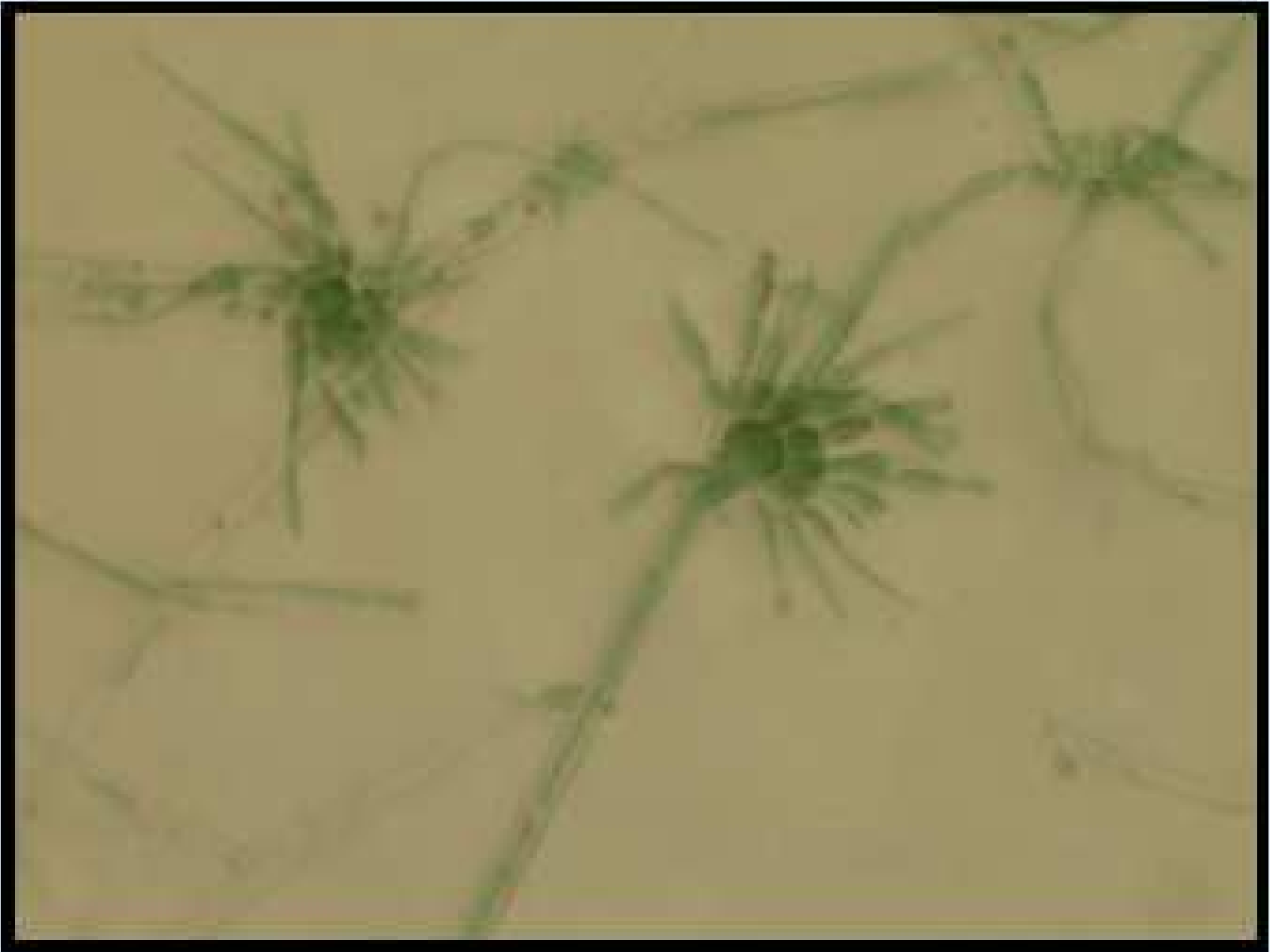




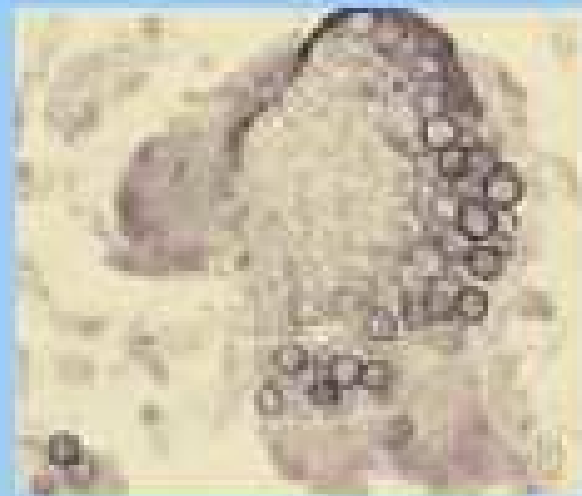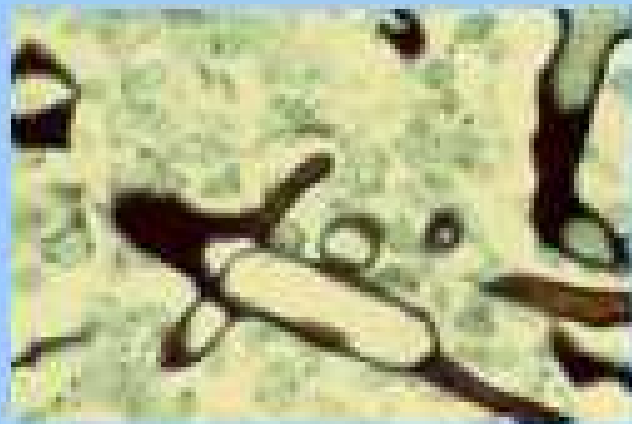
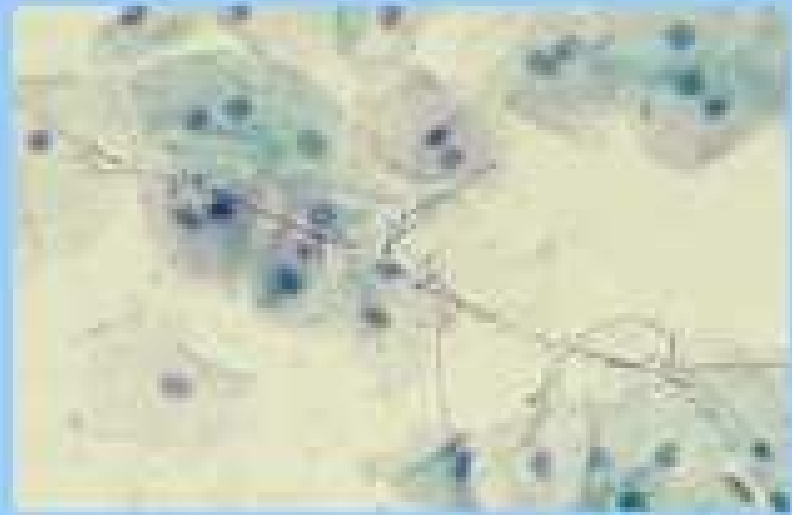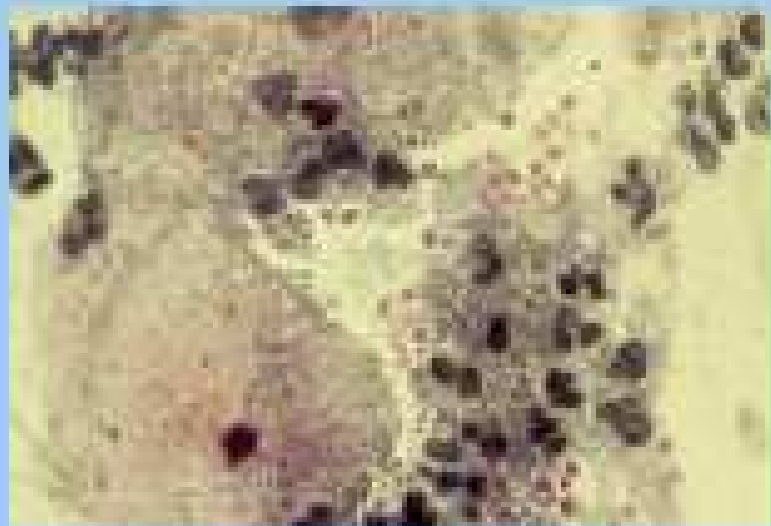








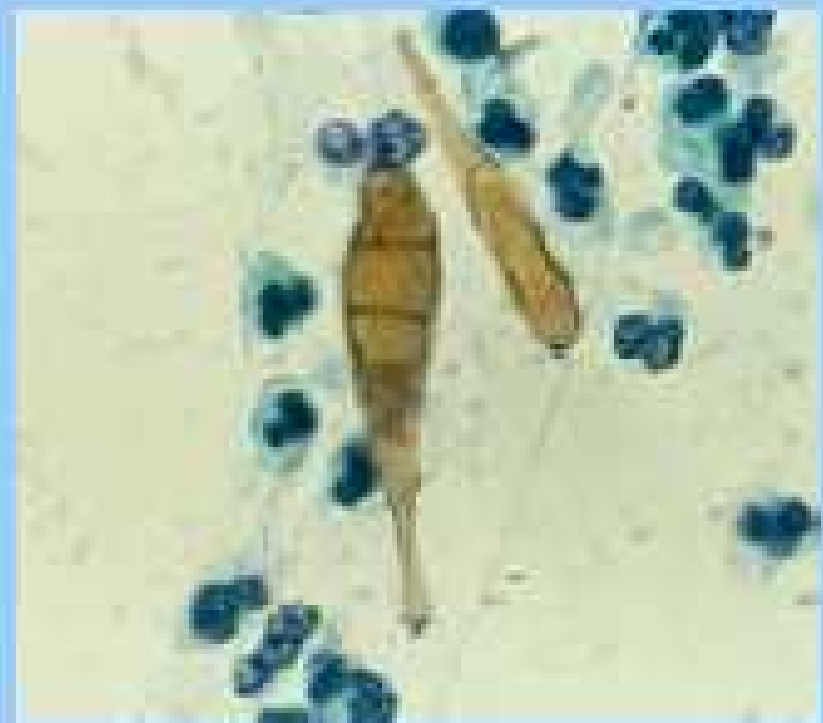# FORMAS MICÓTICAS



# CITOLOGÍA



ASPERGILLUS



ALTERNARIA

# MICOSIS

- **LA MORFOLOGÍA ES DIAGNÓSTICA:**

- CANDIDA.
- ASPERGILLUS.
- ZIGOMICETOS.
- CRYPTOCOCO.
- PNEUMOCYSTIS.
- SPOROTHRIX.
- BLASTOMICES.
- HISTOPLASMA.
- COCCIDIOIDOM.
- PARACOCCIDIO.
- PENICILIUM.
- CROMOBLASTO.

# TÉCNICAS


- HISTOQUÍMICAS.
- INMUNOHISTOQUÍMICAS.
- INMUNOFLUORESCENCIA.
- BIOLOGÍA MOLECULAR.
- MICROSCOPIA ELECTRÓNICA.

# Secuenciación

---



Microarray



Microarray



Chromatogram

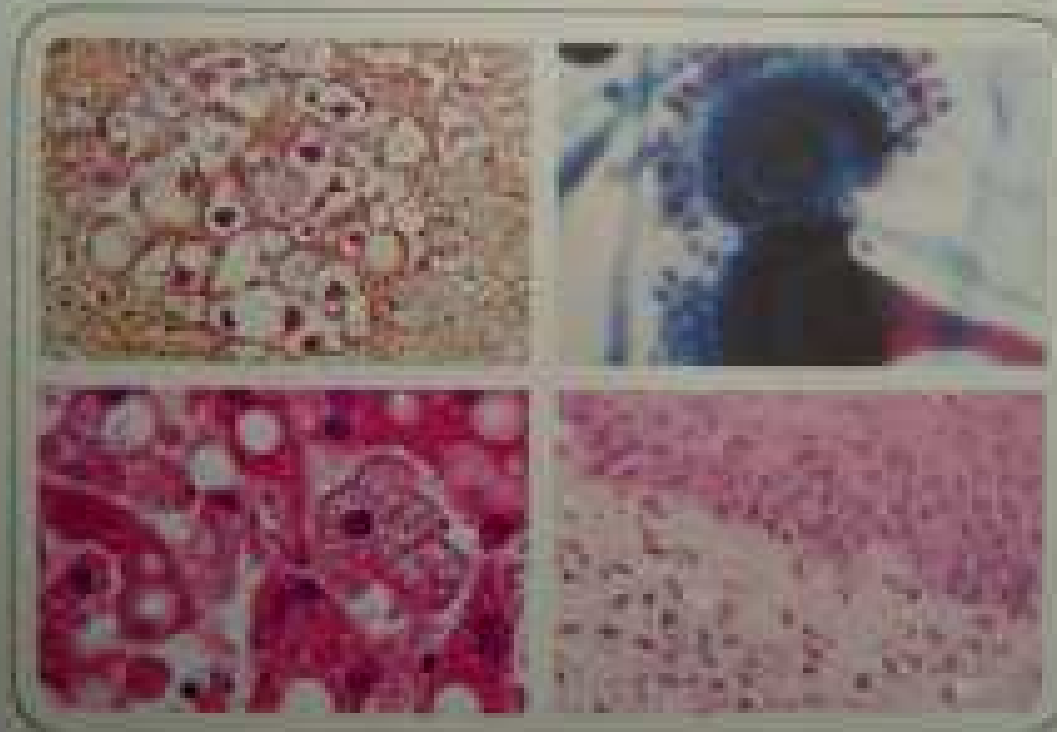


# METODOLOGÍA

- TAMAÑO.
- FORMA.
- COLOR.
- CONIDIOGÉNESIS.
- MEDICACIÓN.

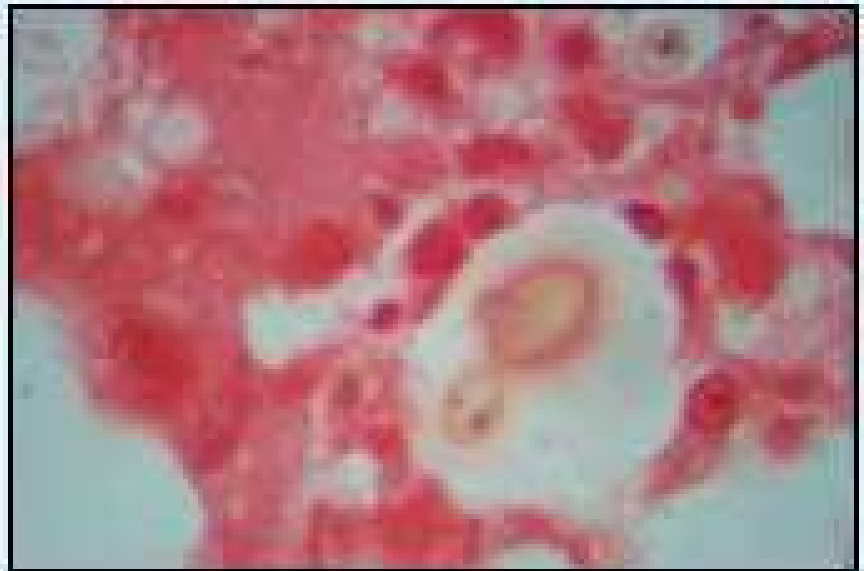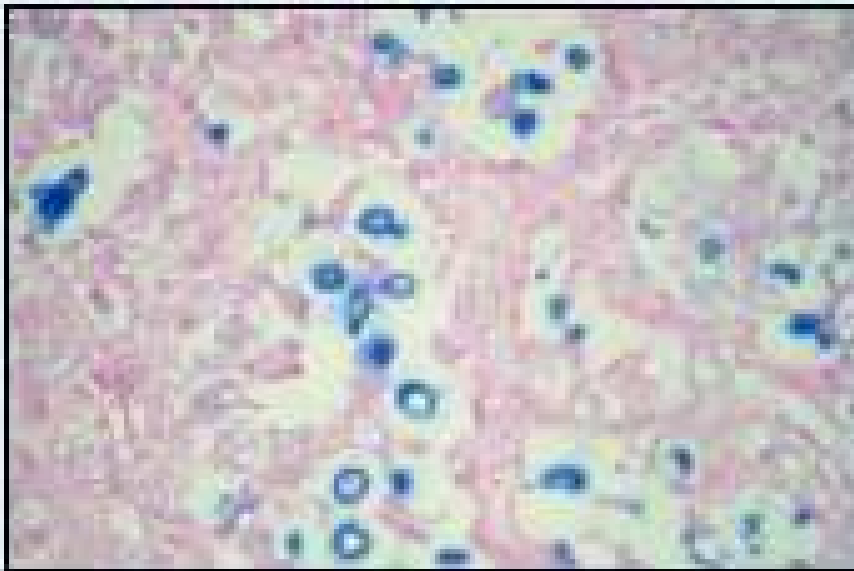
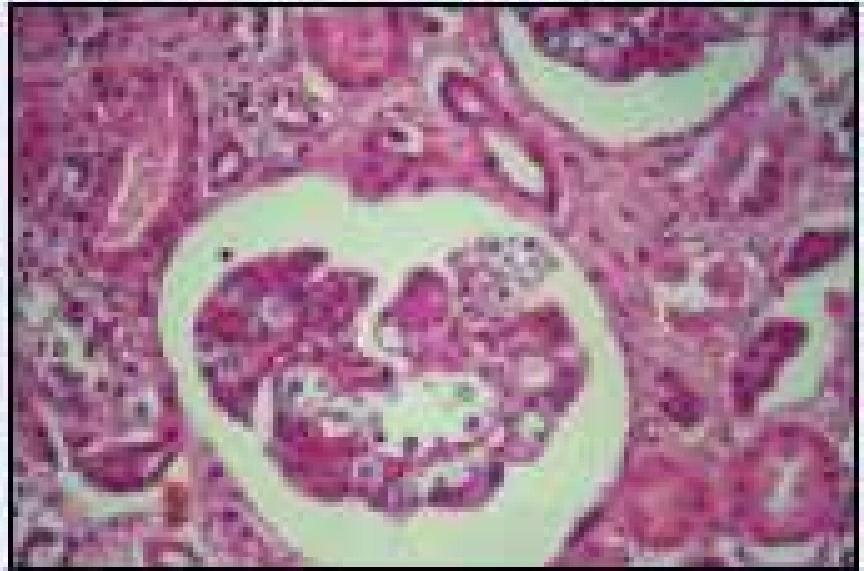
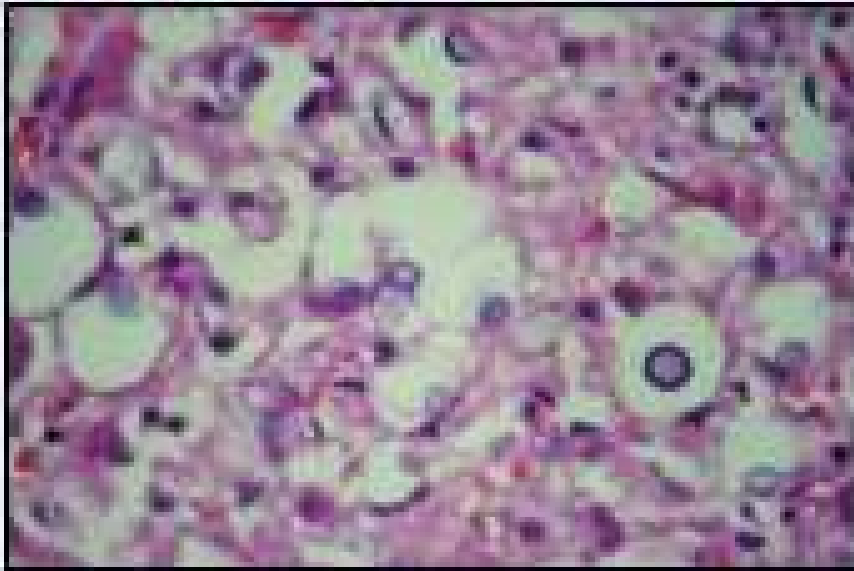
ATLAS OF  
**FUNGAL  
PATHOLOGY**

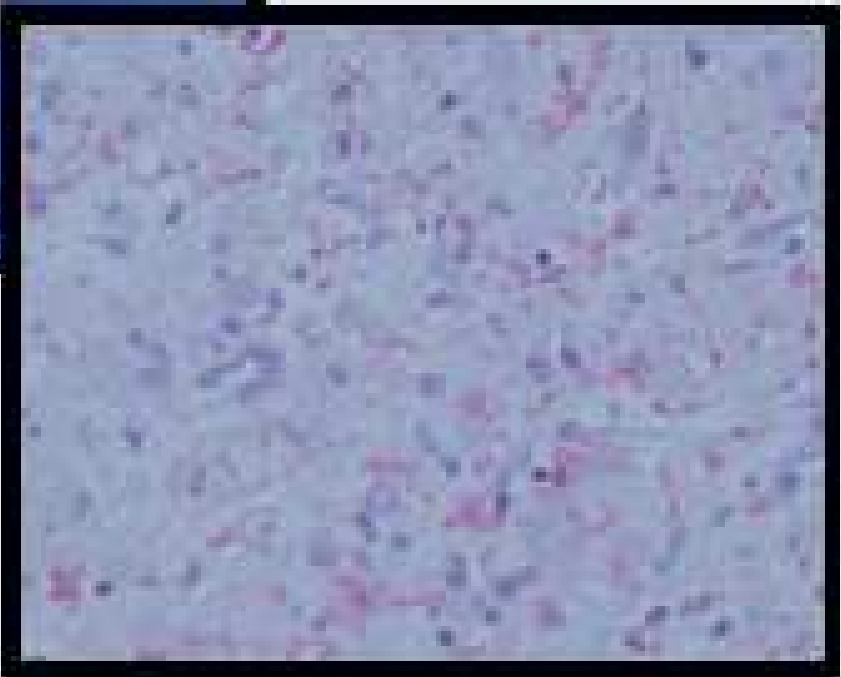
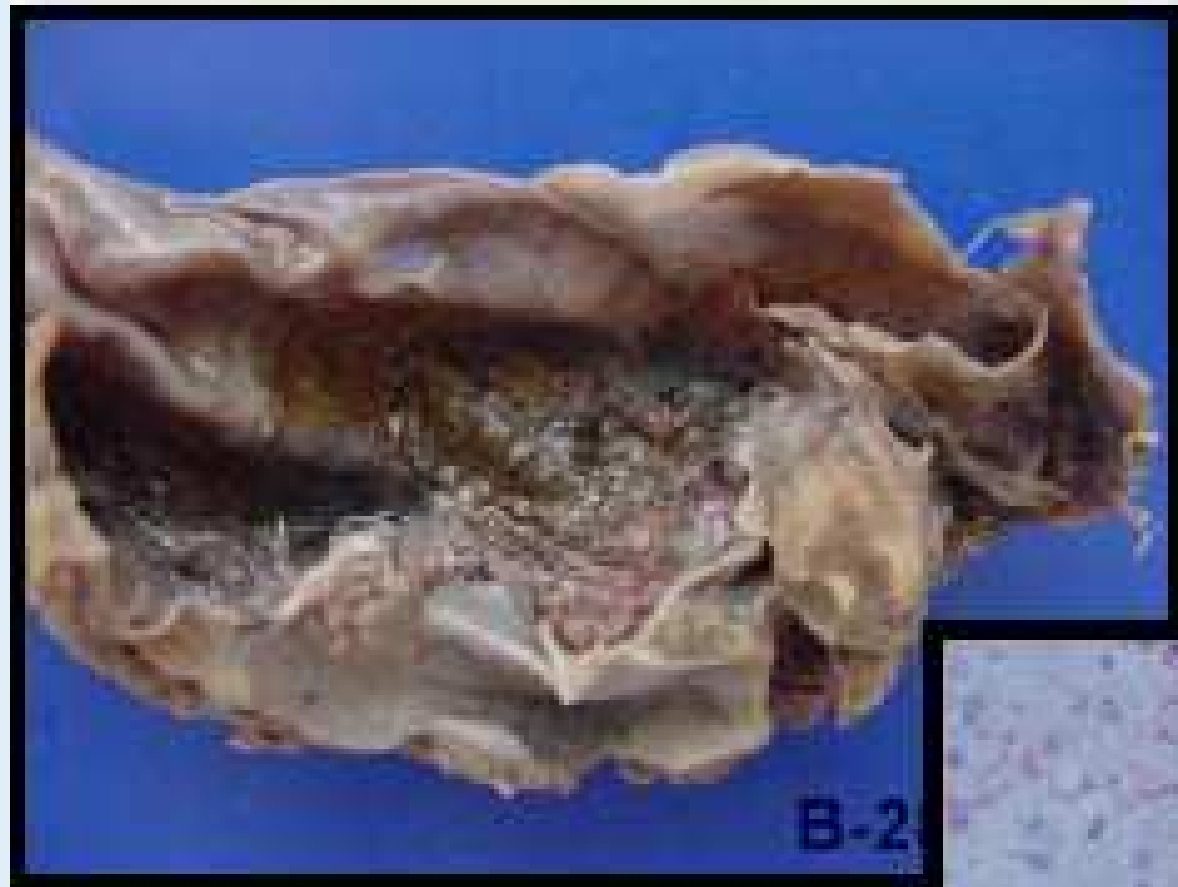
BY K. SALFELDER

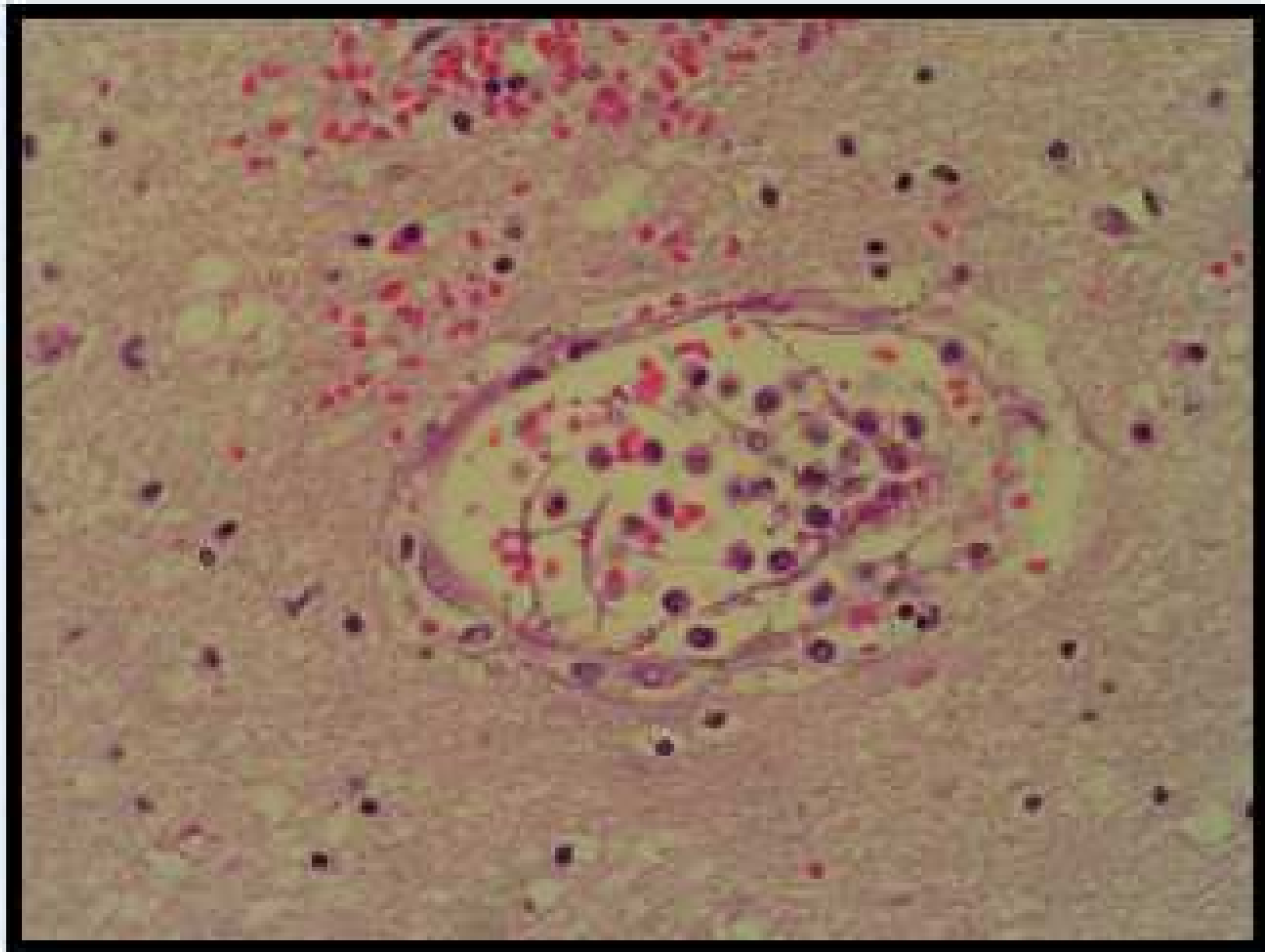


# TÉCNICAS

- **Hematoxilina-Eosina.**
- **PAS.**
- **Grocott-Gomori.**
- Gridley.
- Fontana-Masson.
- Mucicarmin.

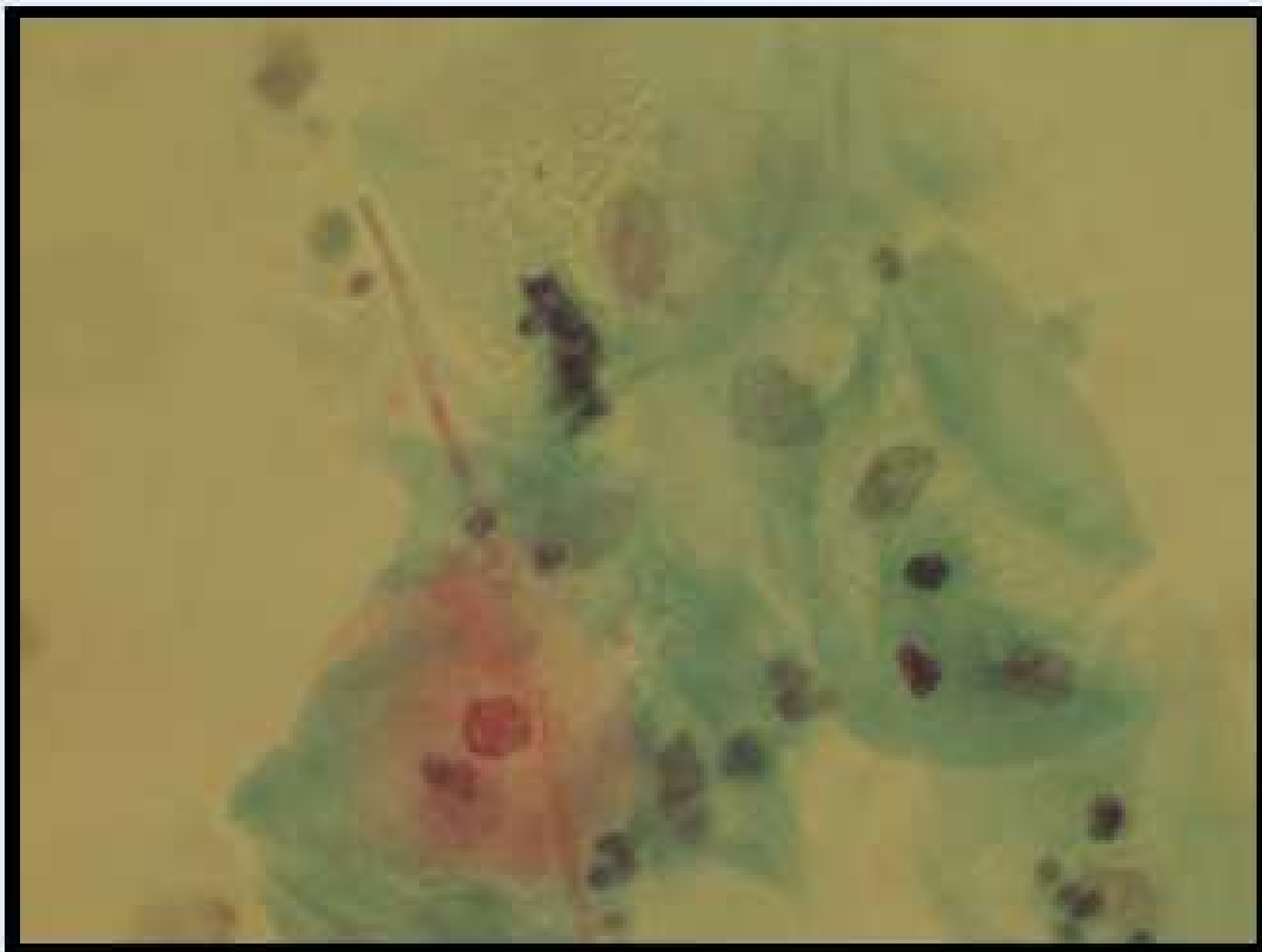


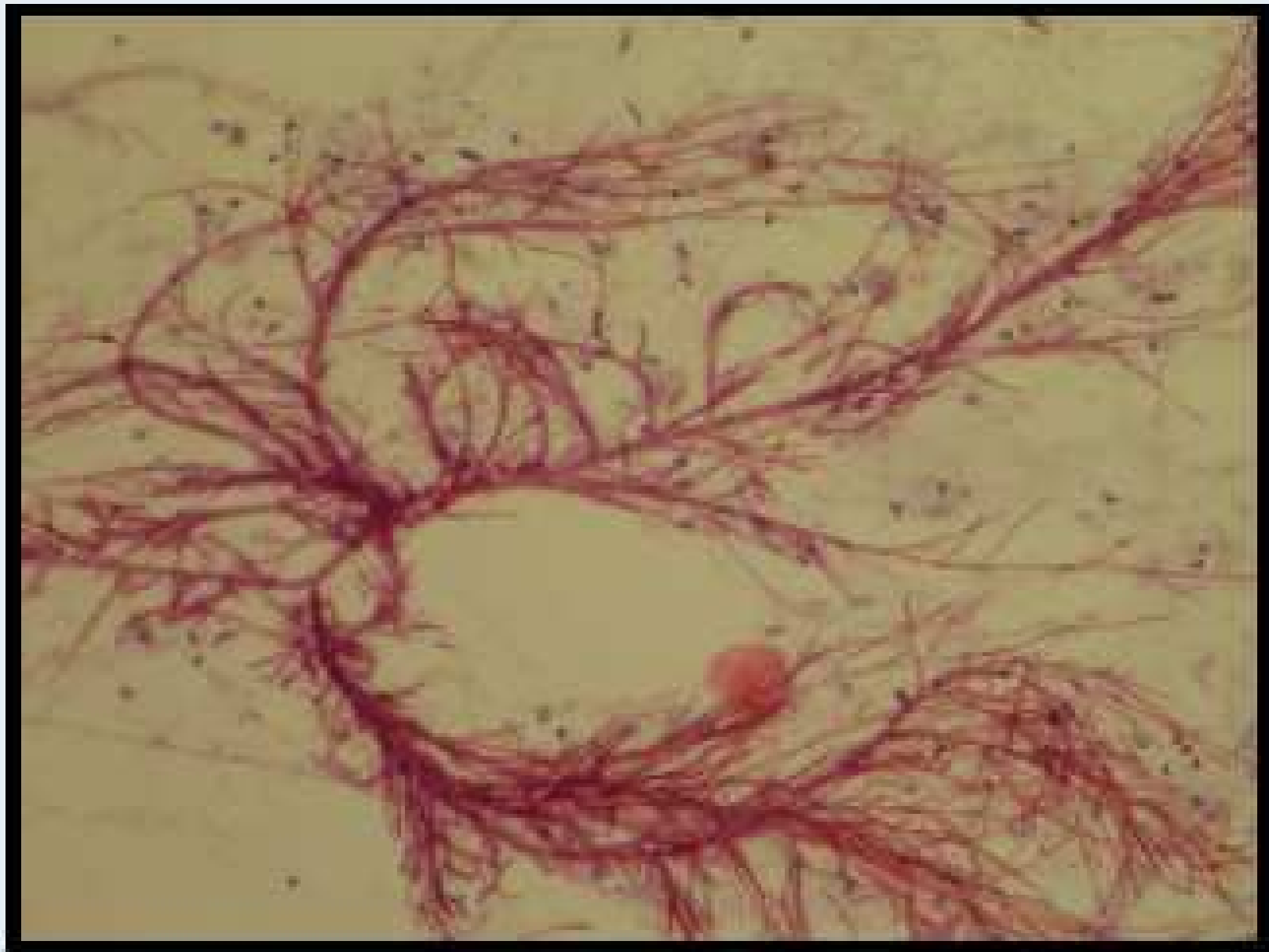


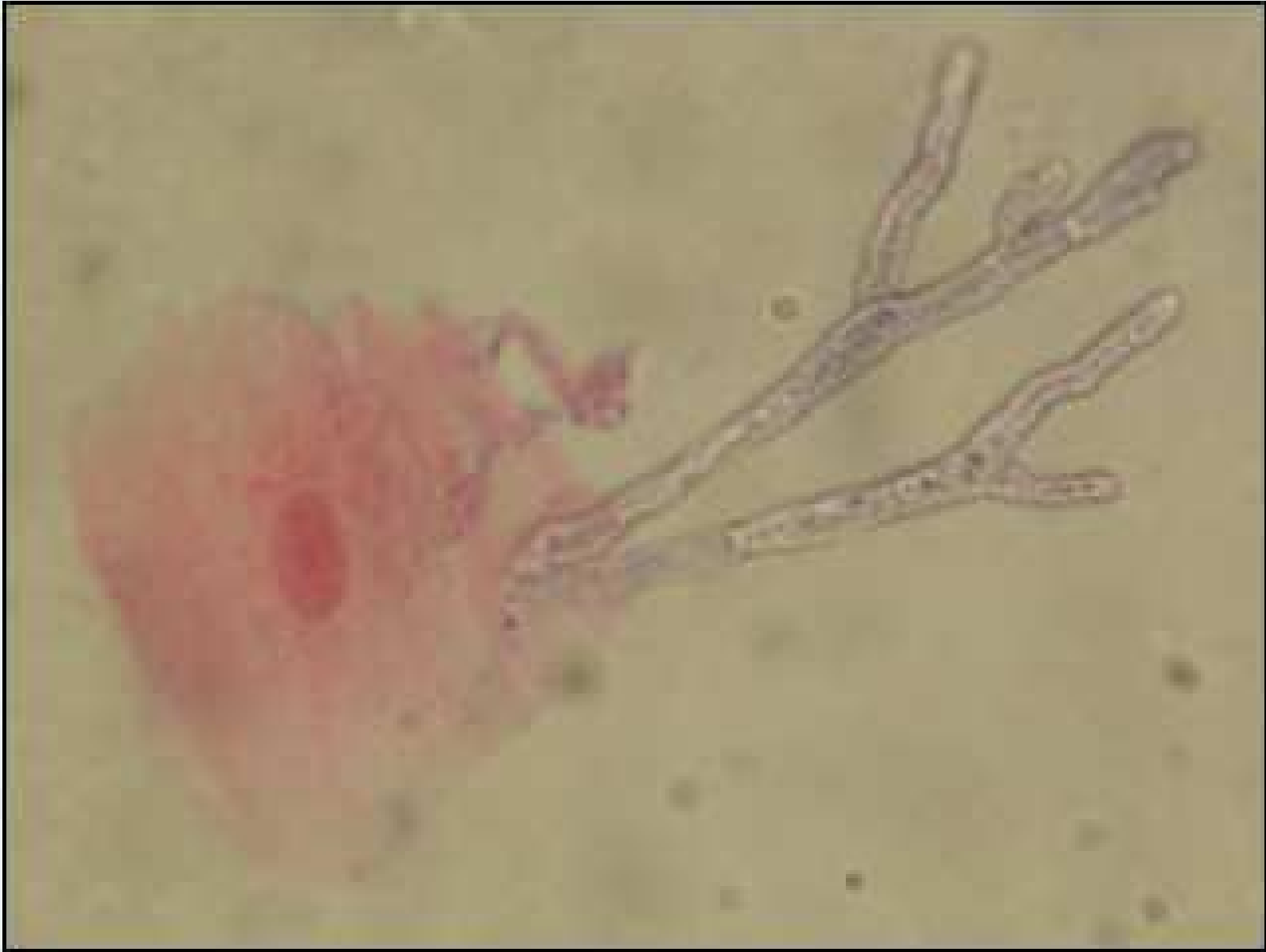

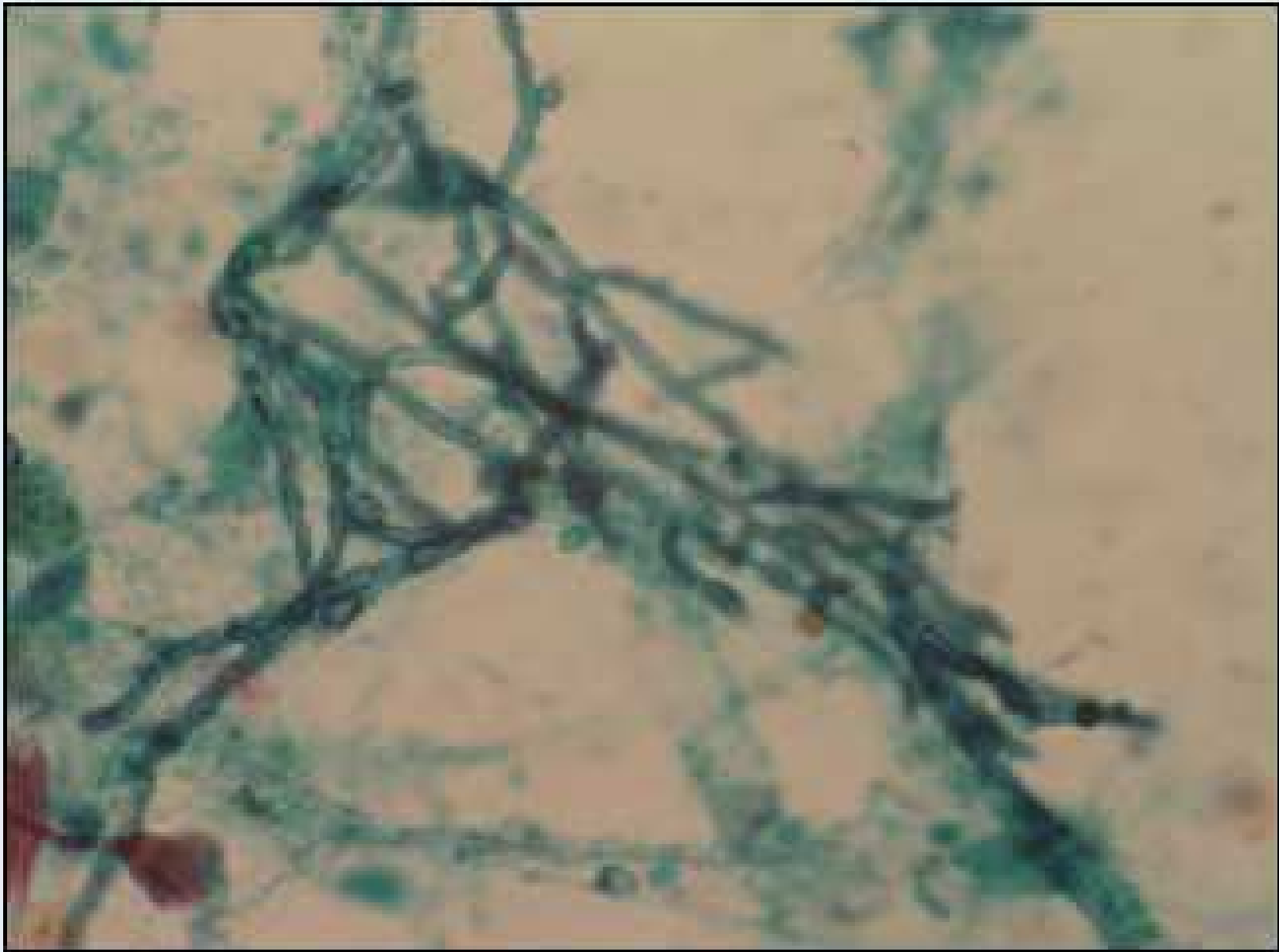
# MATERIAL A ESTUDIO

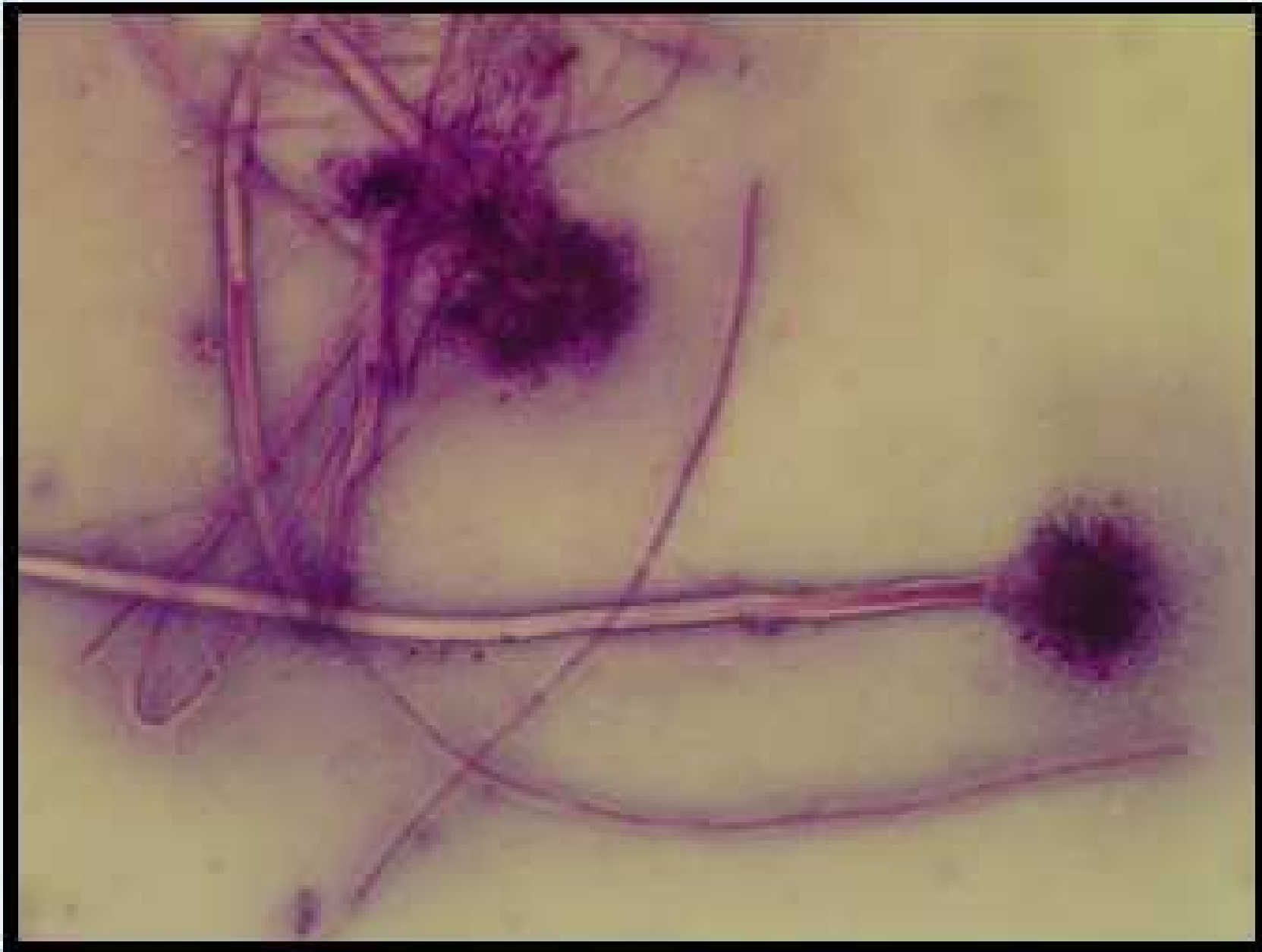- CITOLOGIA.
- PAAF (FNAC).
- BIOPSIA.
- AUTOPSIA.

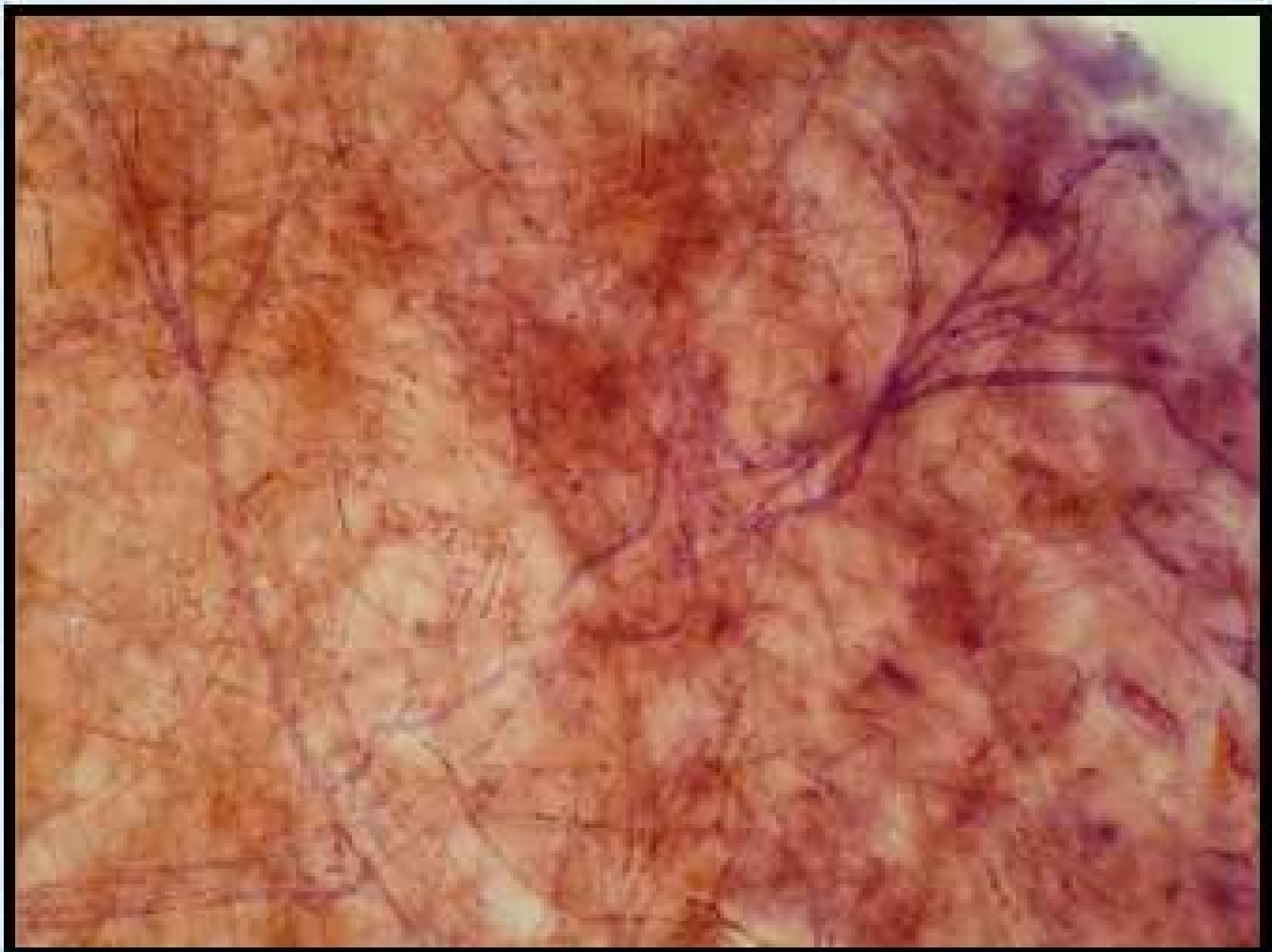


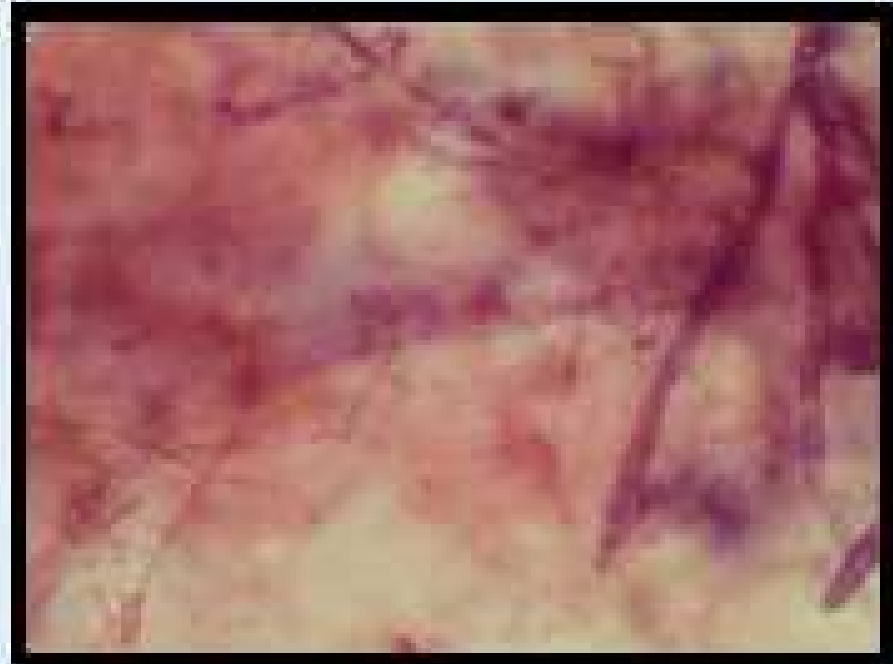
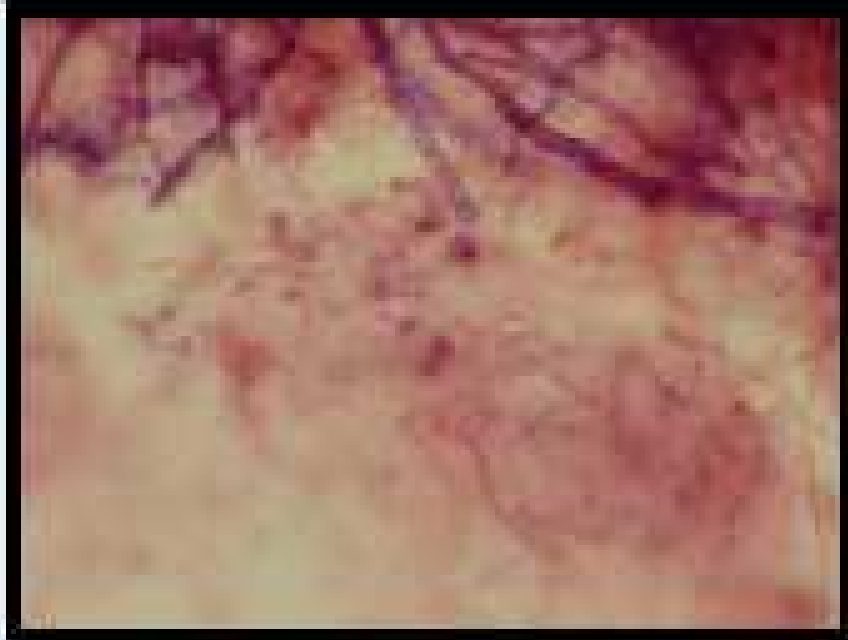
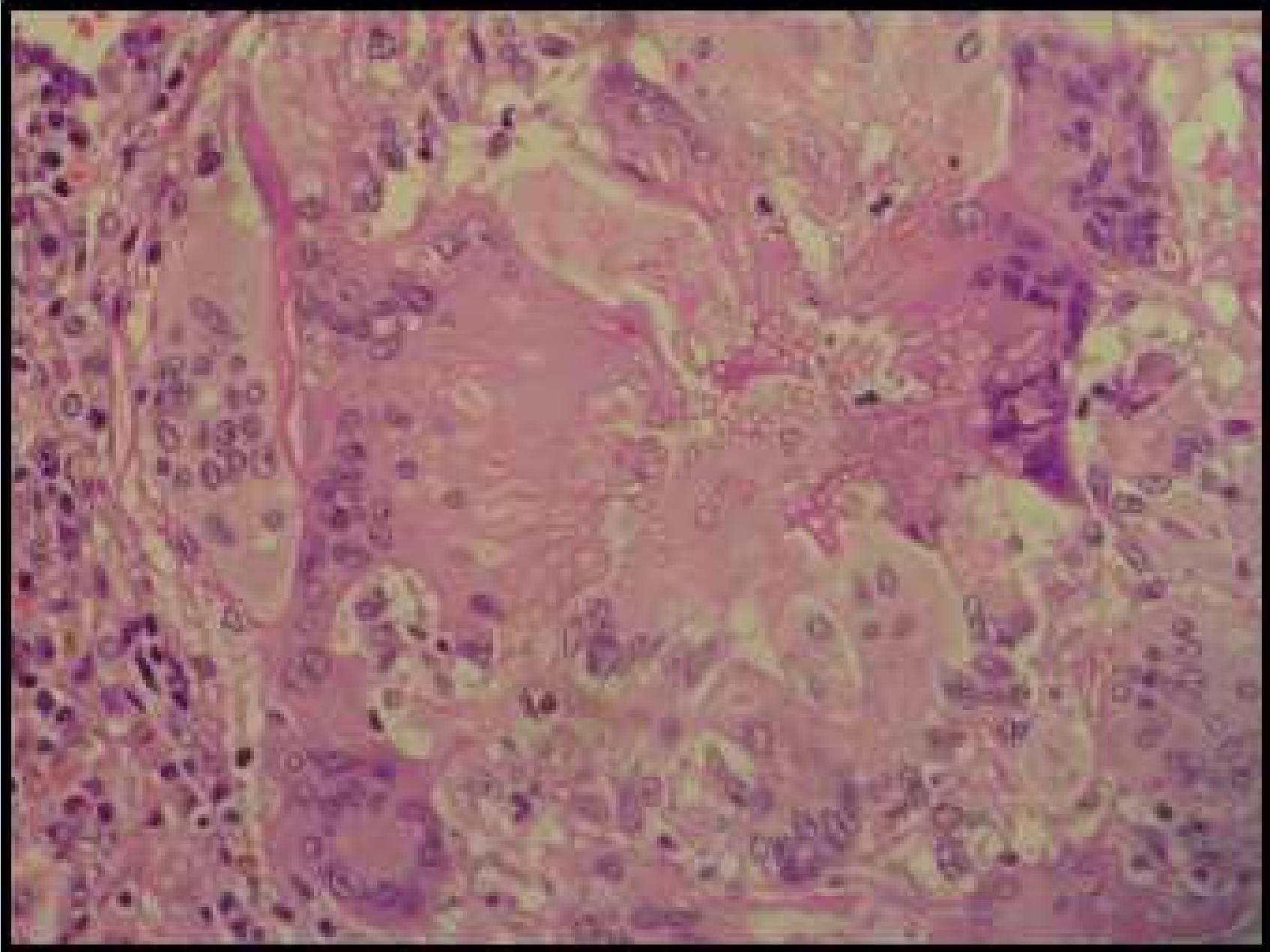


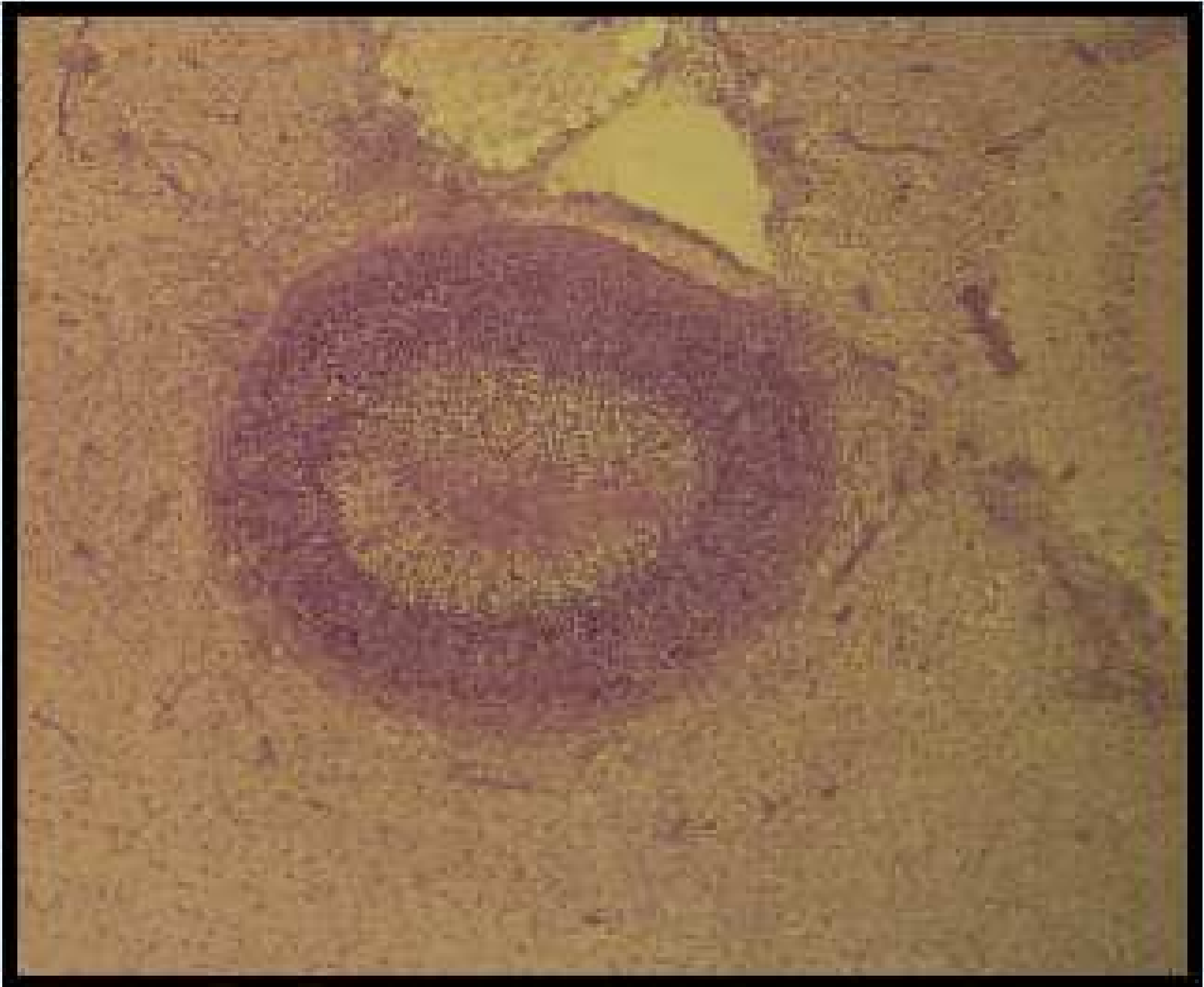


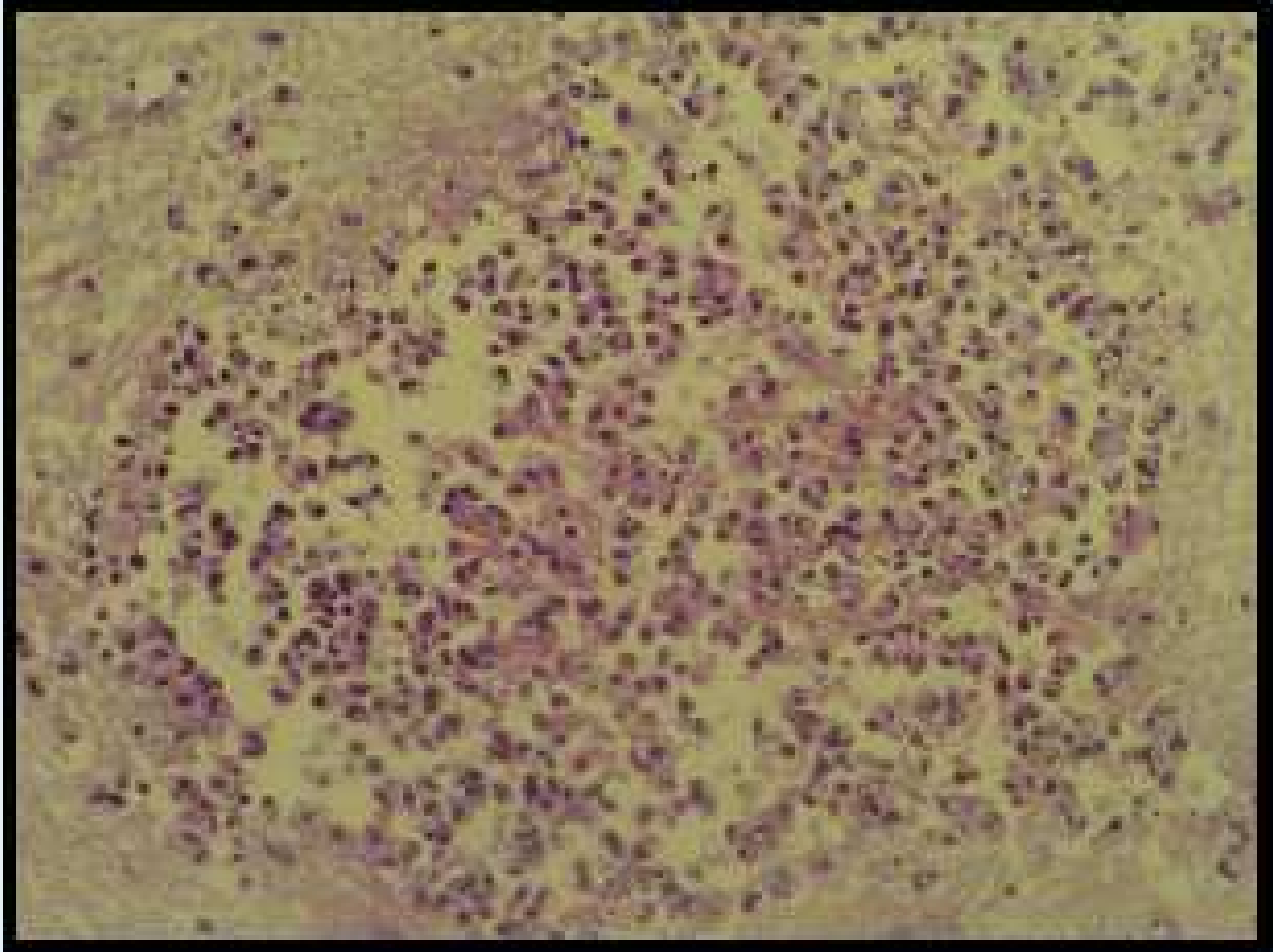


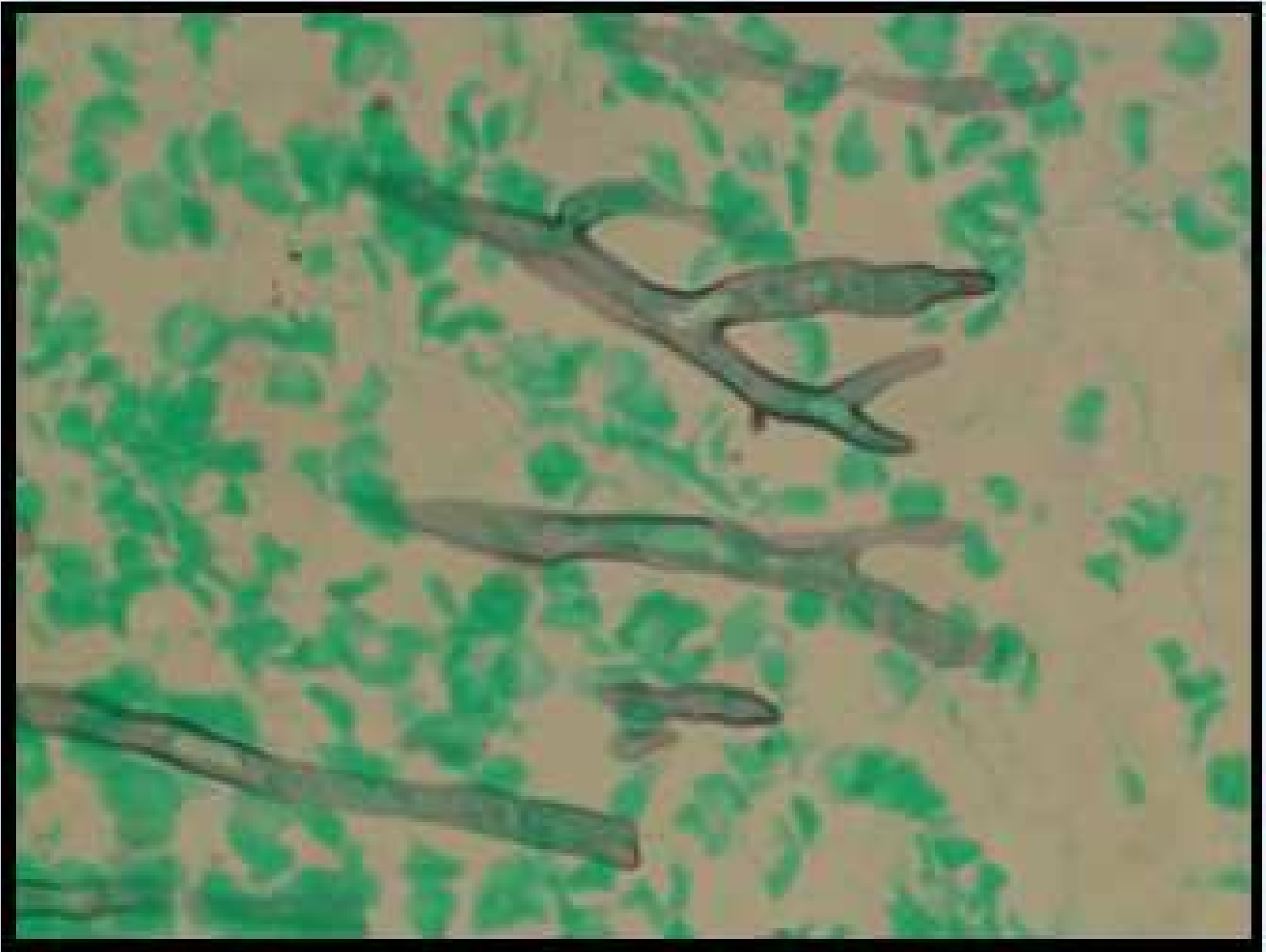












# ASPERGILLUS

- Pier A. Micheli. 1729. Nova Plant. Genera
- Rudolf Virchow 1856. Infección humanos.
- Fresenius 1856. Infección aves.
- F.Deve 1938. Aspergiloma (fungus ball).
- Hinson 1952. Reacciones alérgicas.
- Rankin 1953. Aspergilosis invas inmuno.

# ASPERGILLUS

- INFECCIÓN NOSOCOMIAL.
- PACIENTES HEMATOLÓGICOS.
- INMUNOCOMPROMETIDOS.
- PACIENTES DE UCI.
- EPOC.
- FIBROSIS QUÍSTICA
- CÁNCER DE PULMÓN.
- TUBERCULOSIS ANTIGUA.

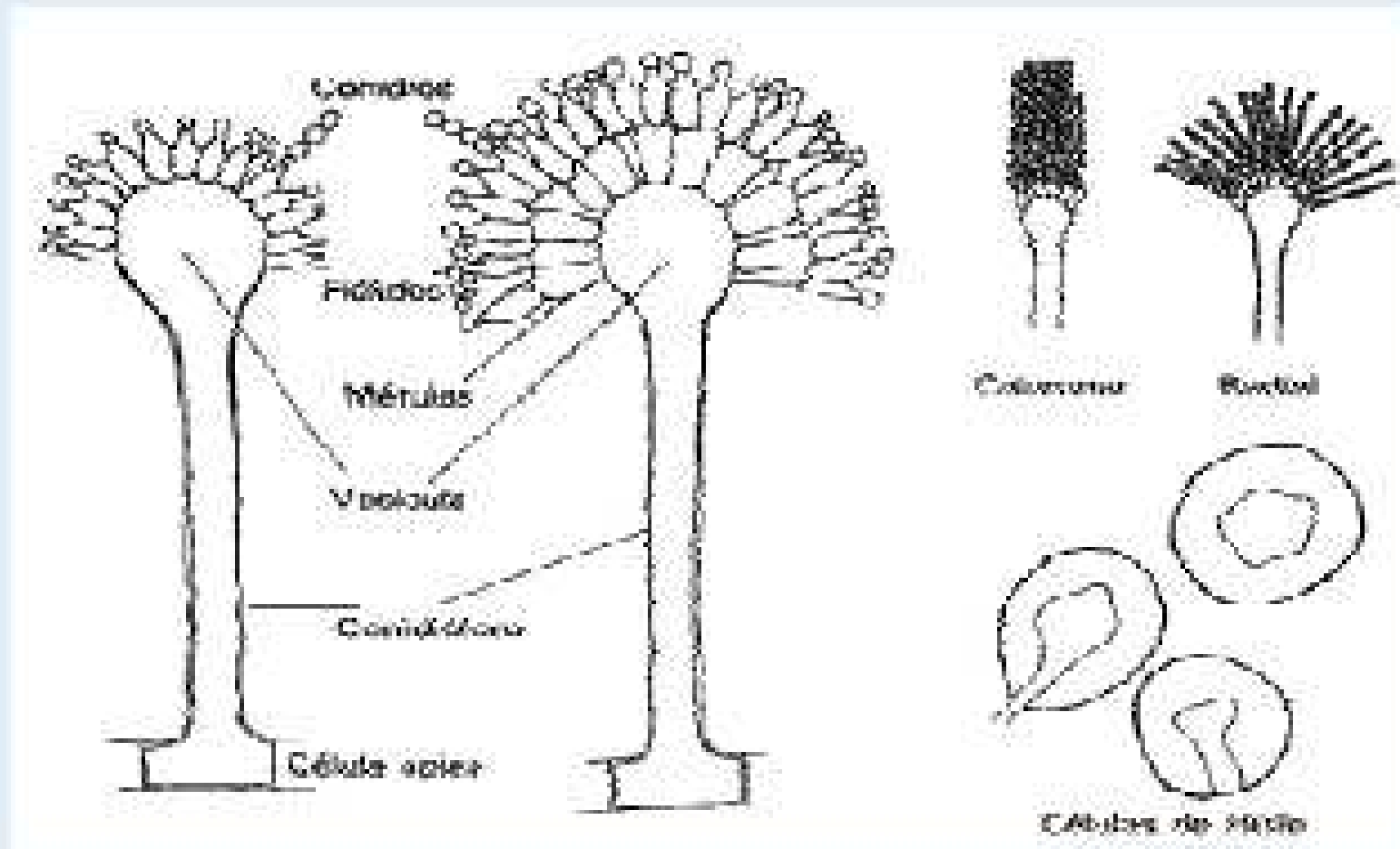
# ASPERGILLUS

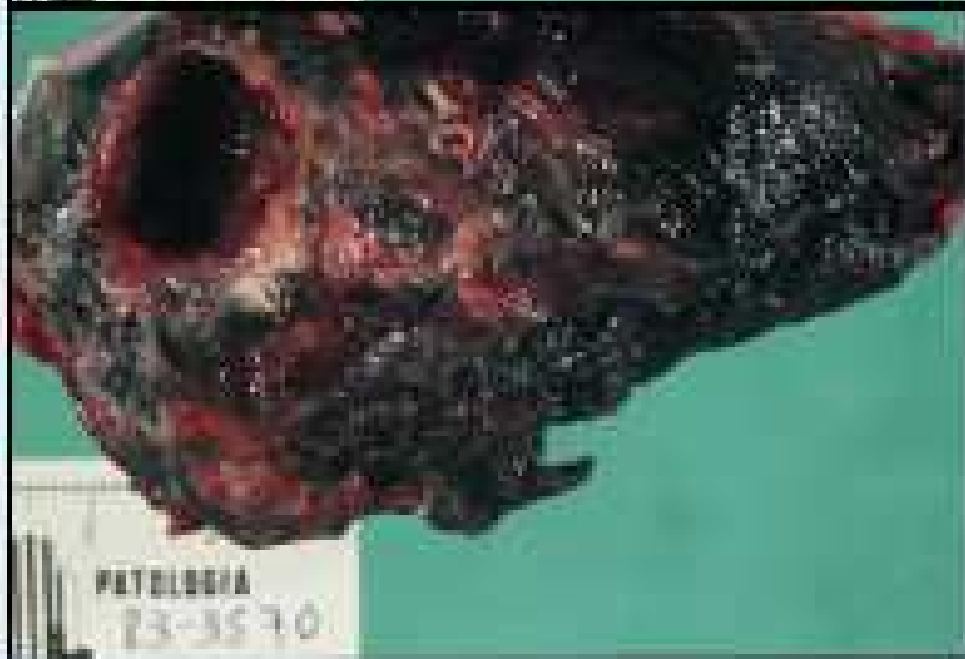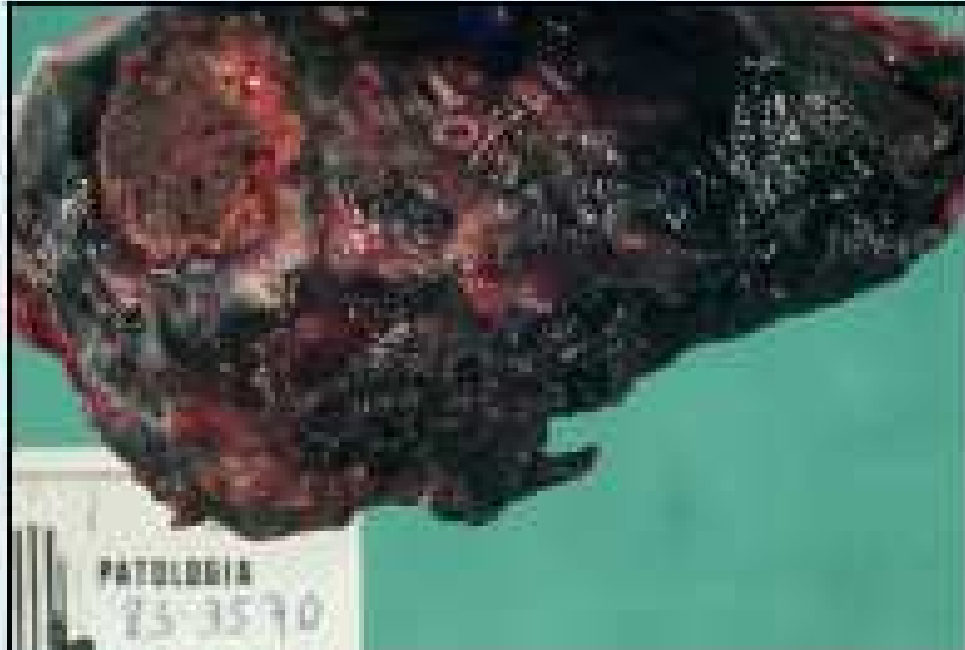- FORMA ALÉRGICA.
- FORMA SAPRÓFITA.
- FORMA INVASORA.
- A. CRÓNICA NECROTIZANTE.

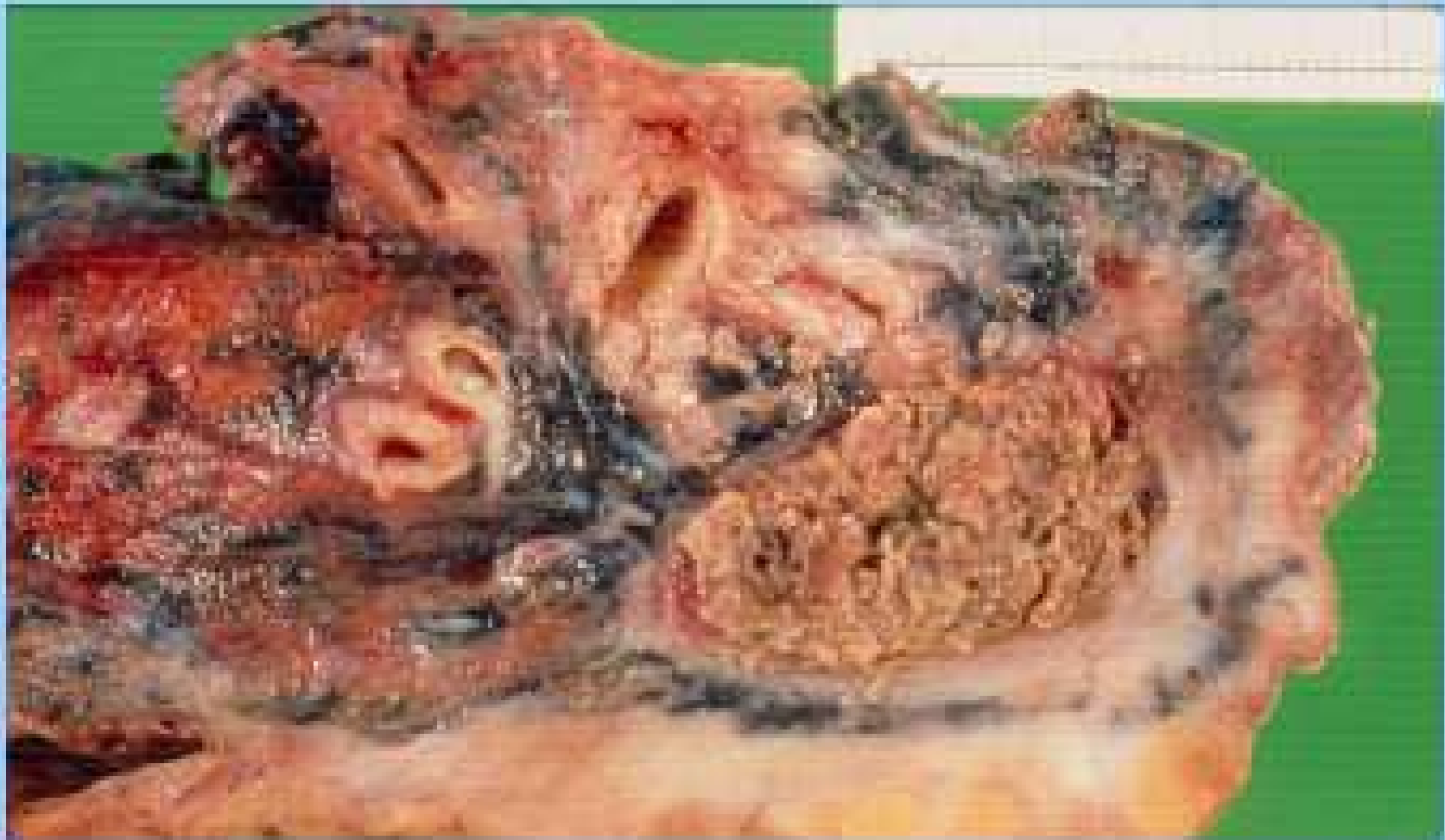# ASPERGILLUS

- + 200 ESPECIES RECONOCIDAS:
  - \* *A. fumigatus*
  - \* *A. niger*
  - \* *A. flavus*
  - *A. ustus*
  - *A. terreus*
  - *A. nidulans*
  - *A. candidus*

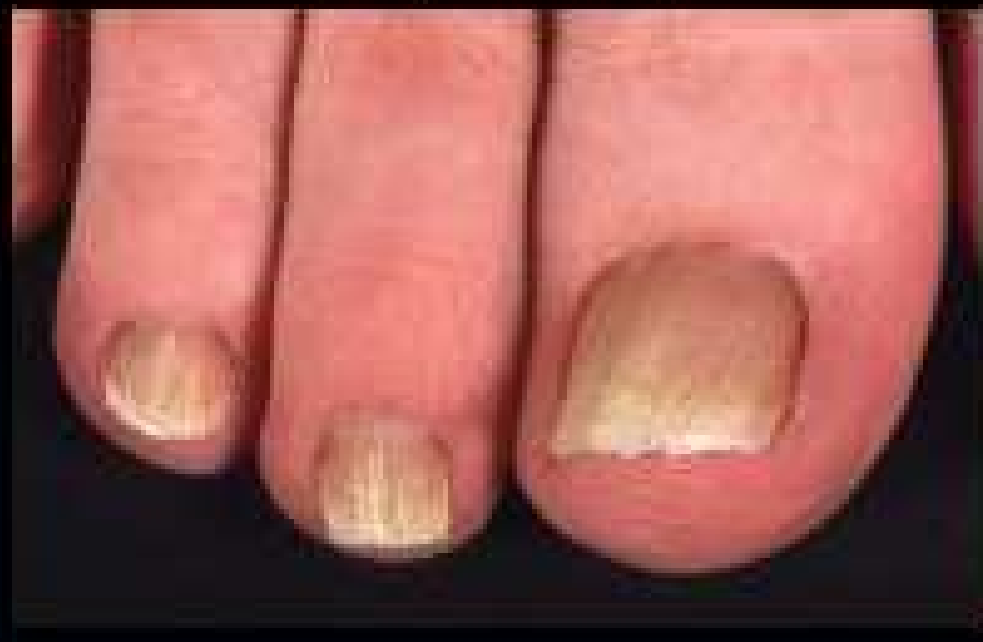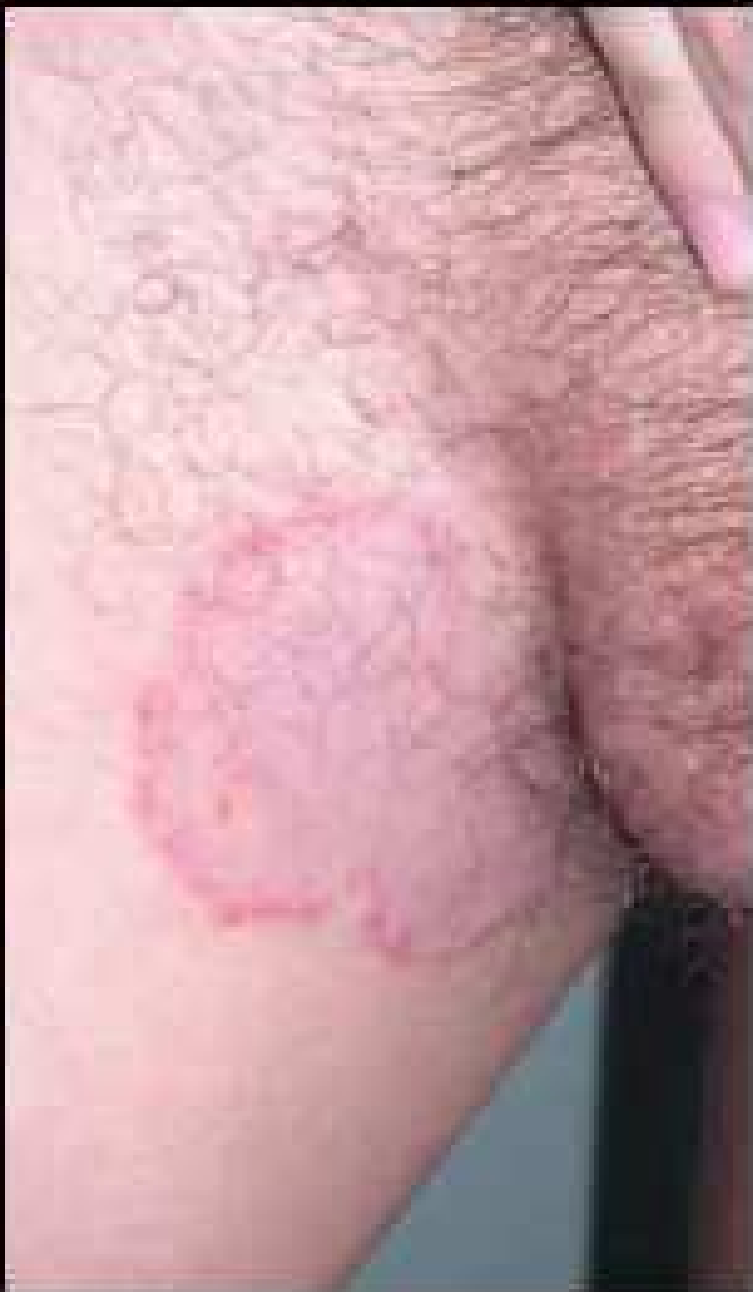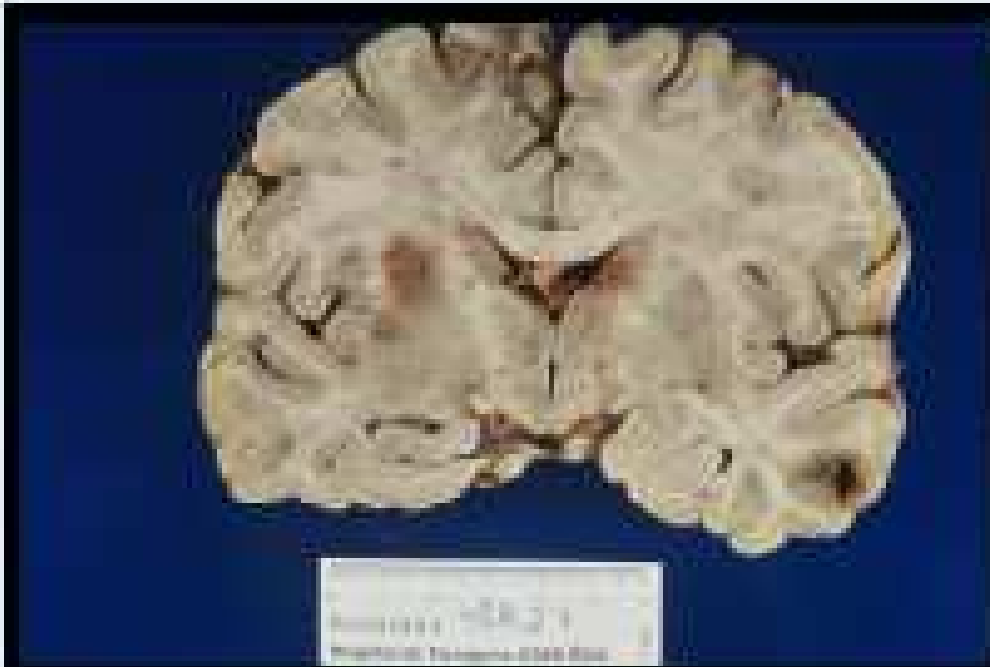
# ASPERGILLUS

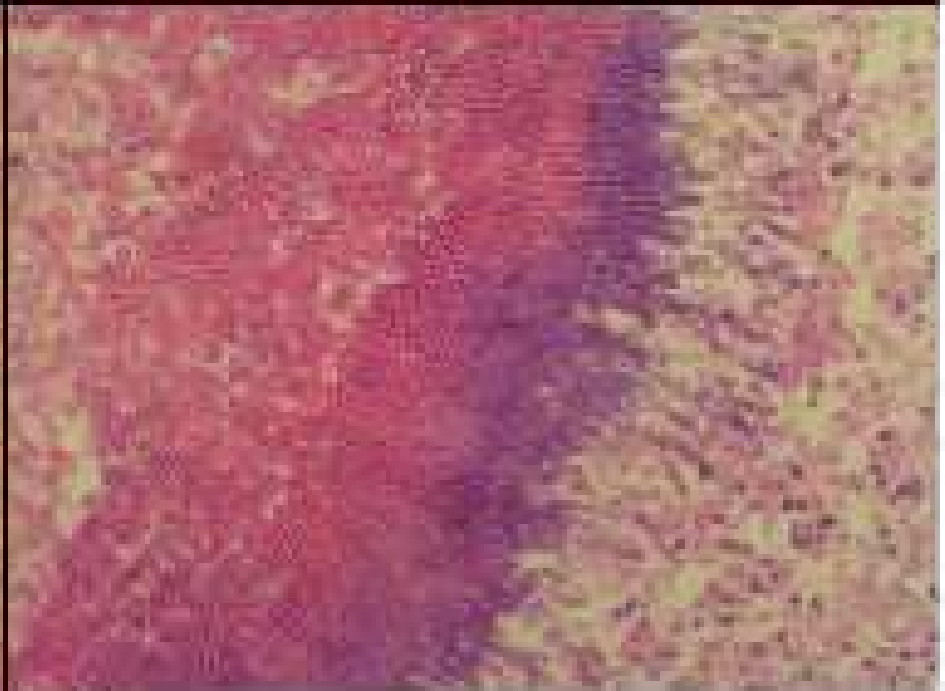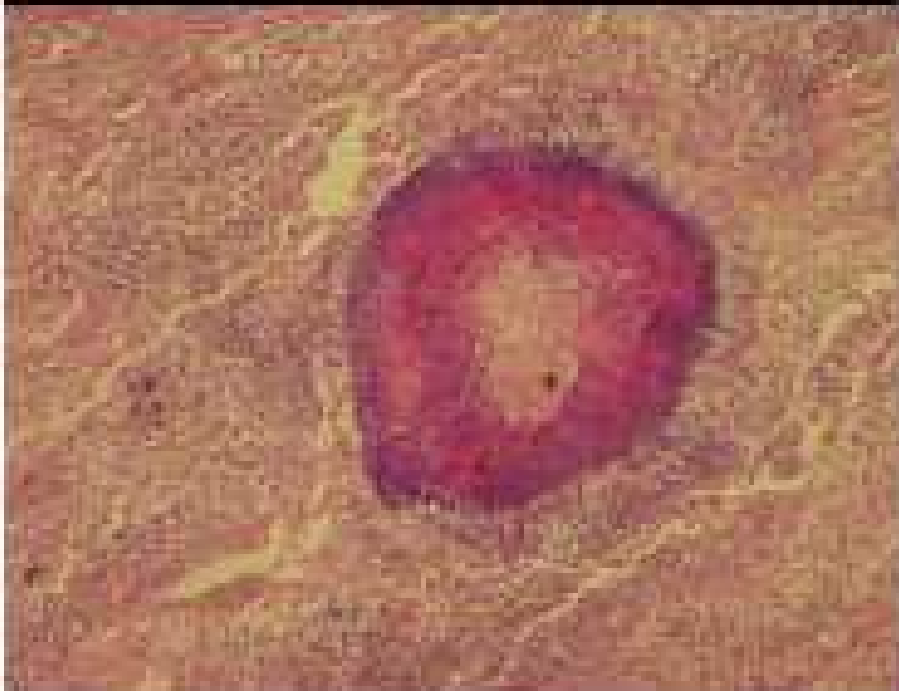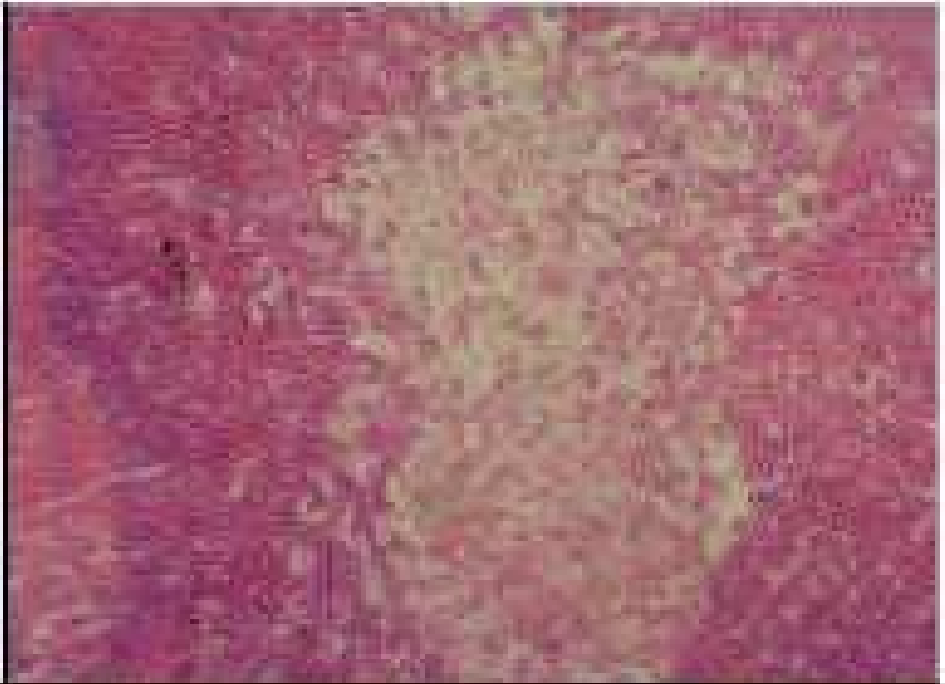


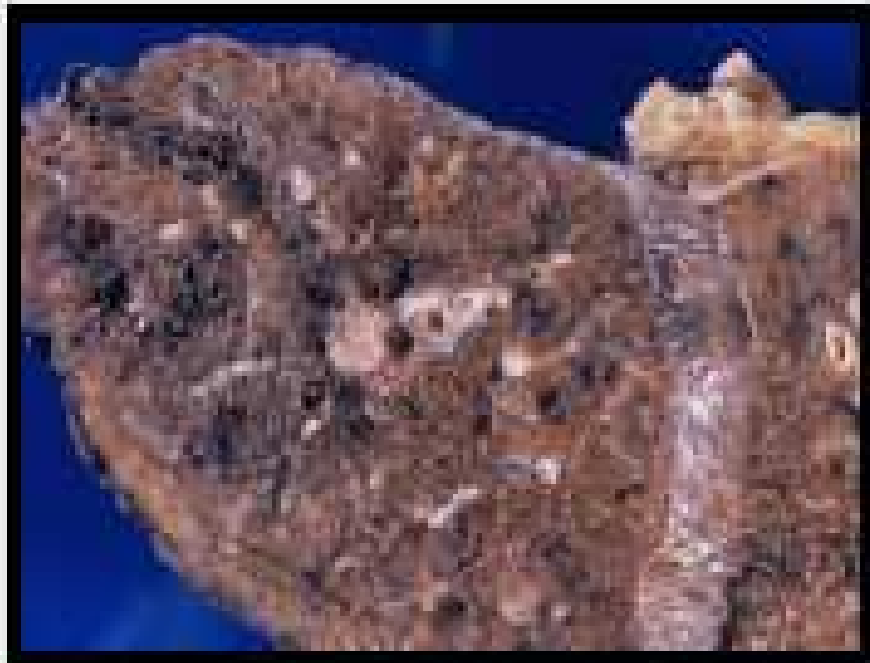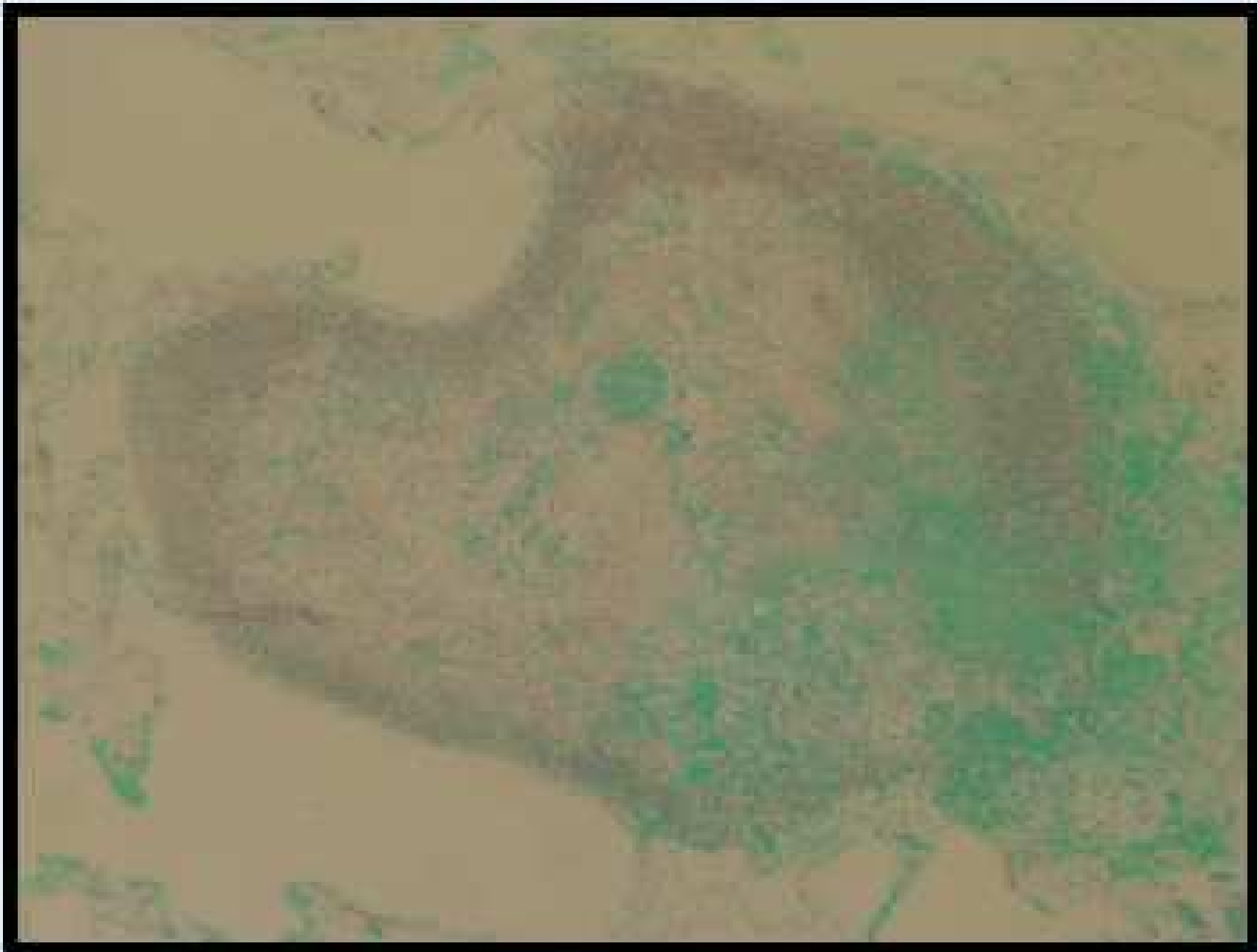


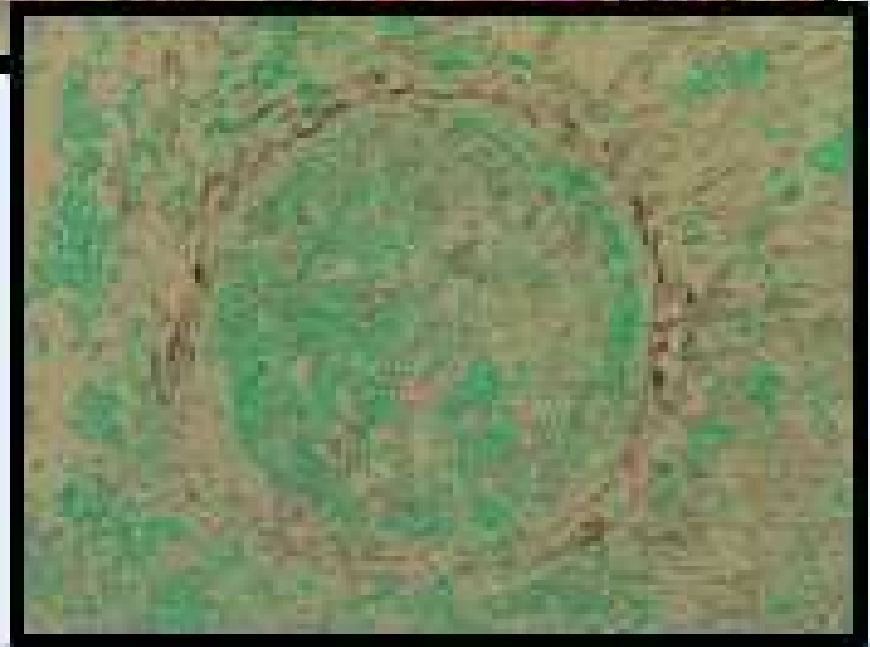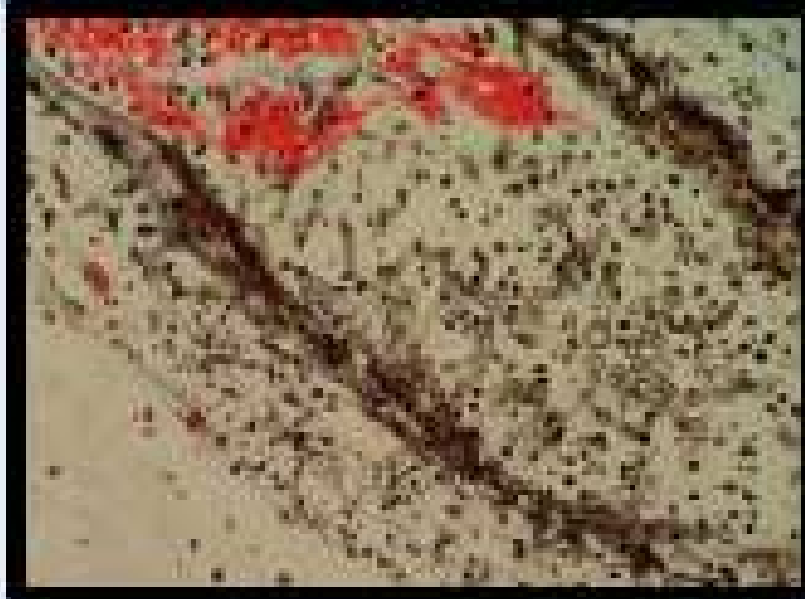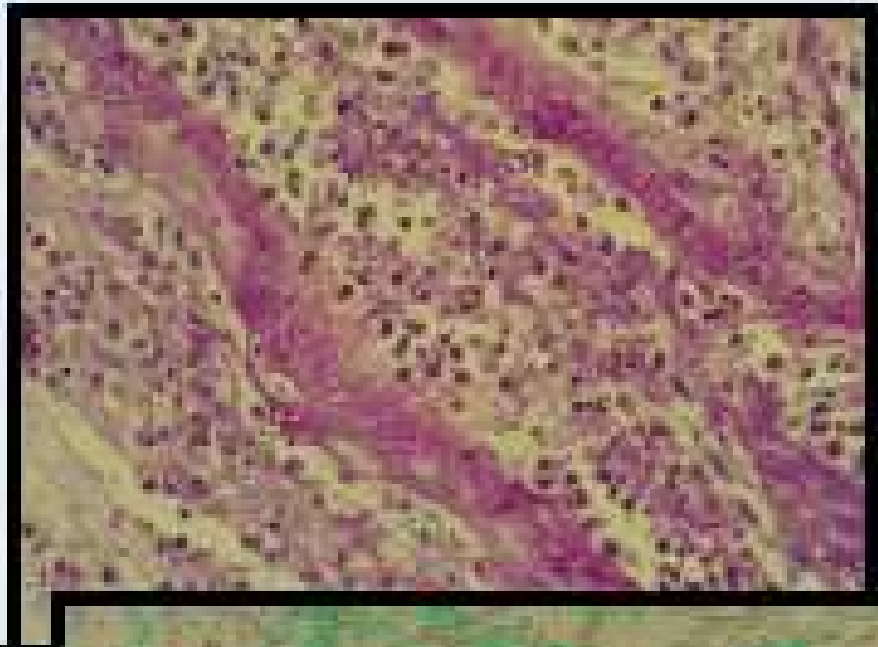


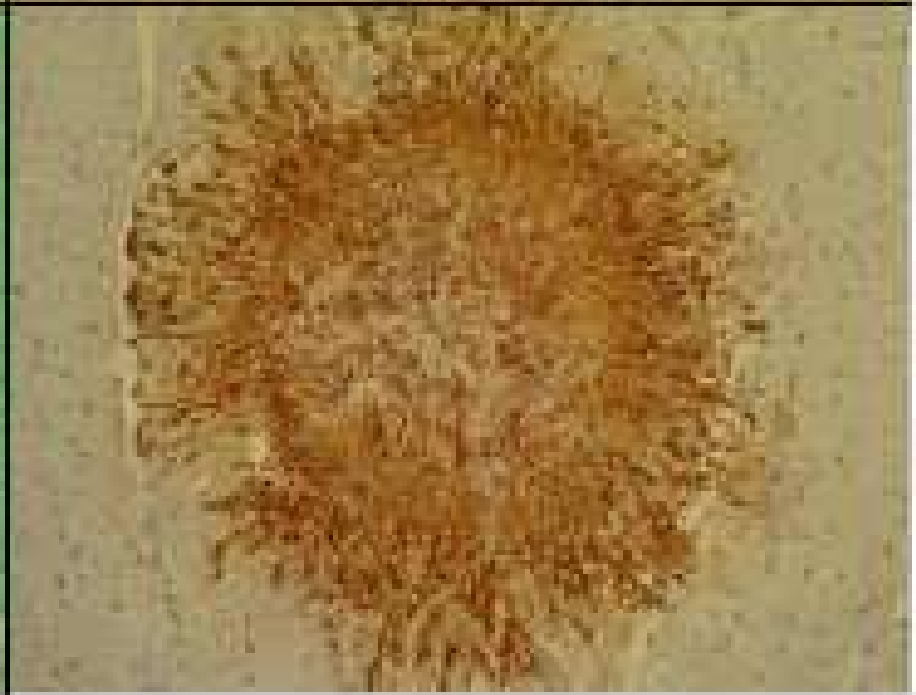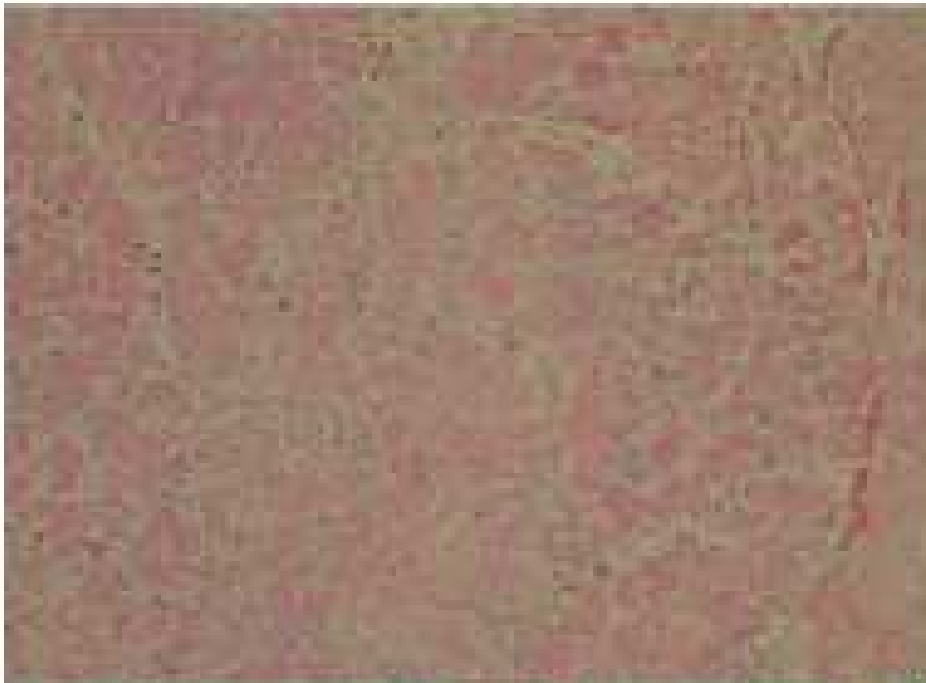Pieza de pulmón en autopsia. En su centro hay gran cavidad totalmente ocupada por masa fúngica o aspergiloma. Fibrosis a su alrededor.

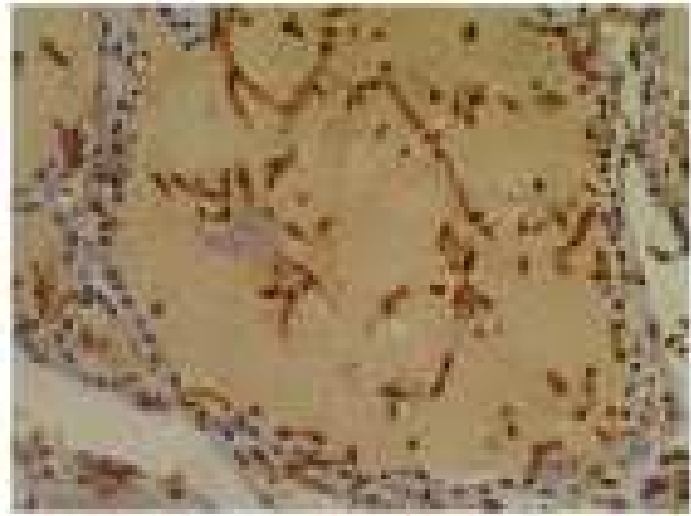
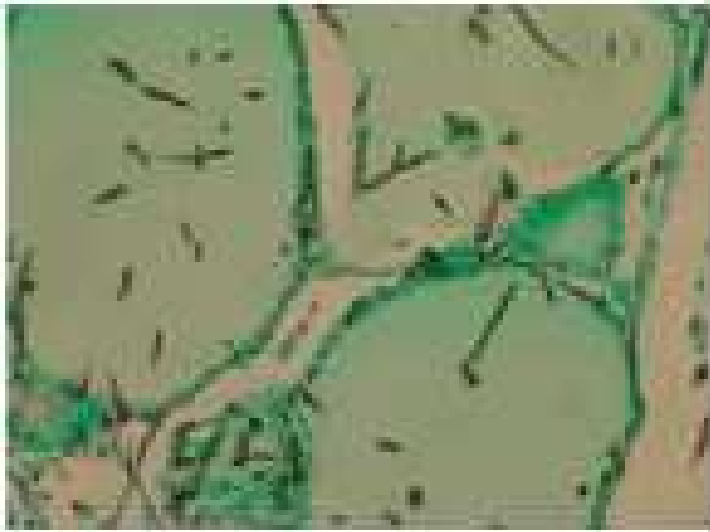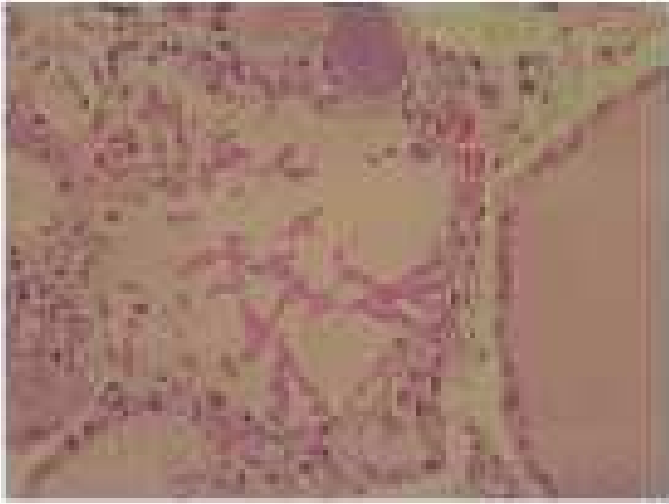


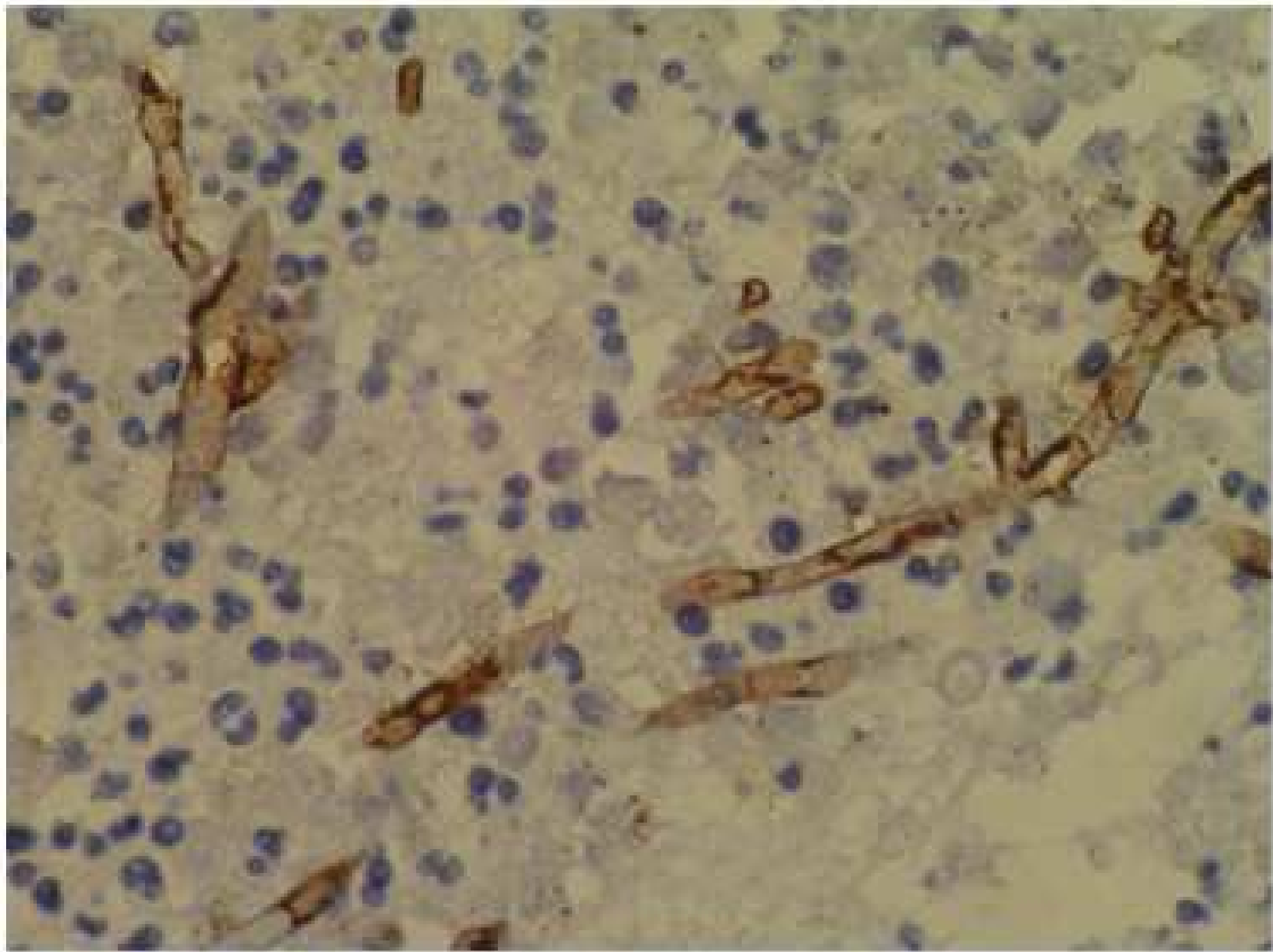


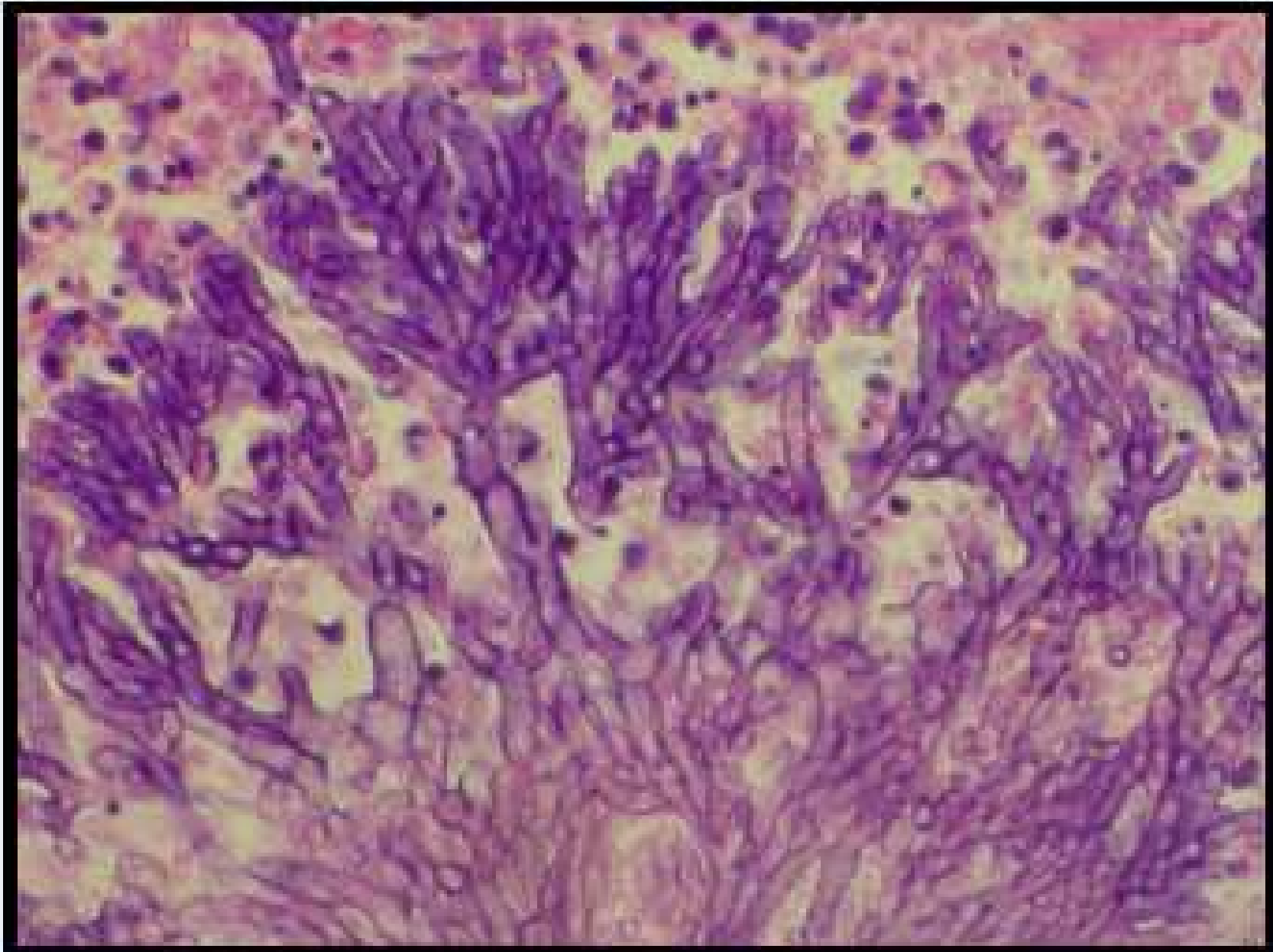


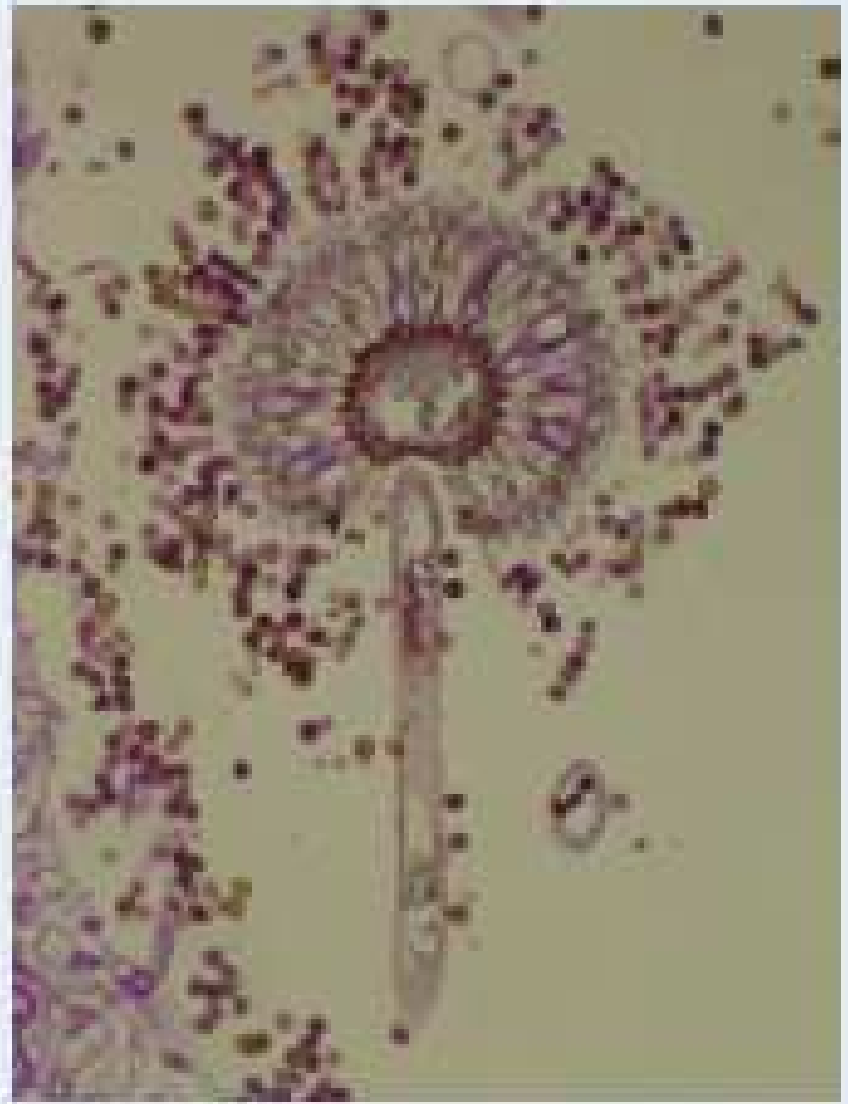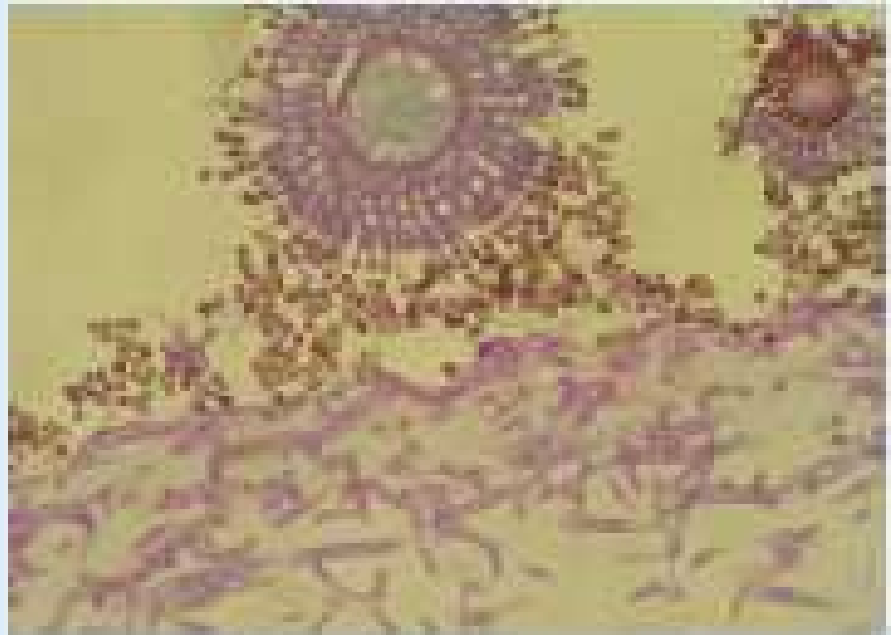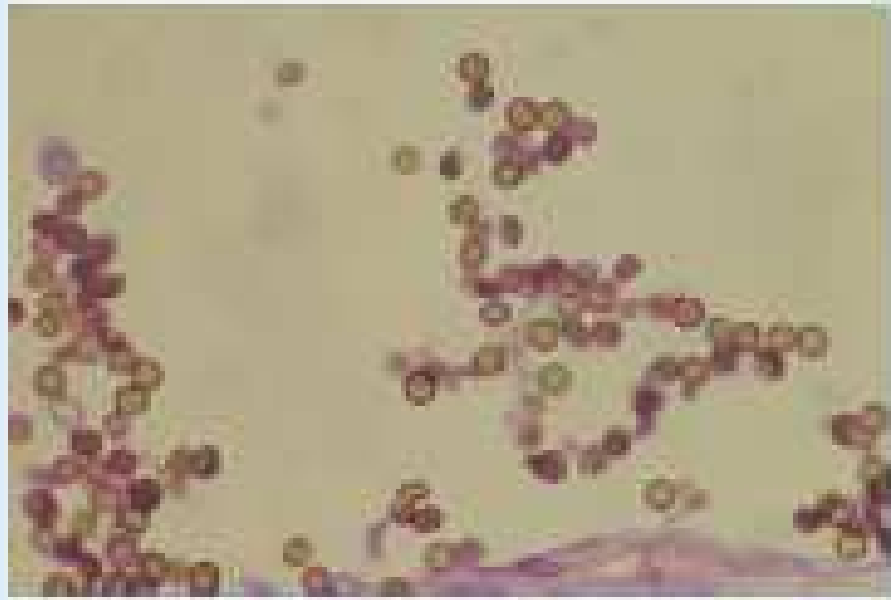


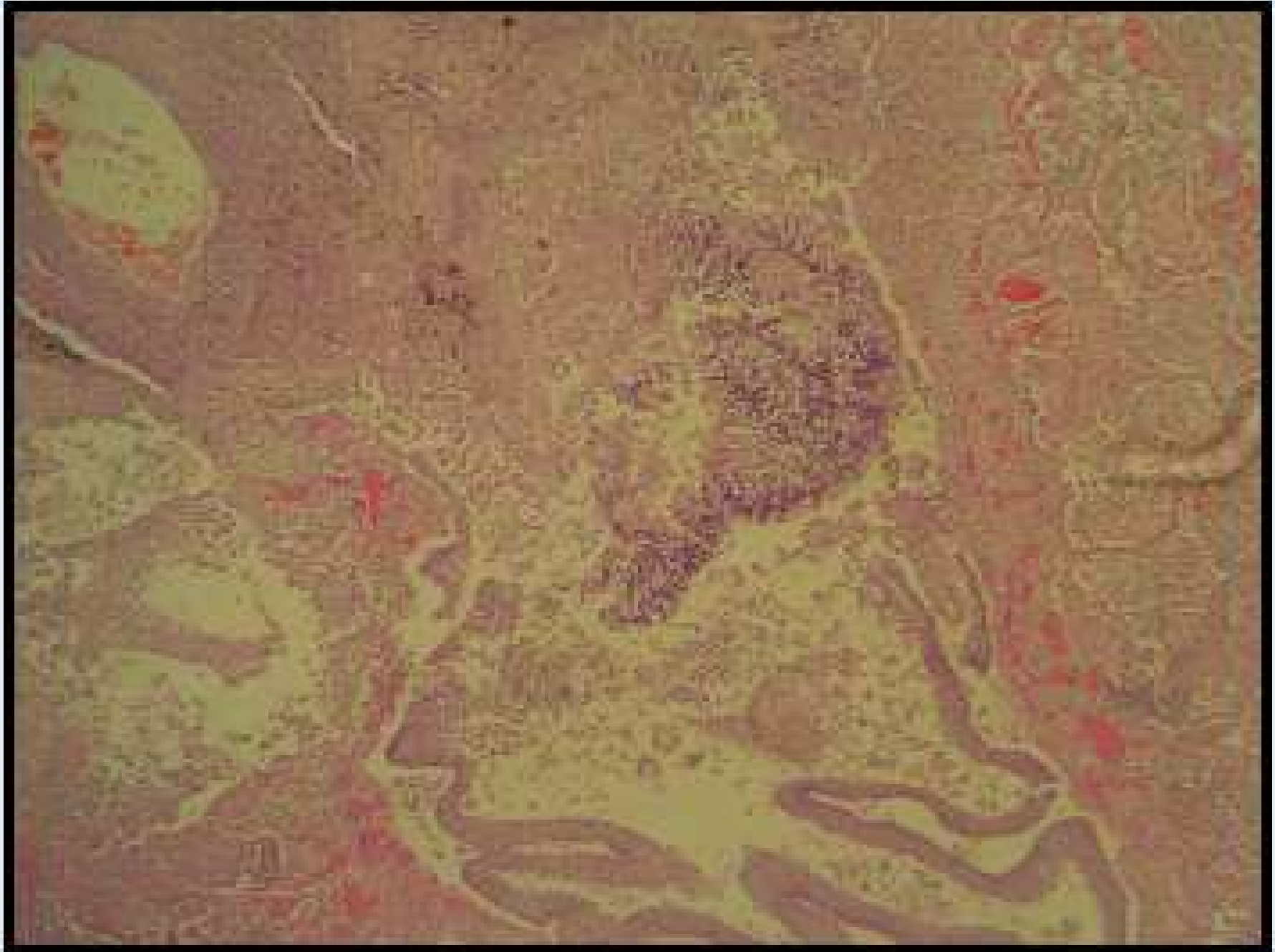


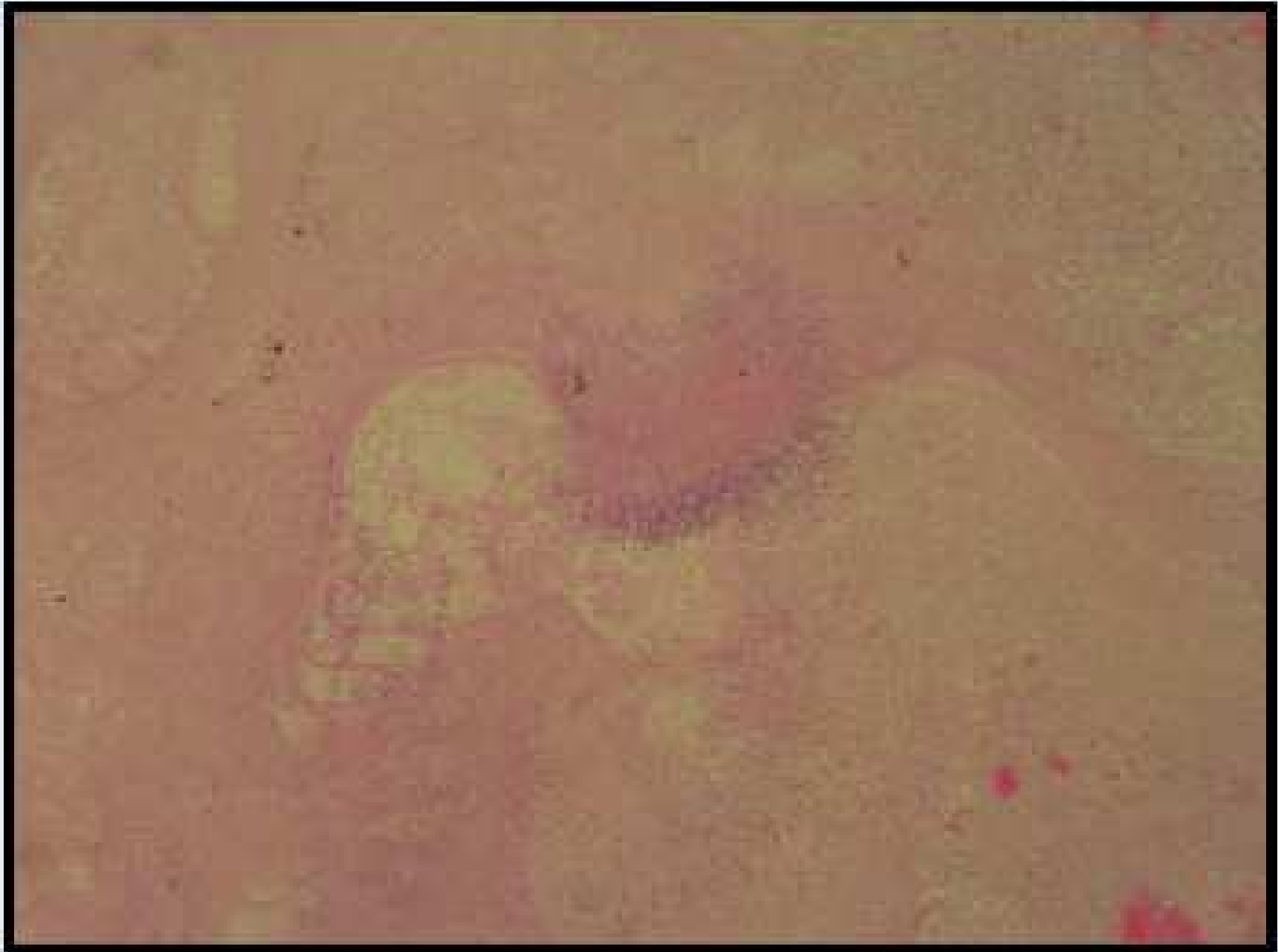


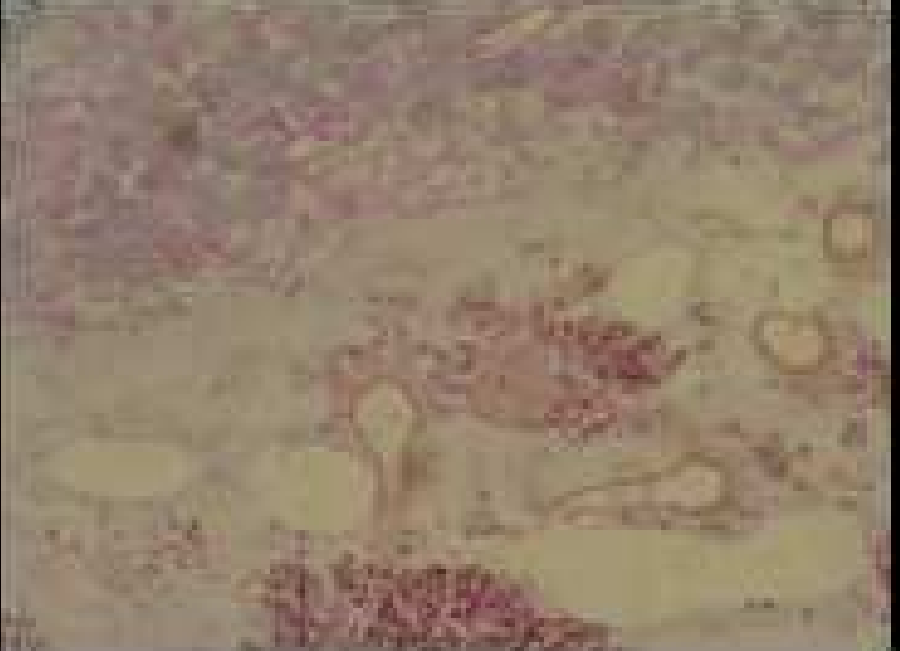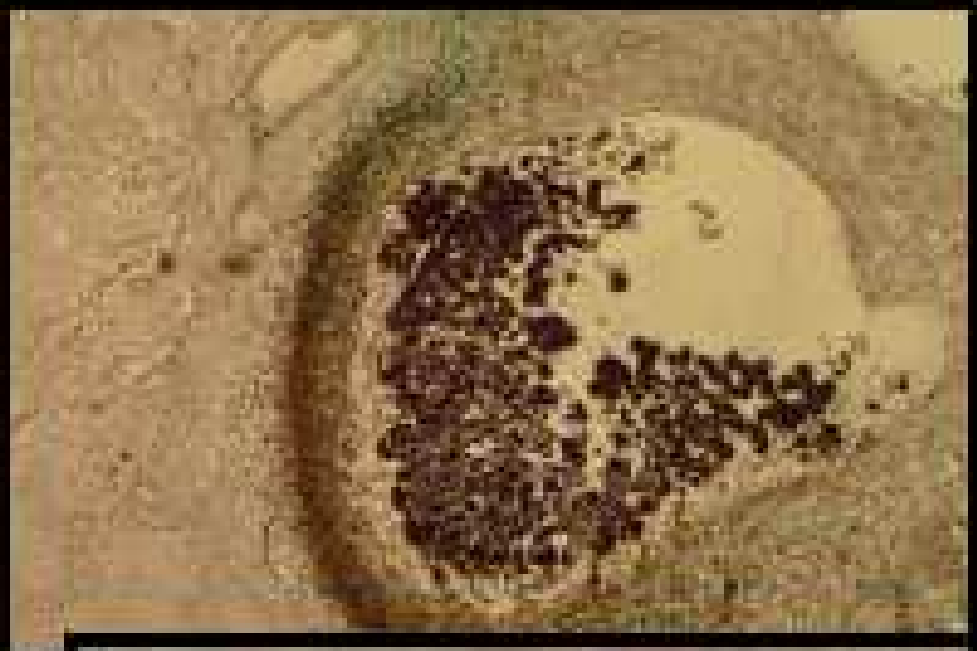




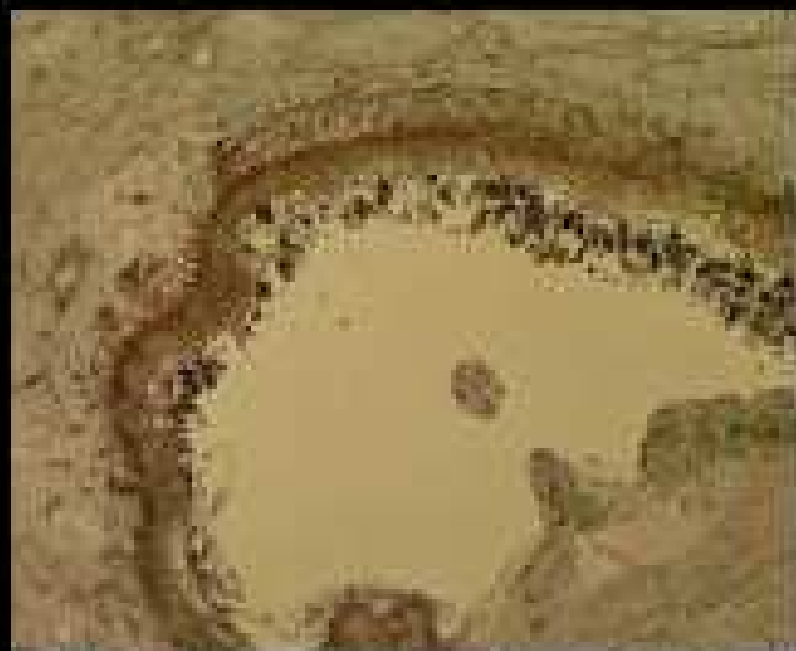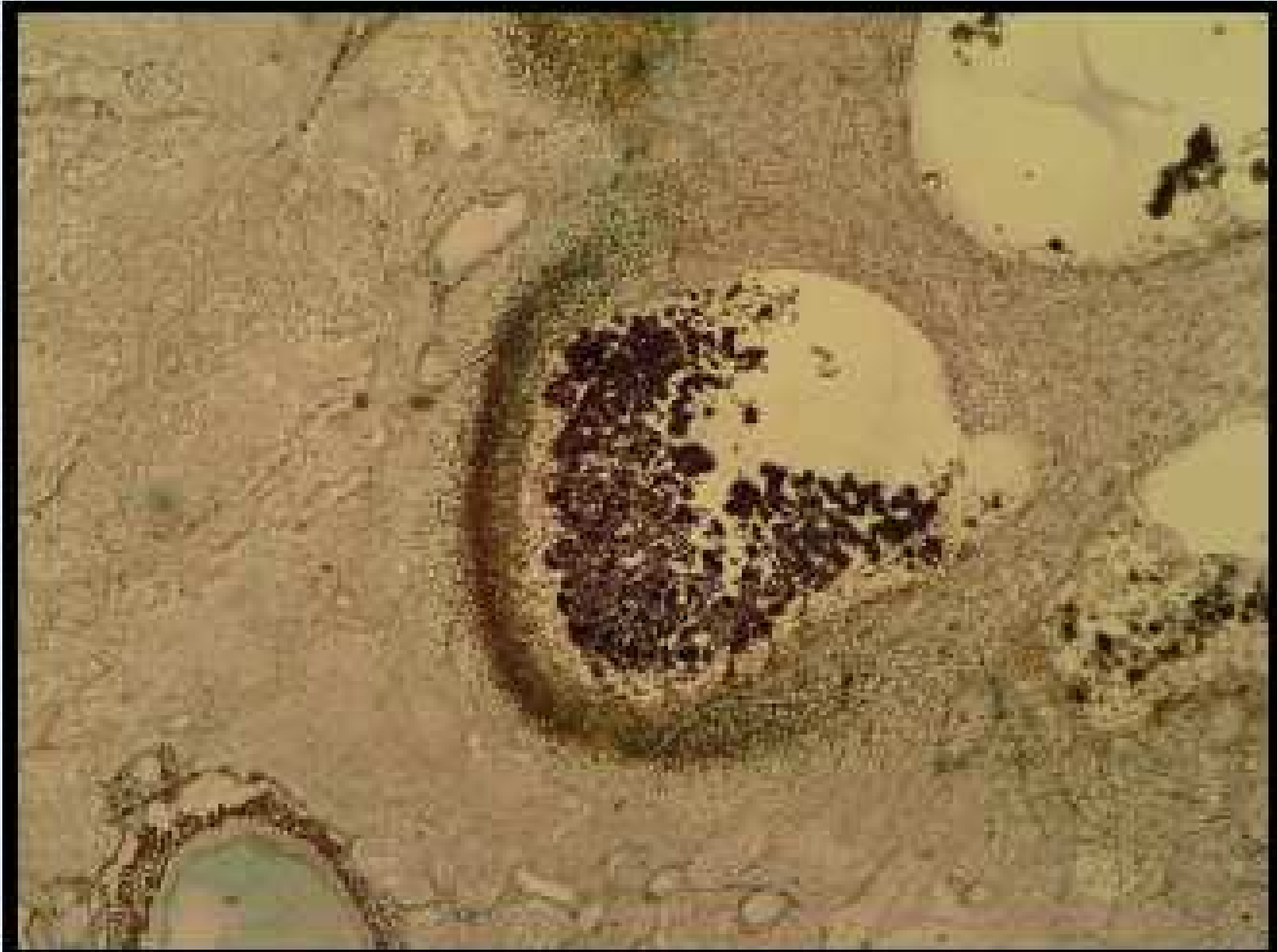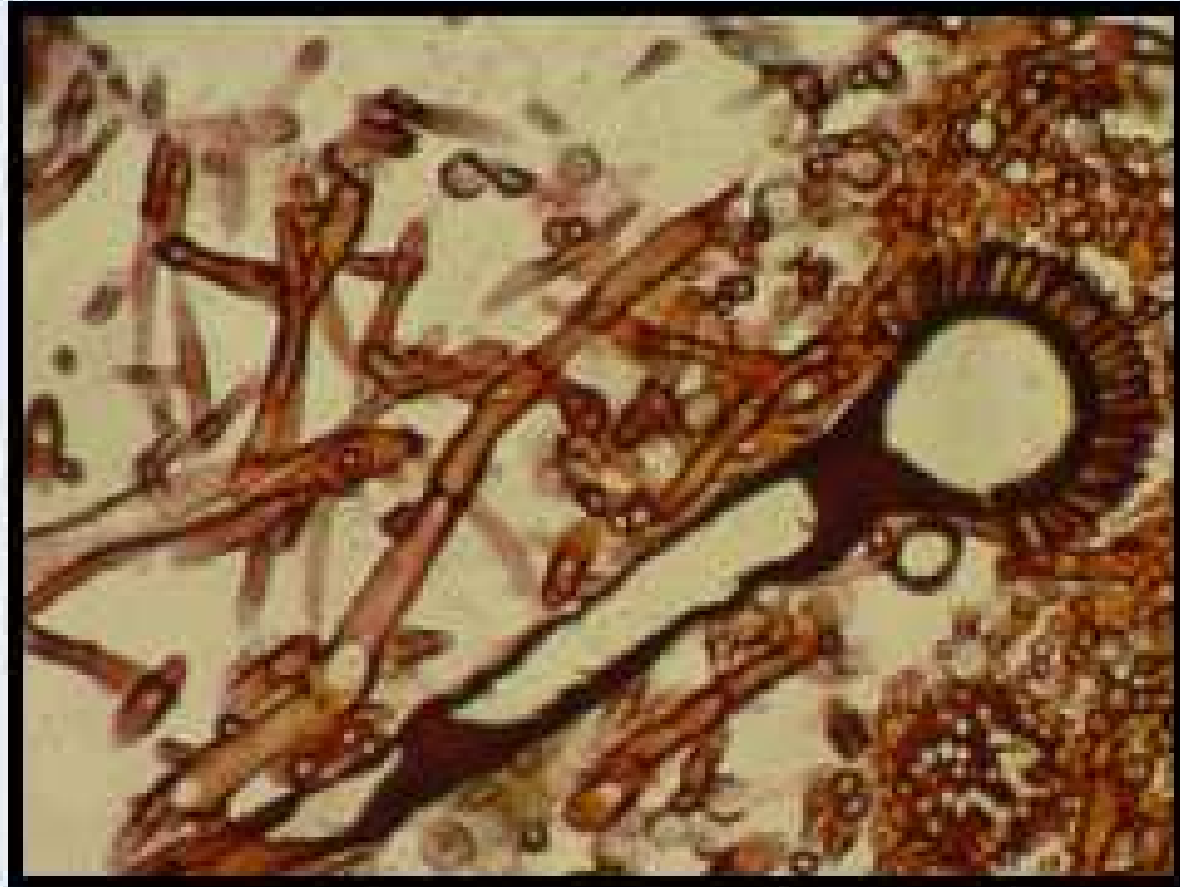


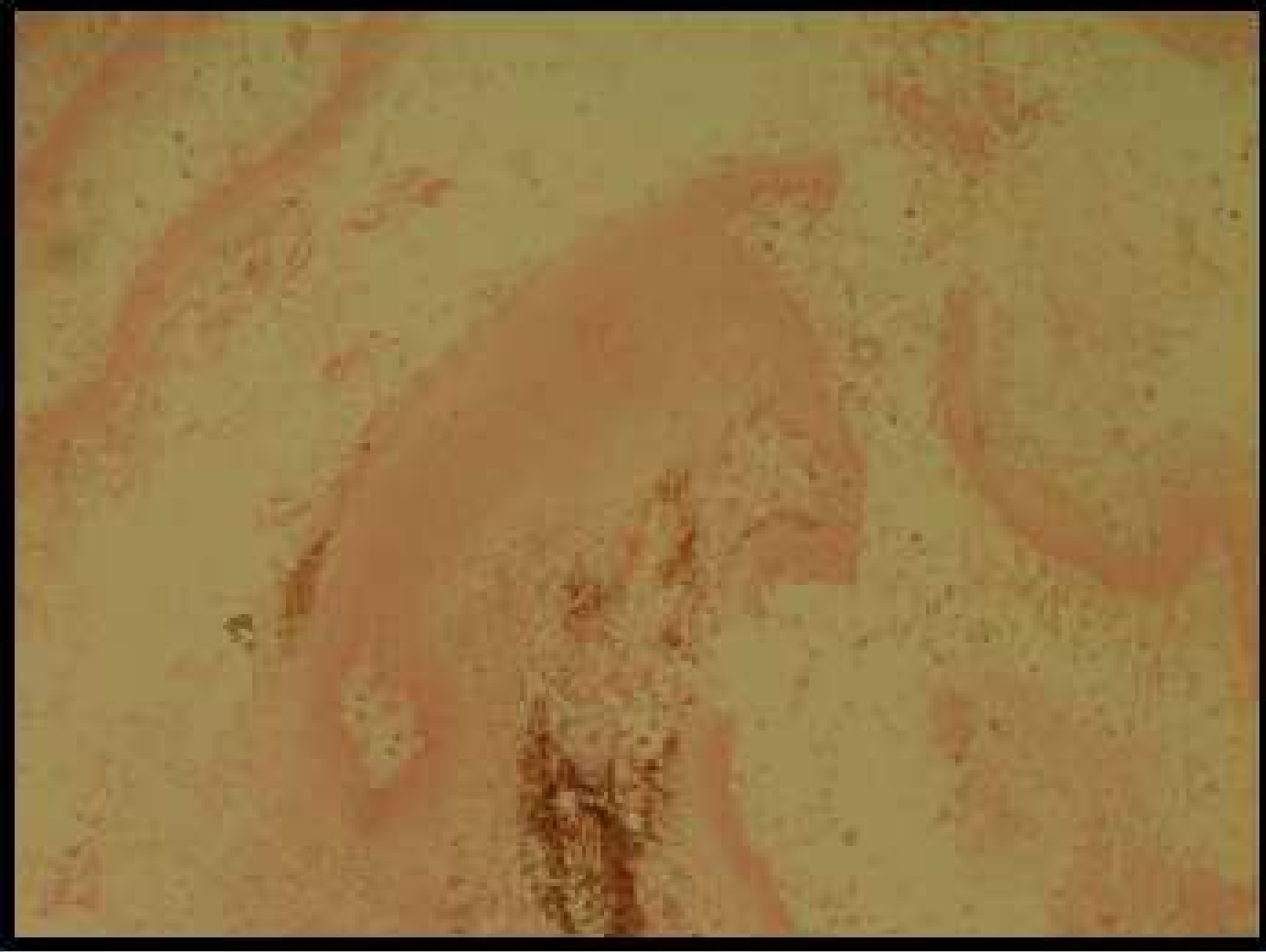


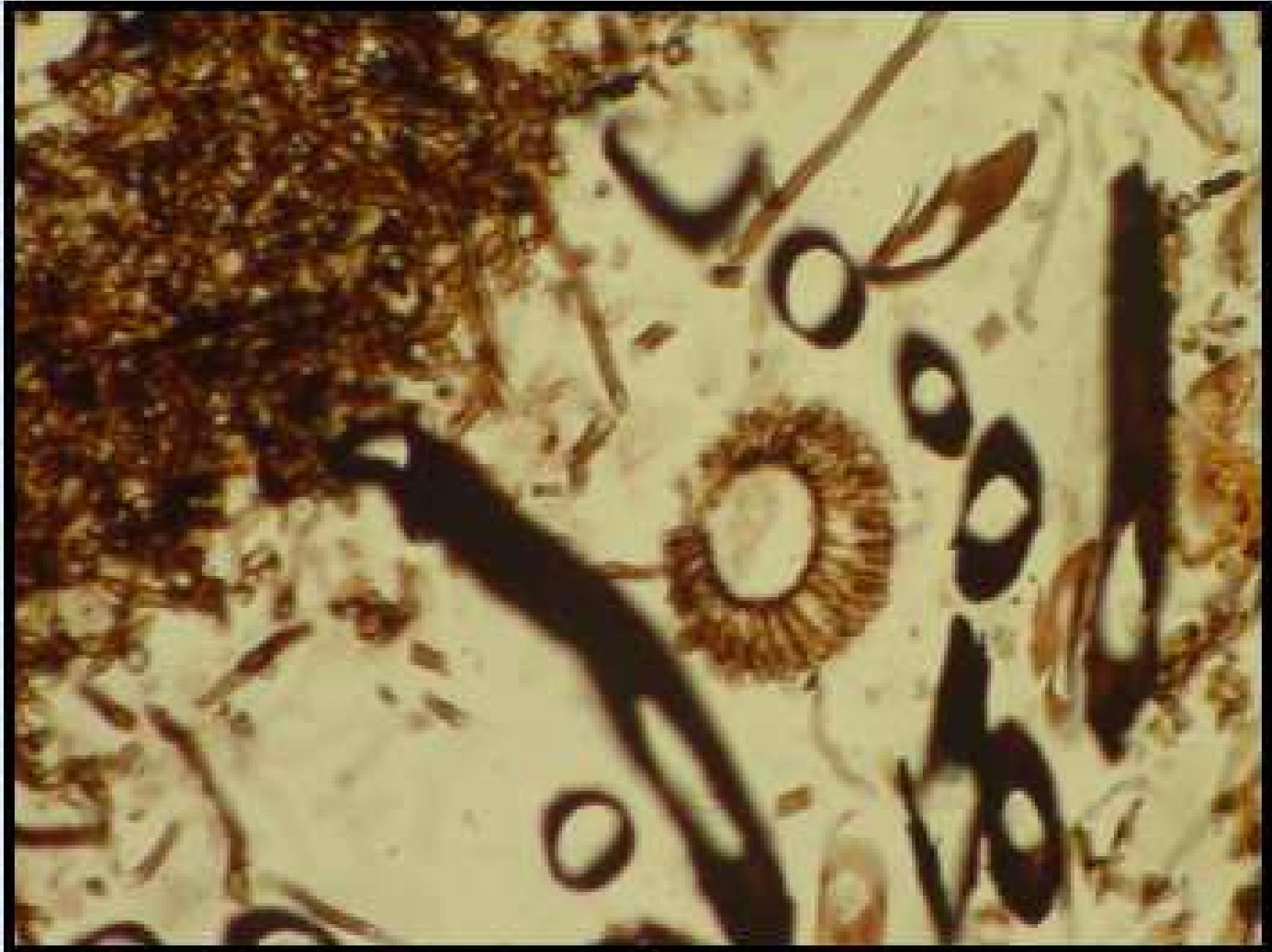






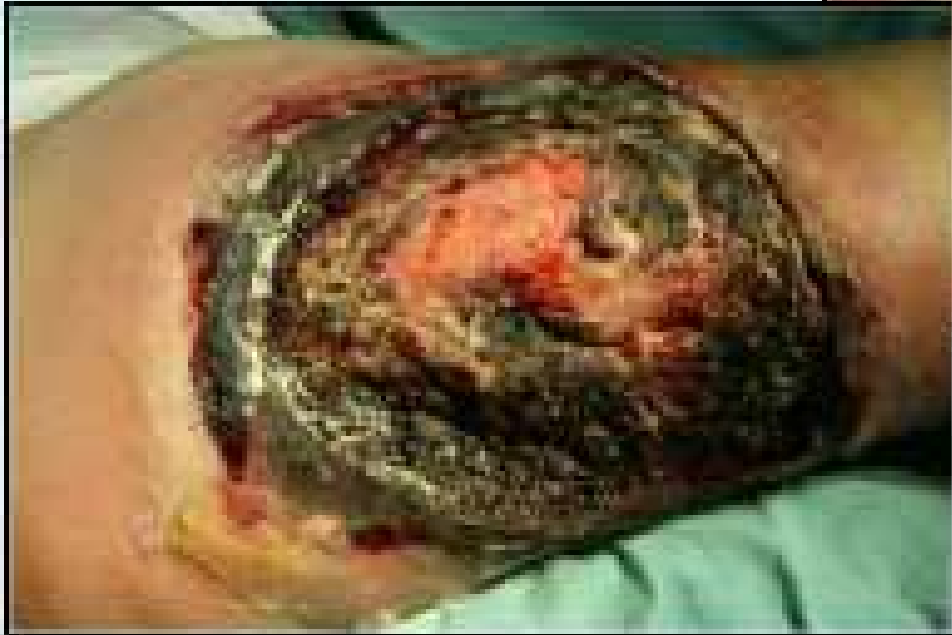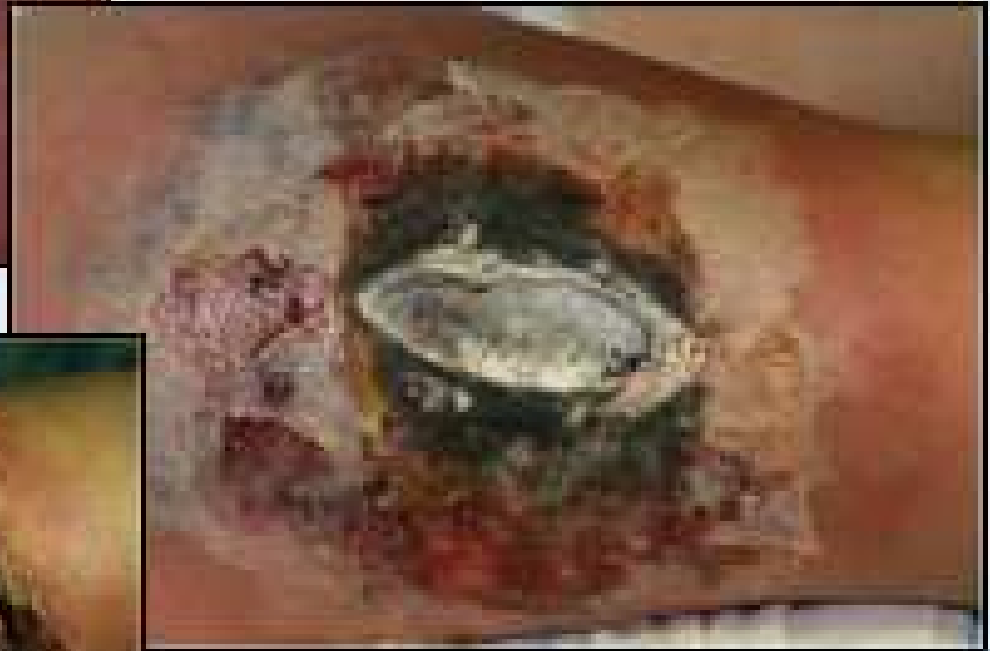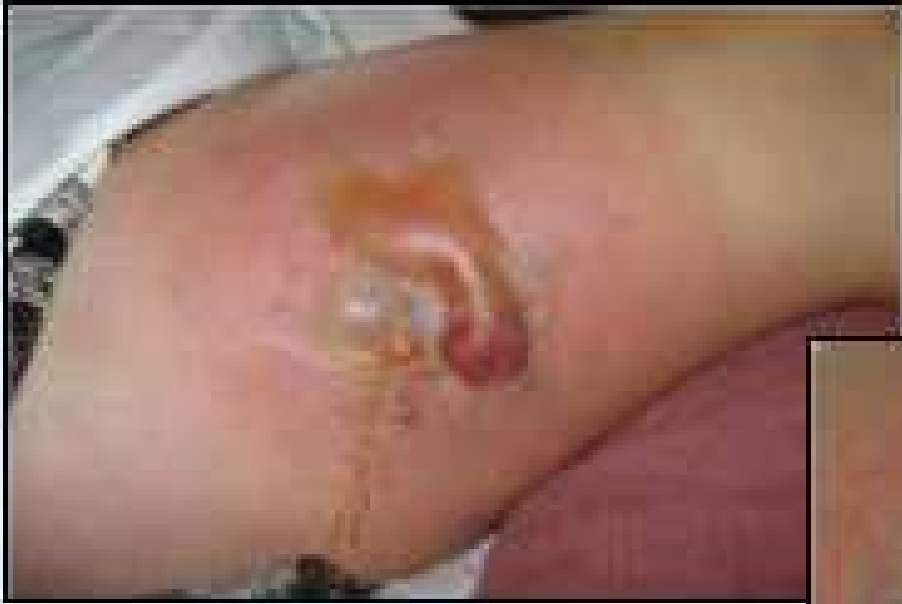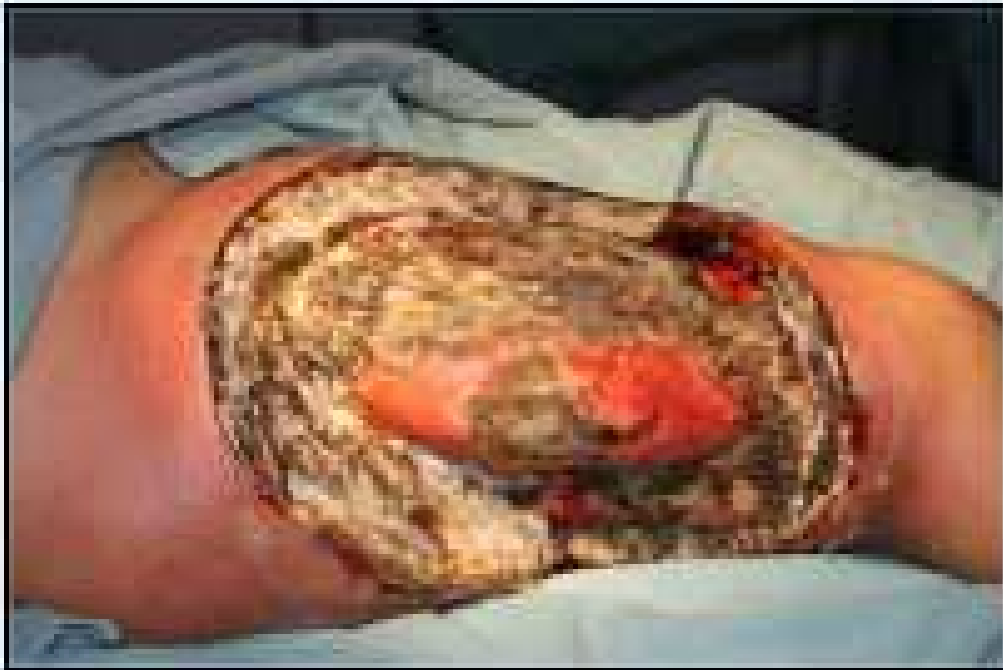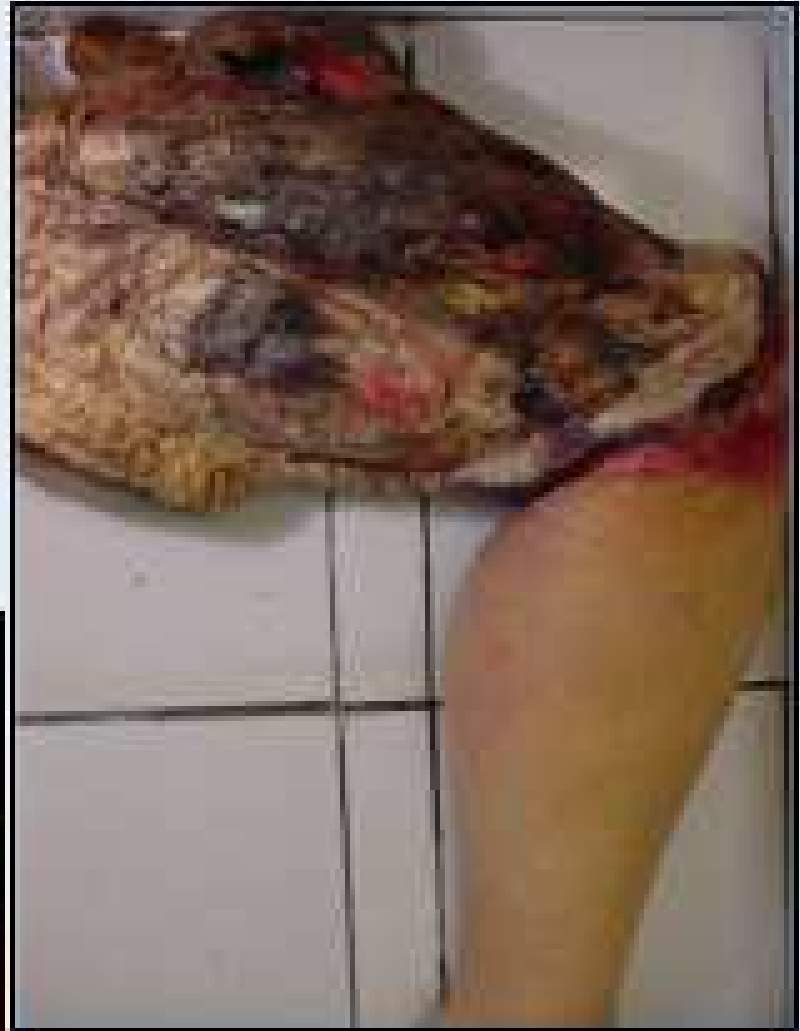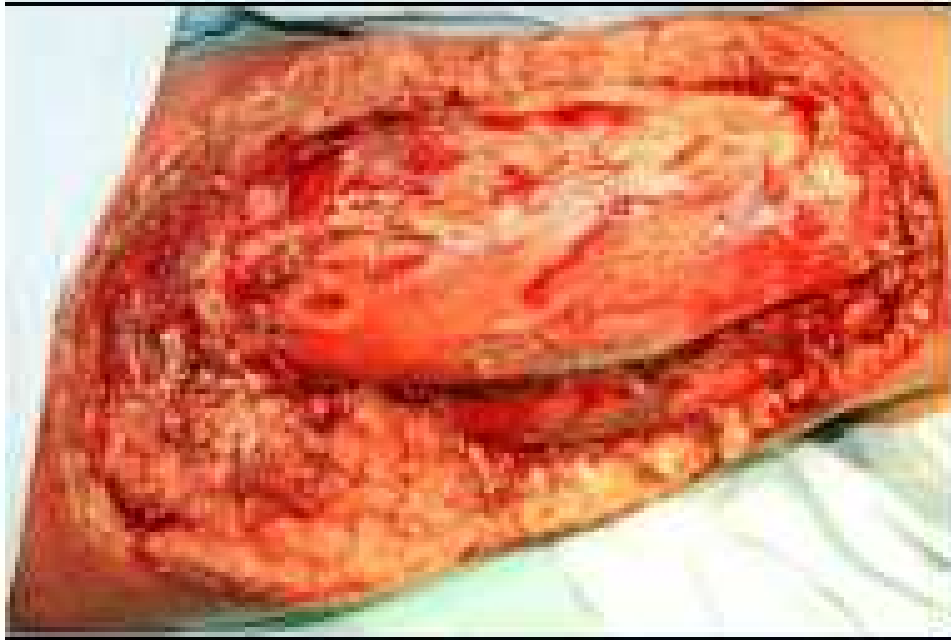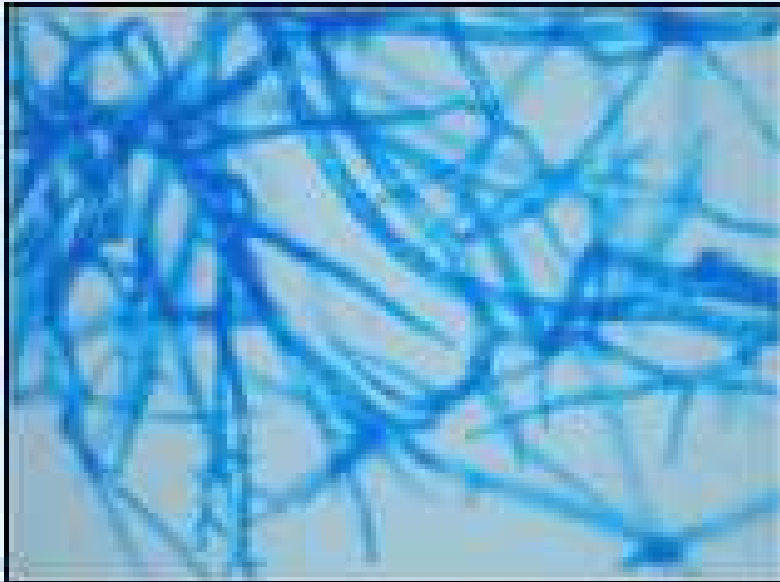
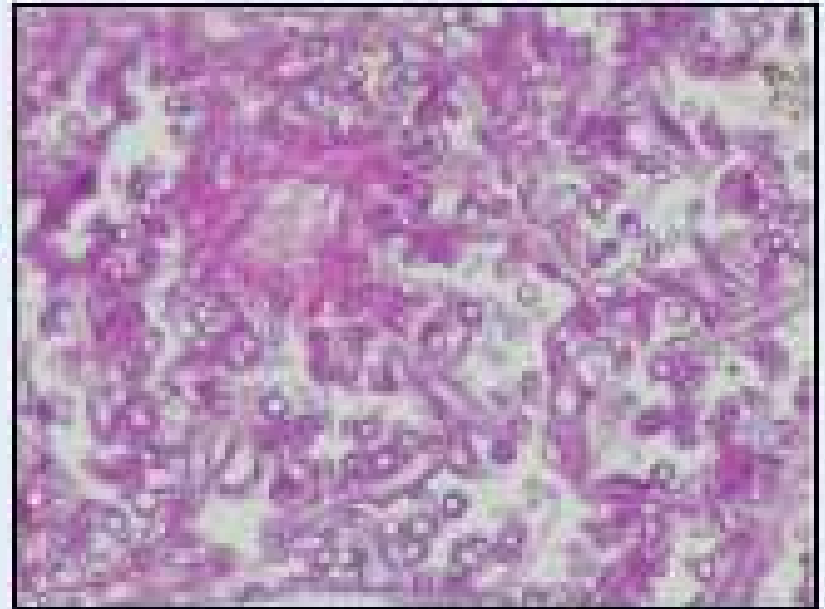
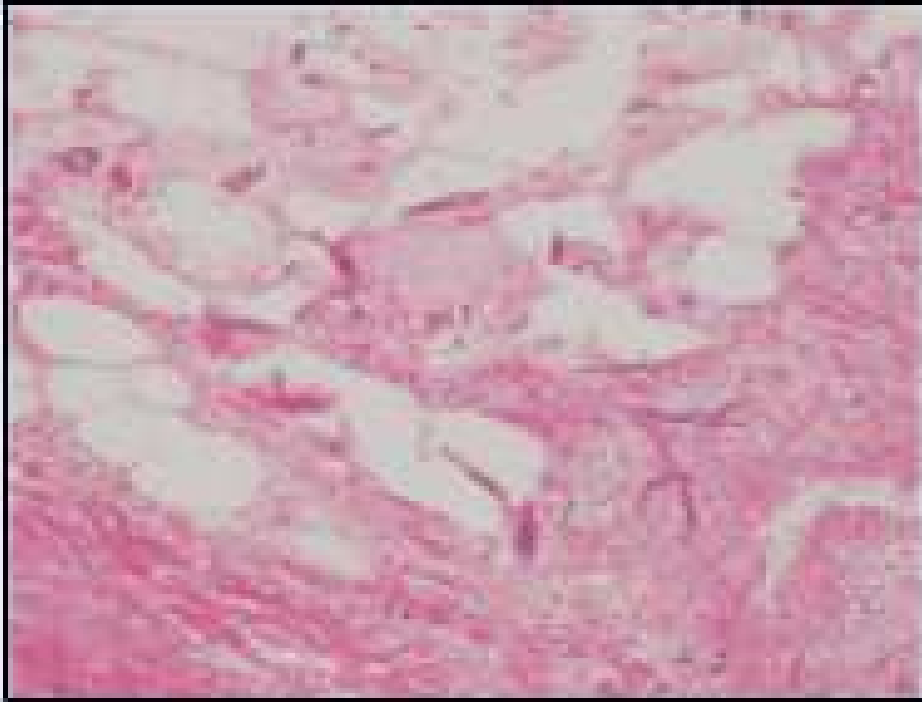


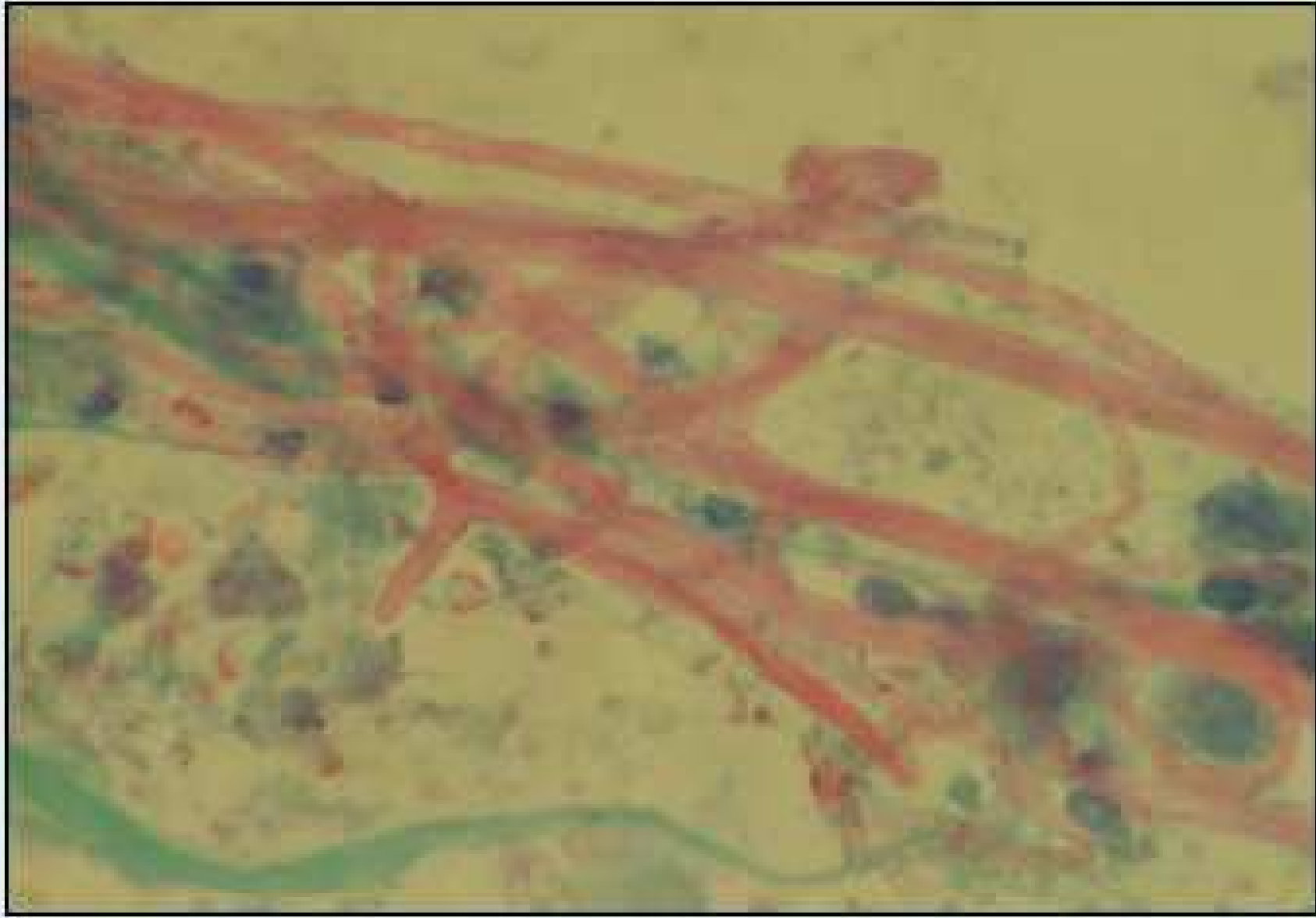


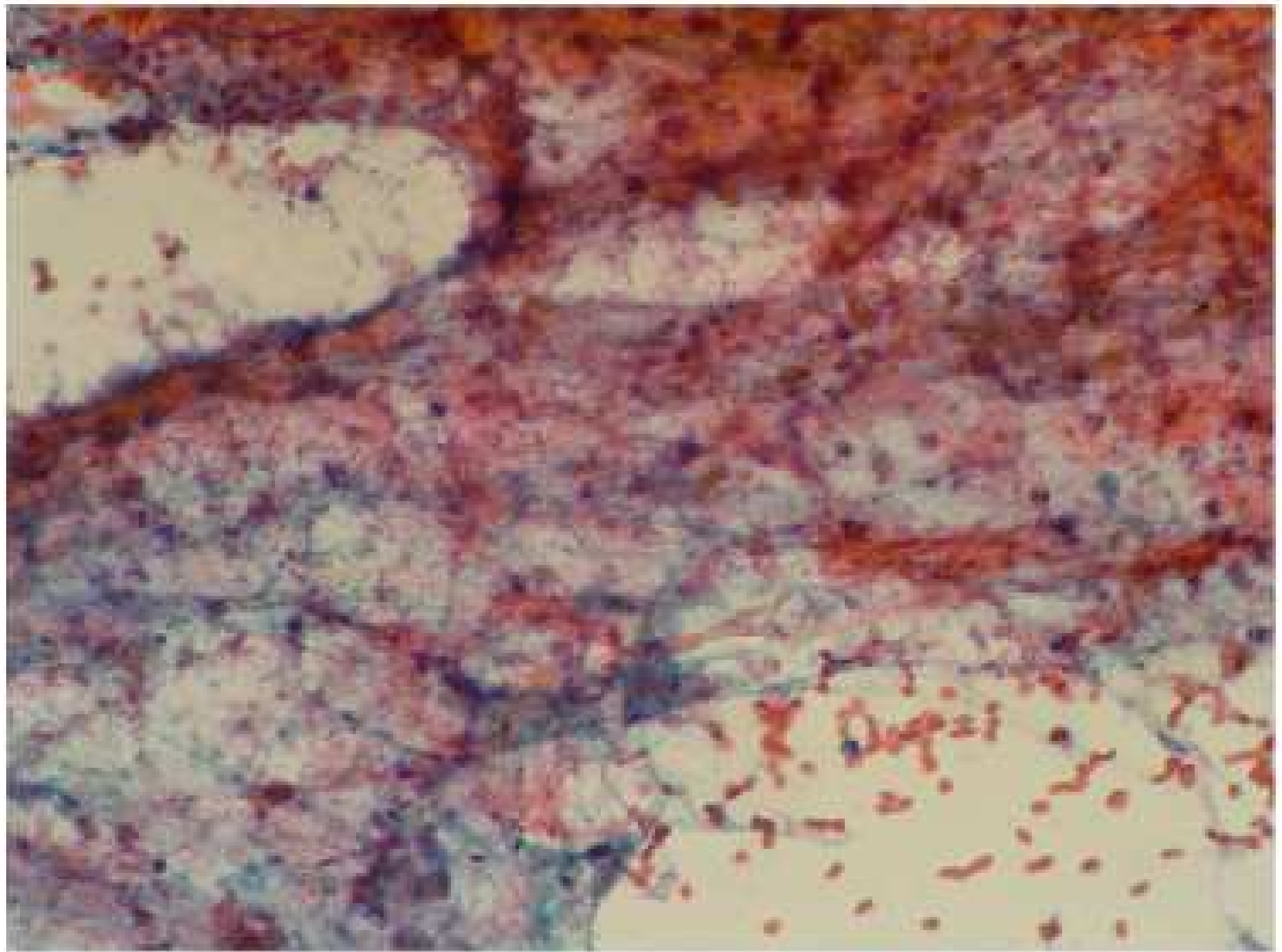


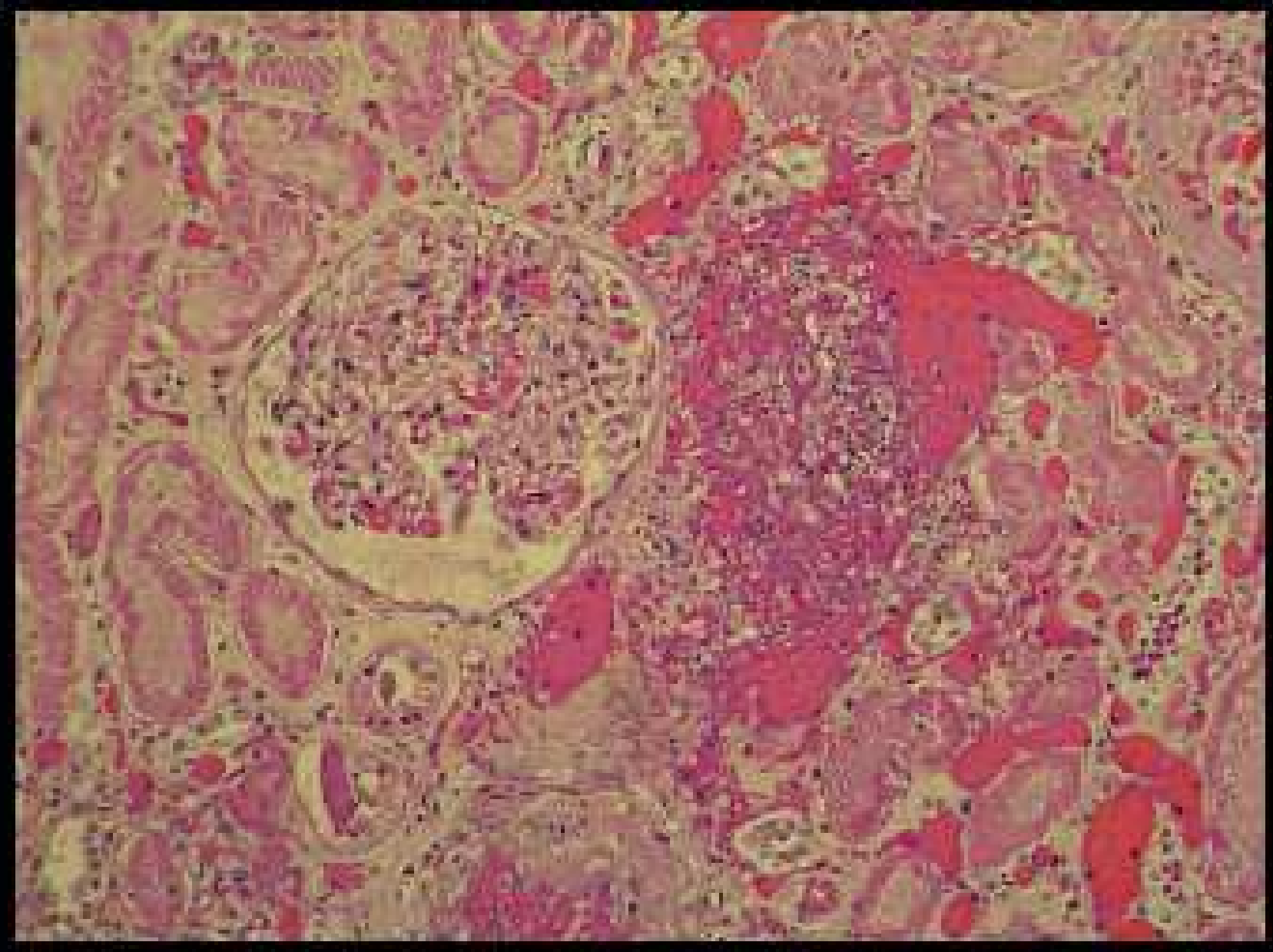


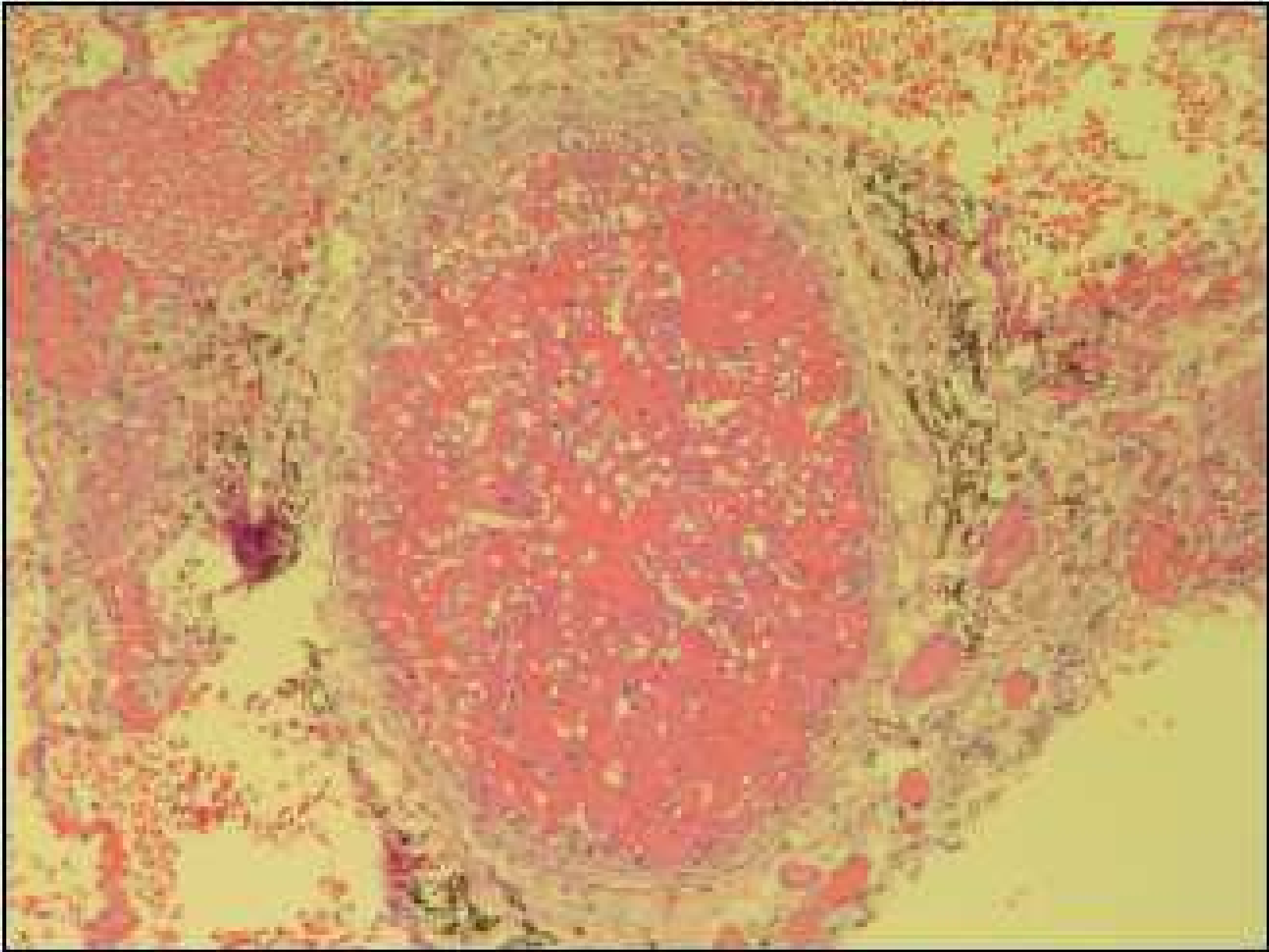


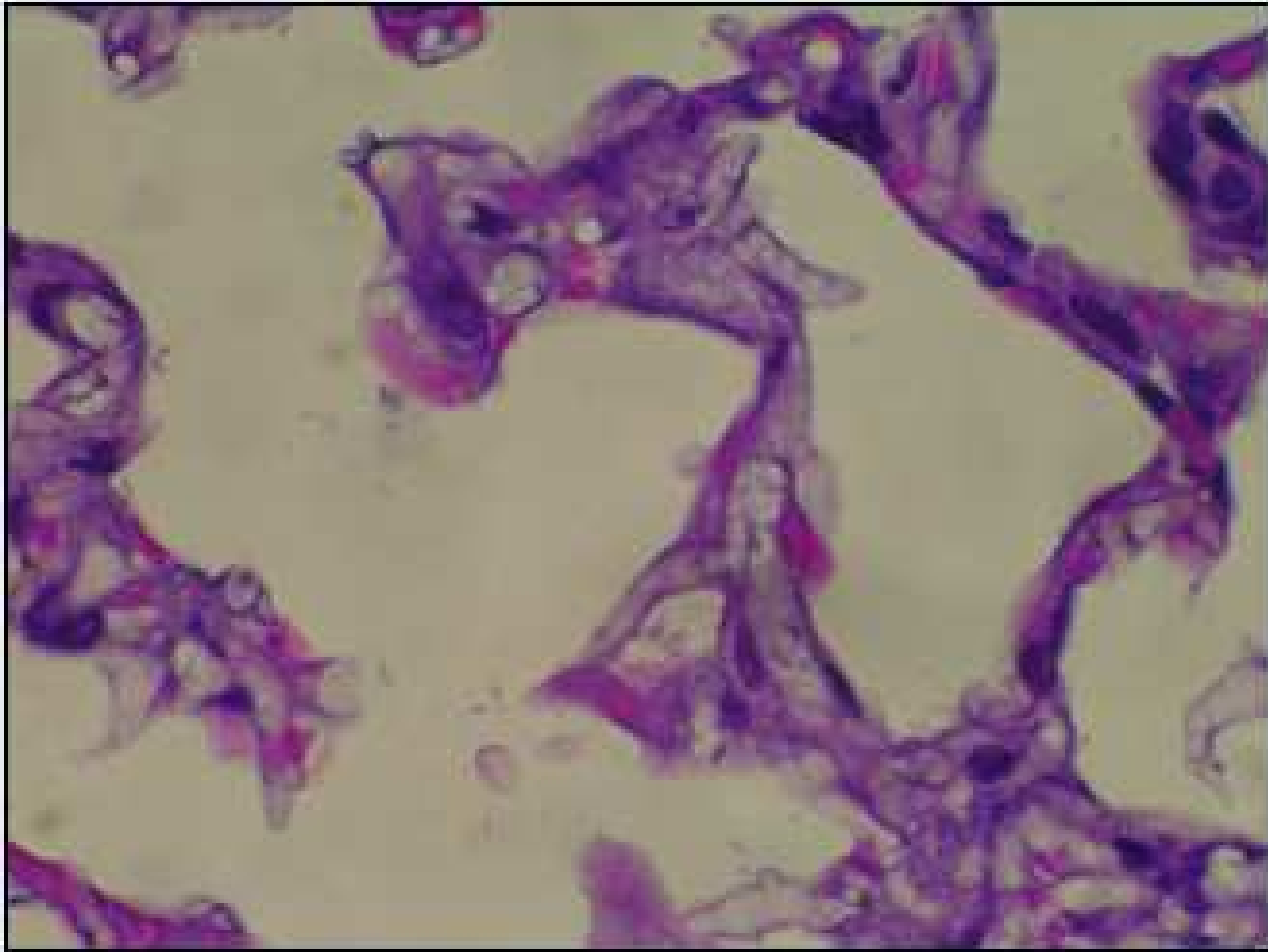




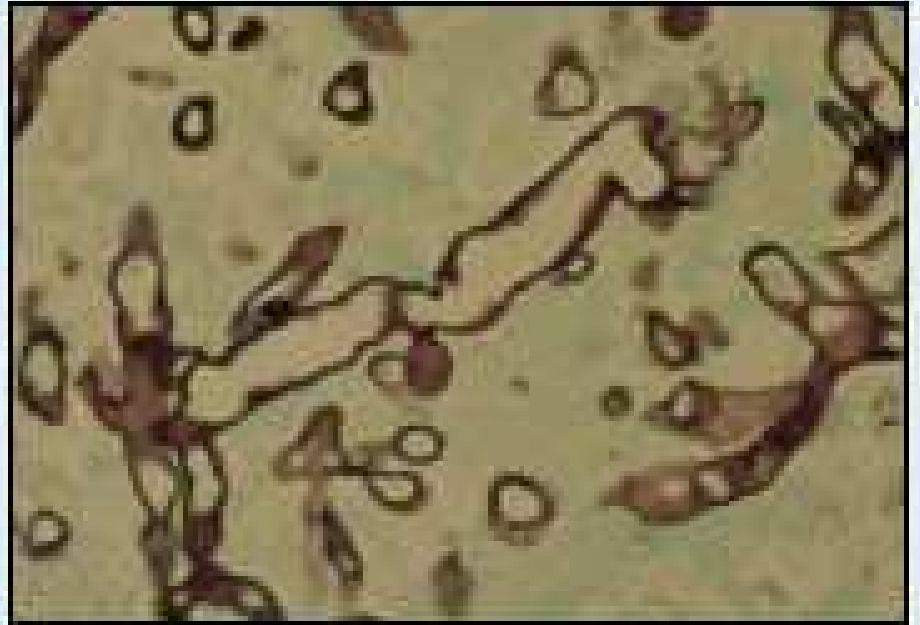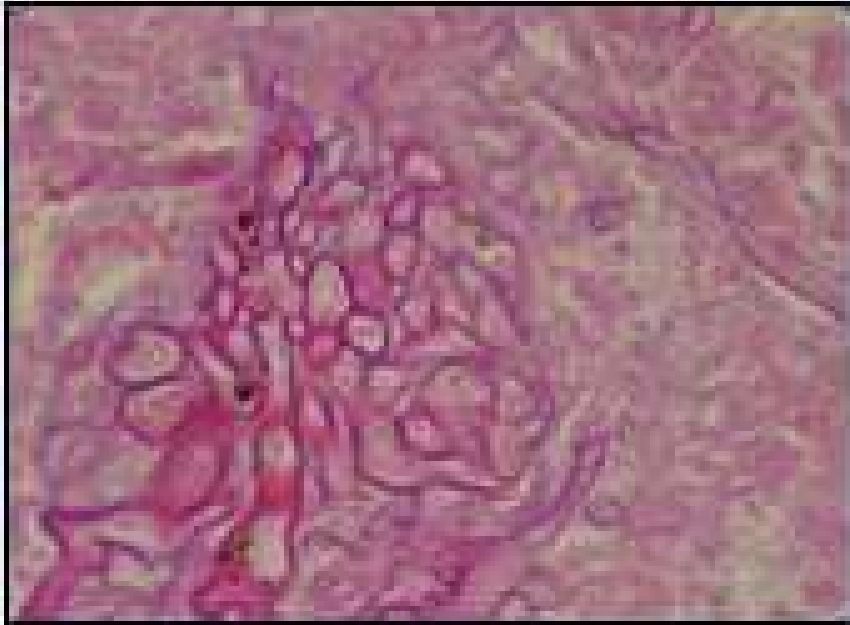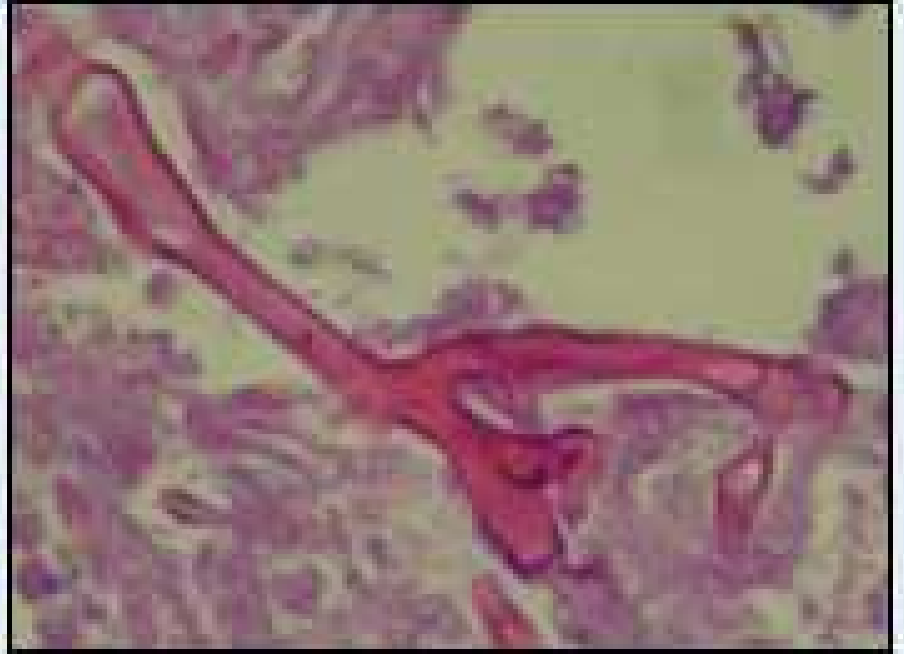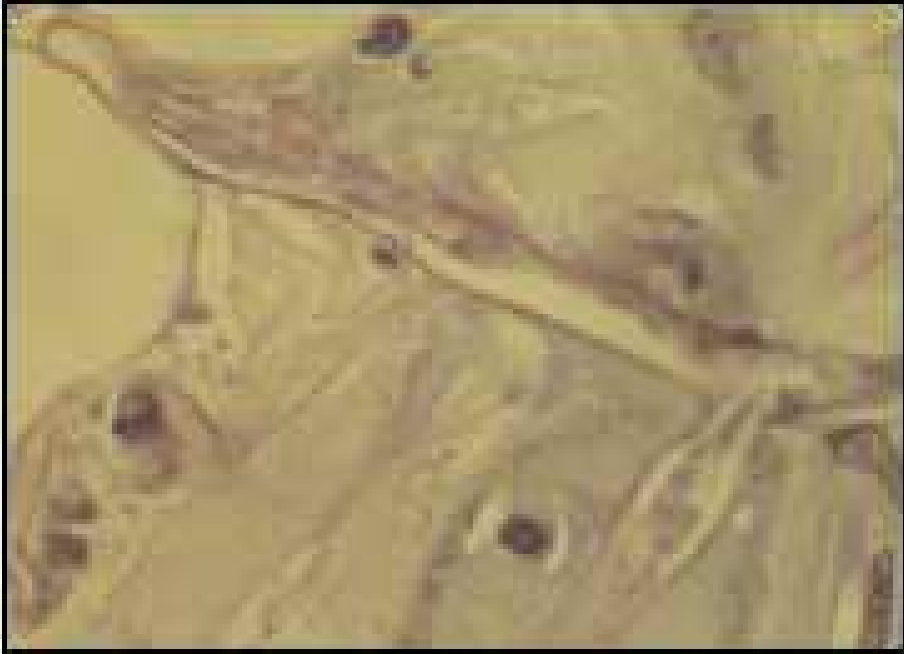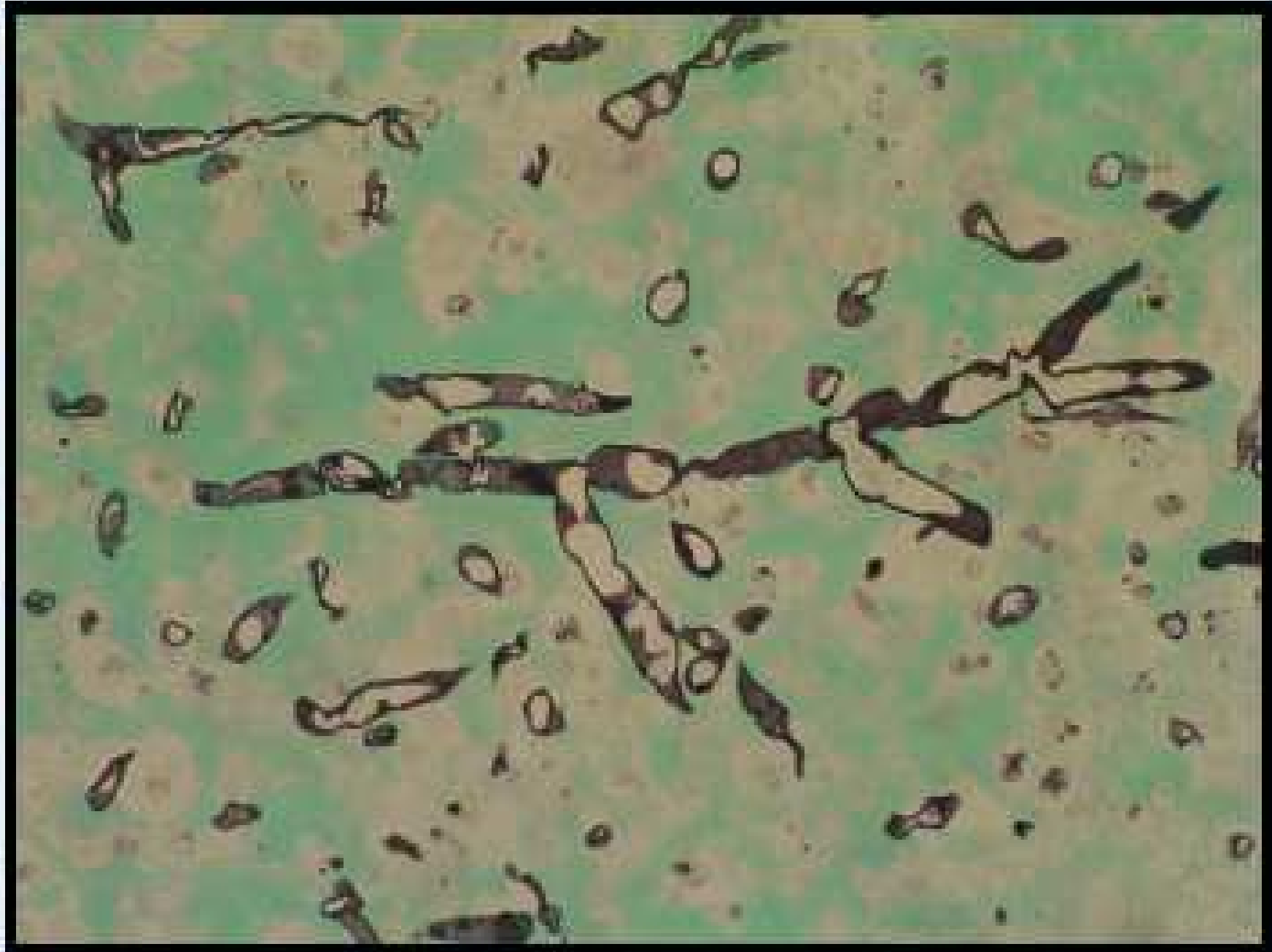


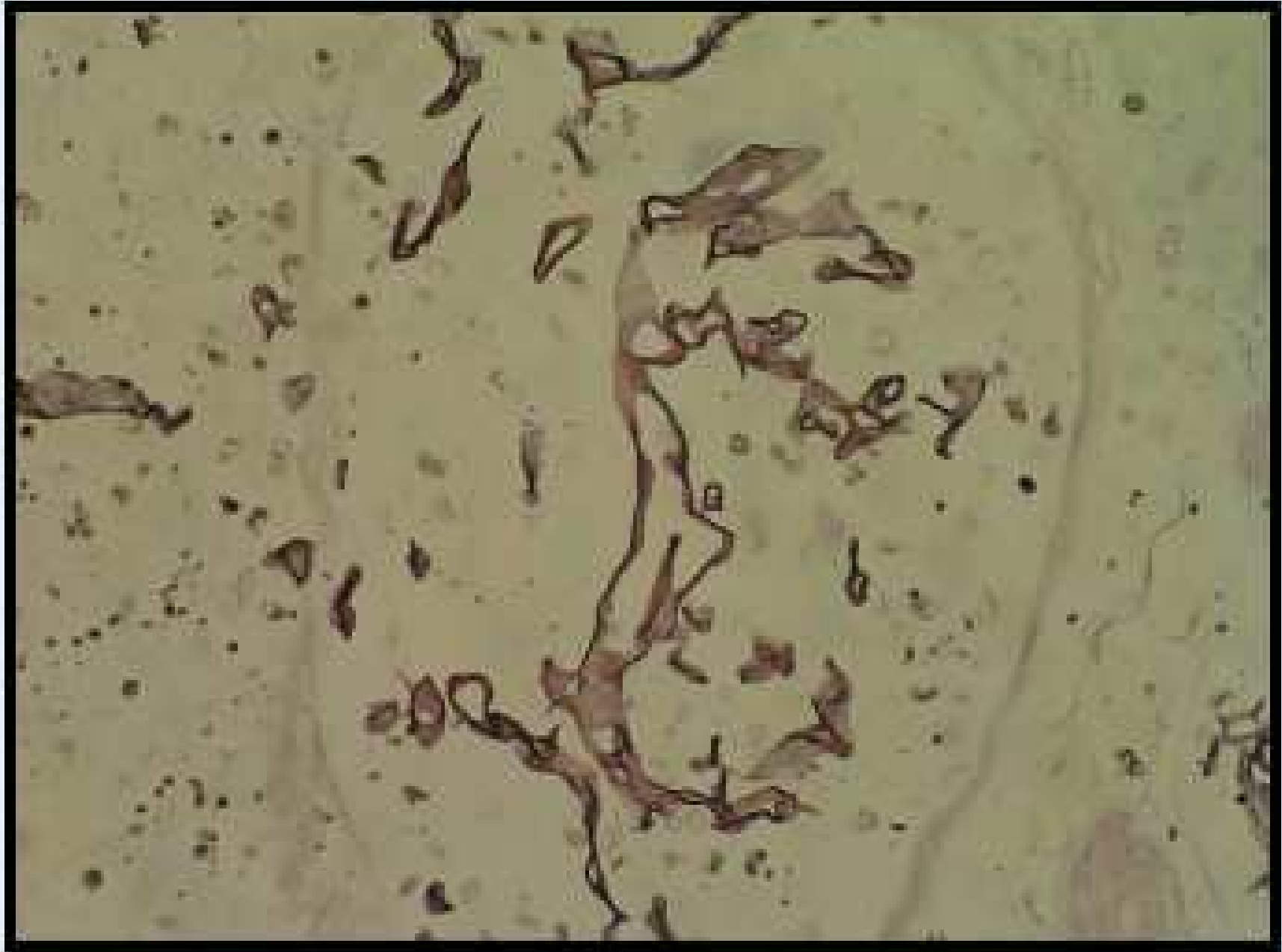


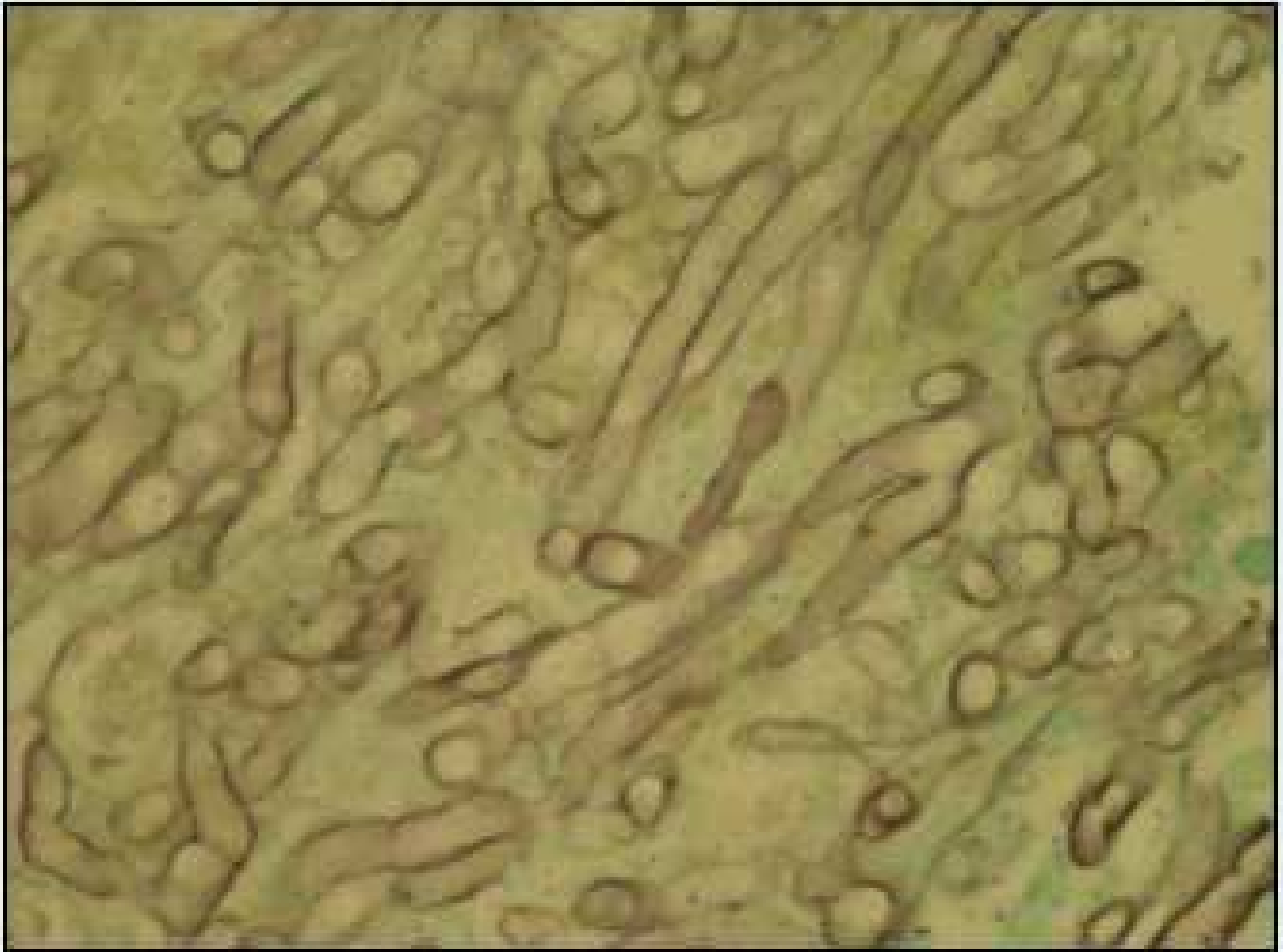


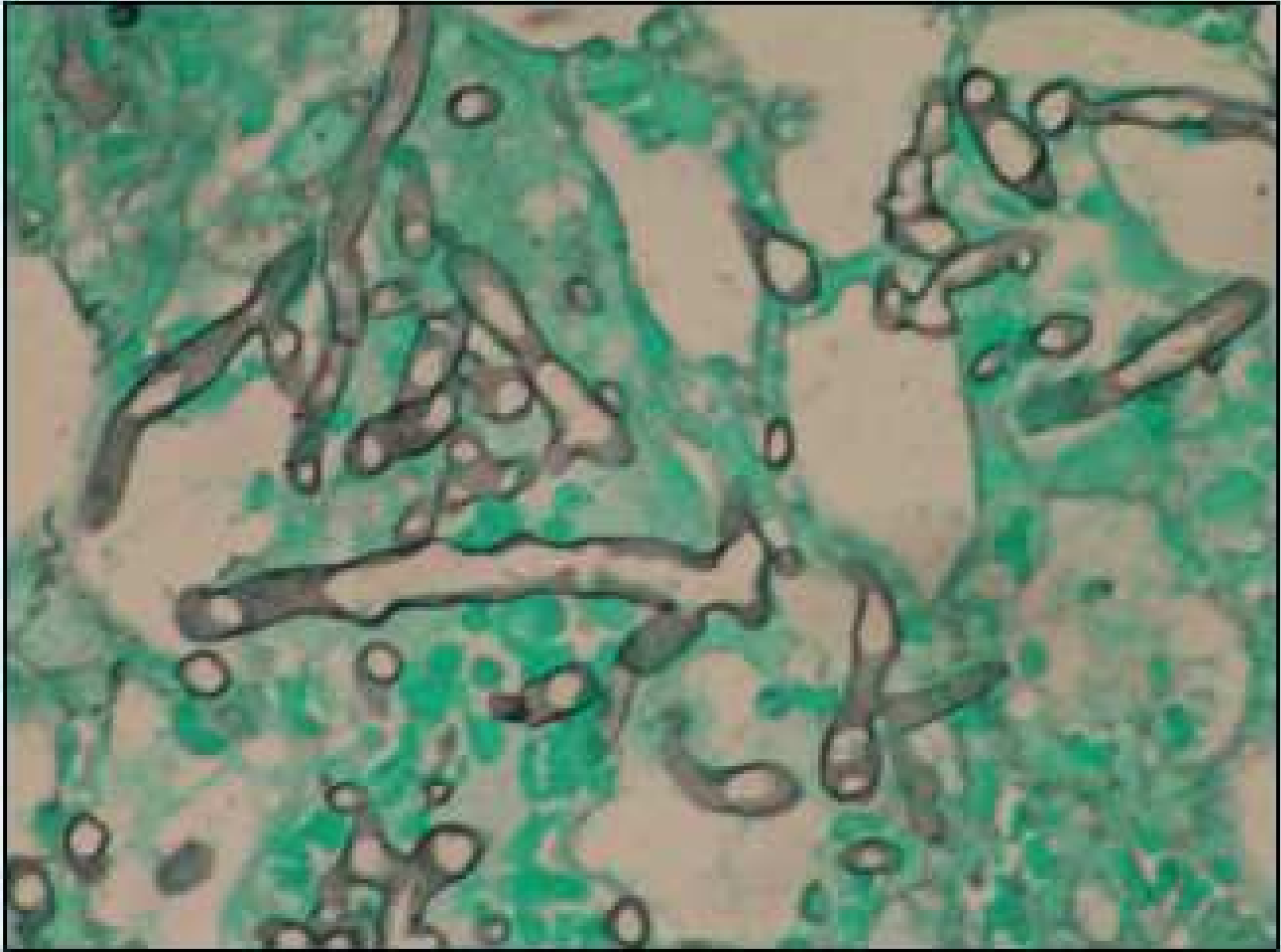




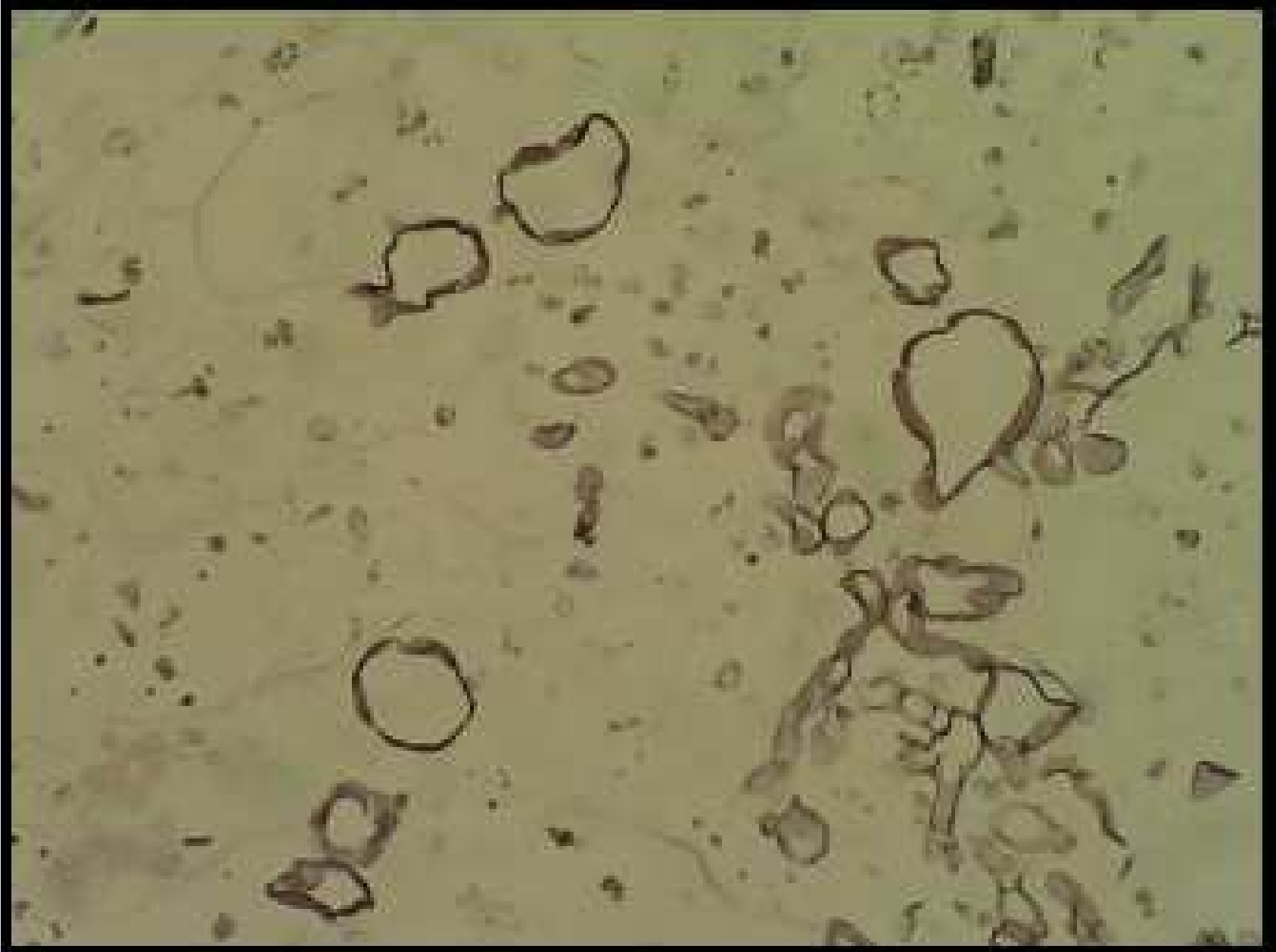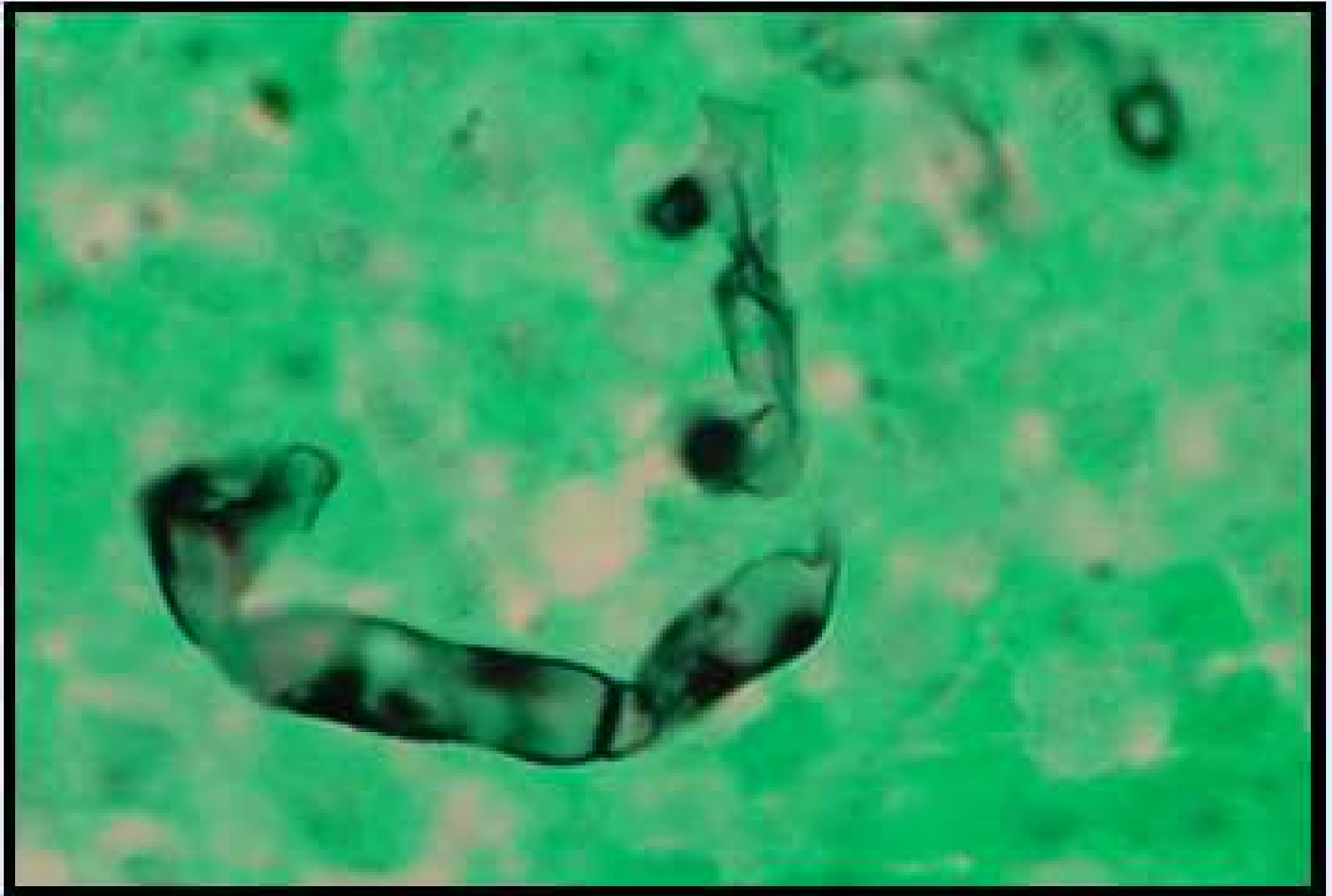











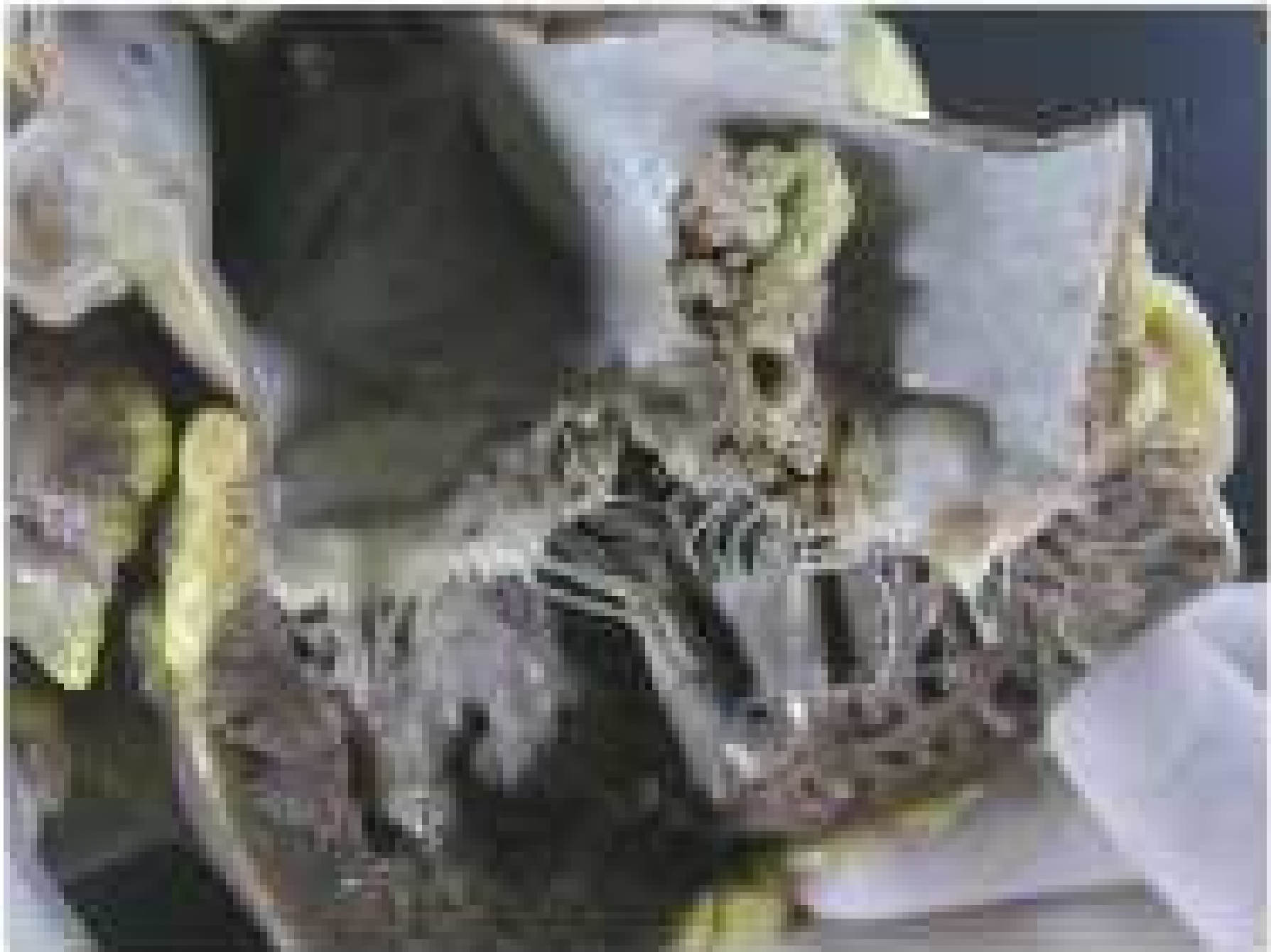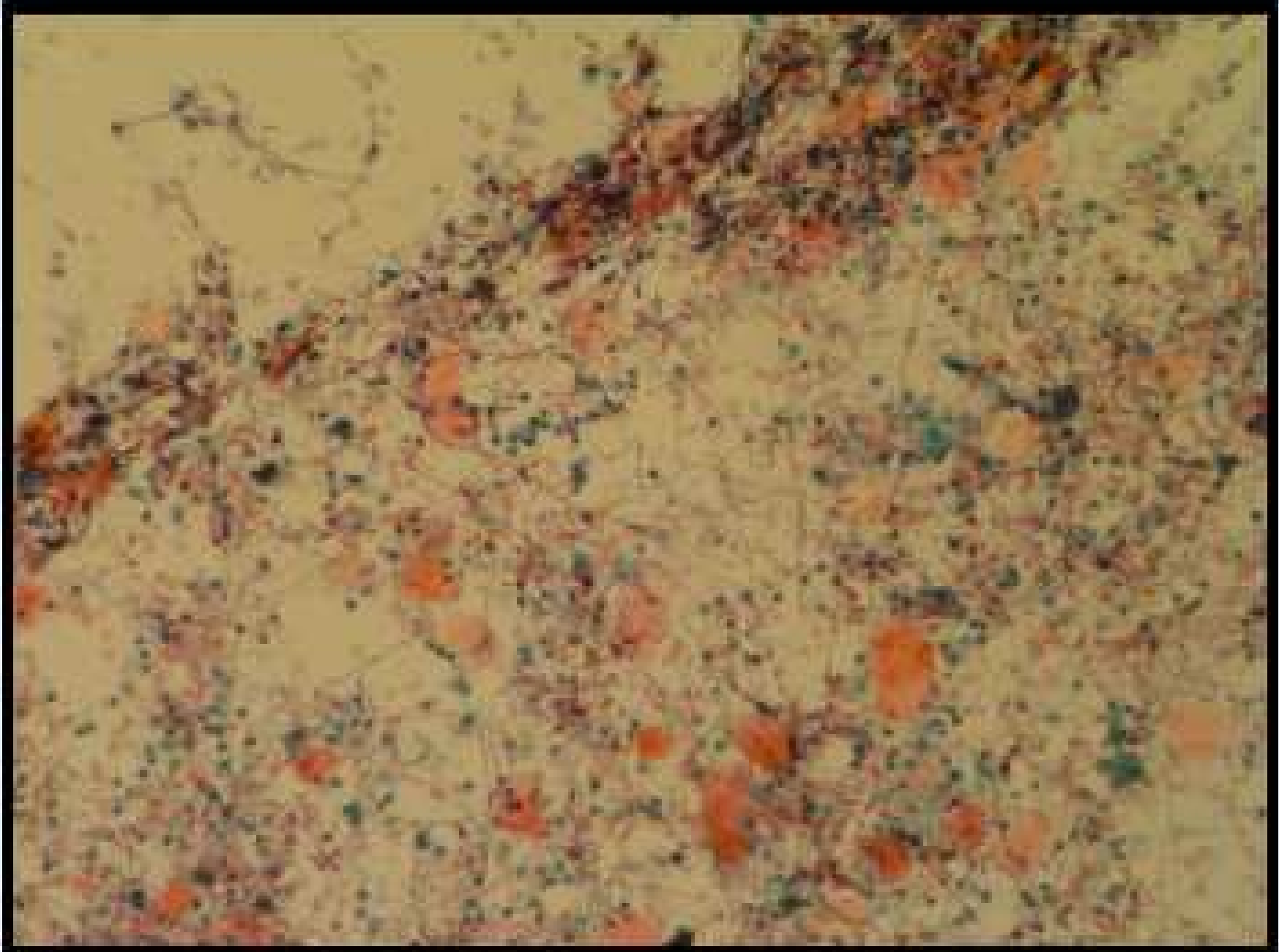




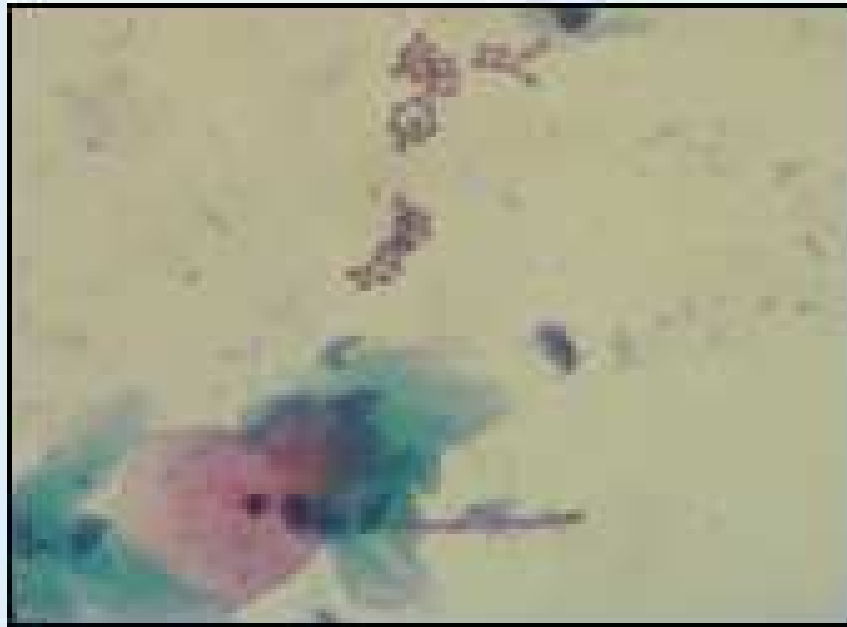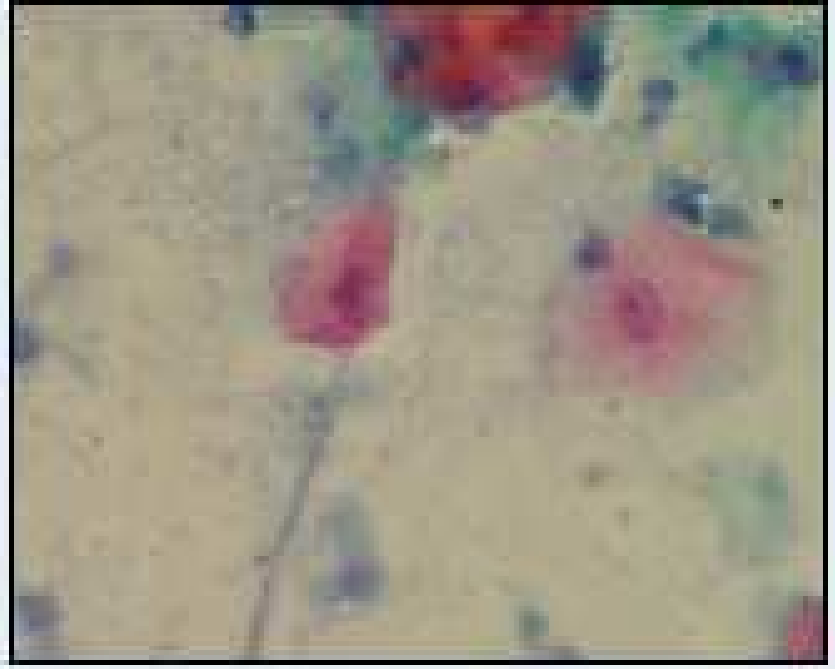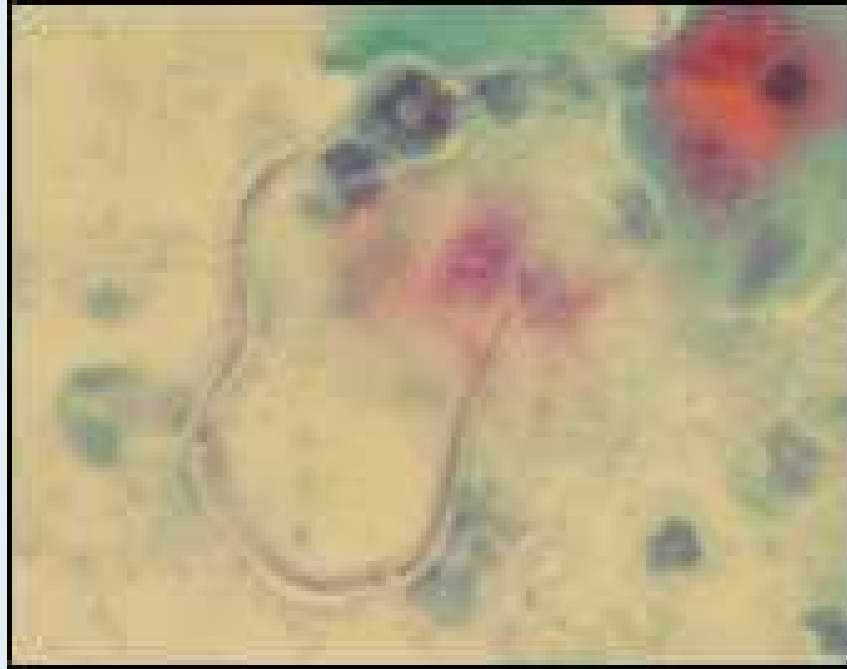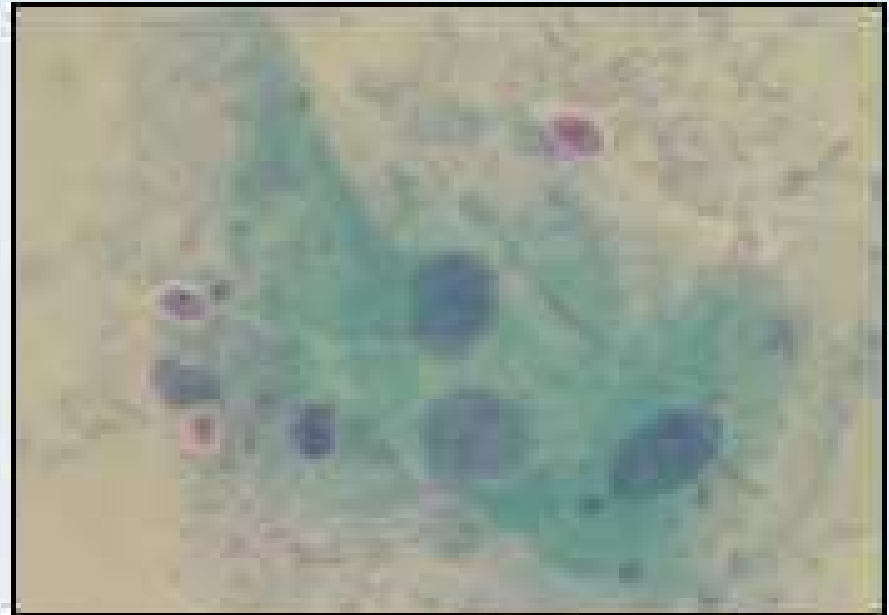
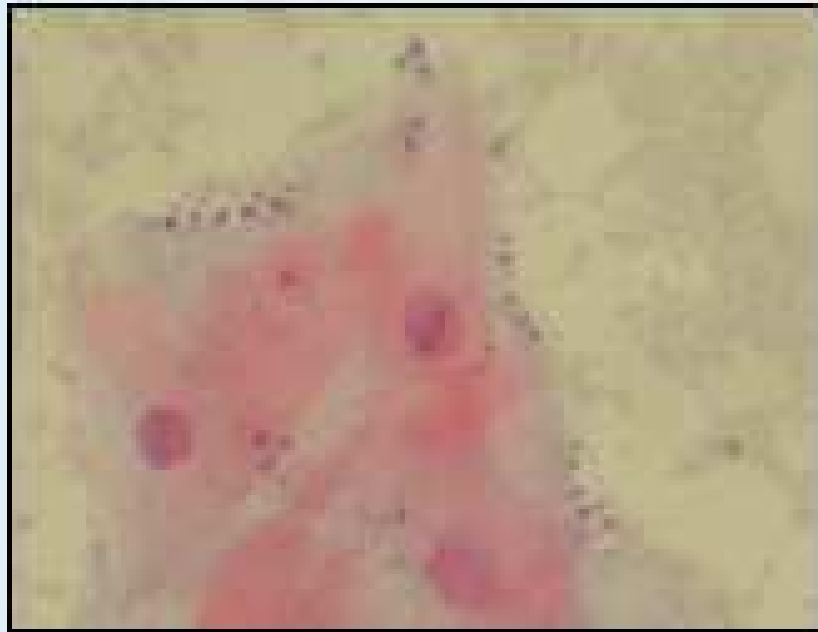


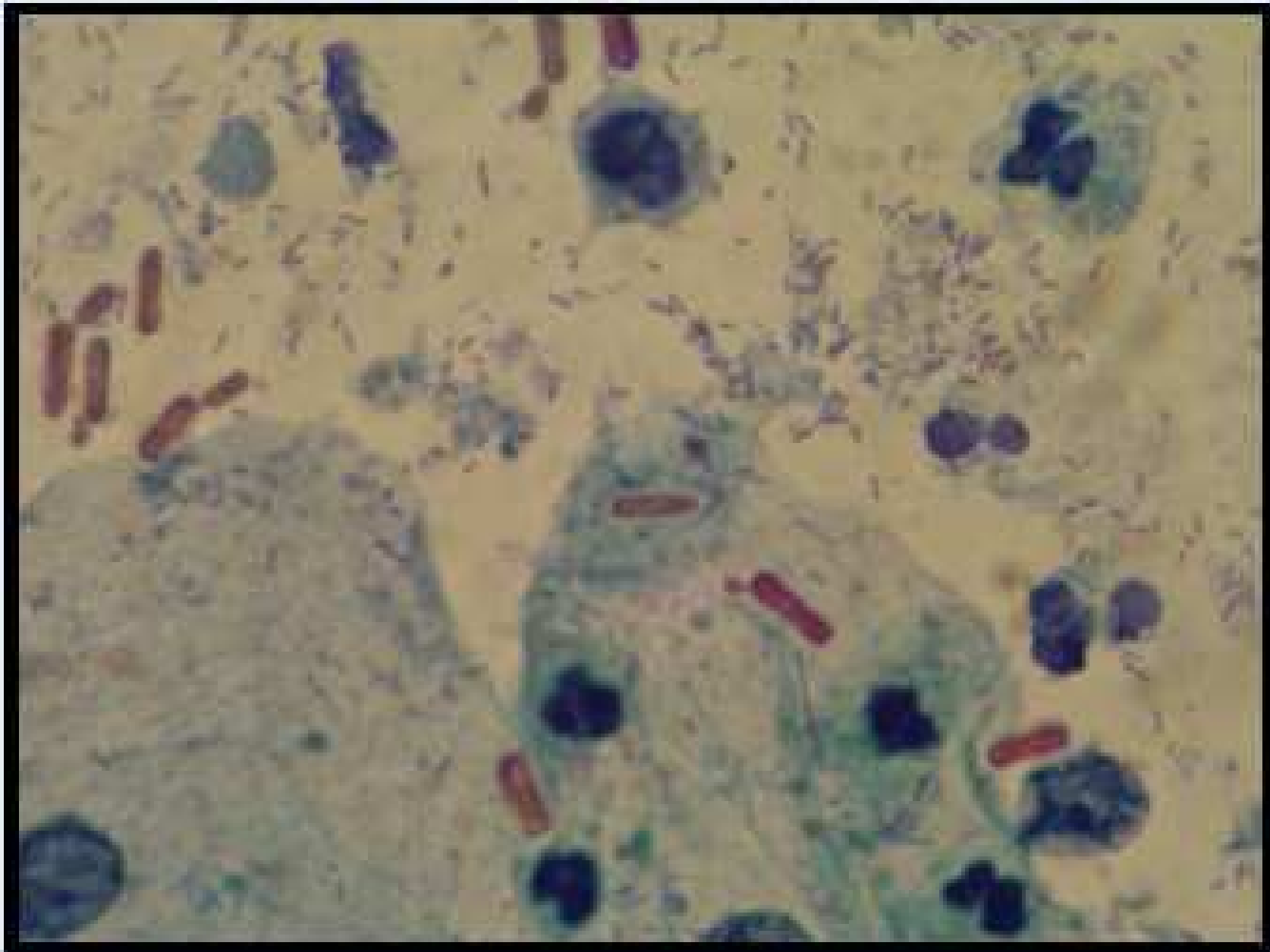


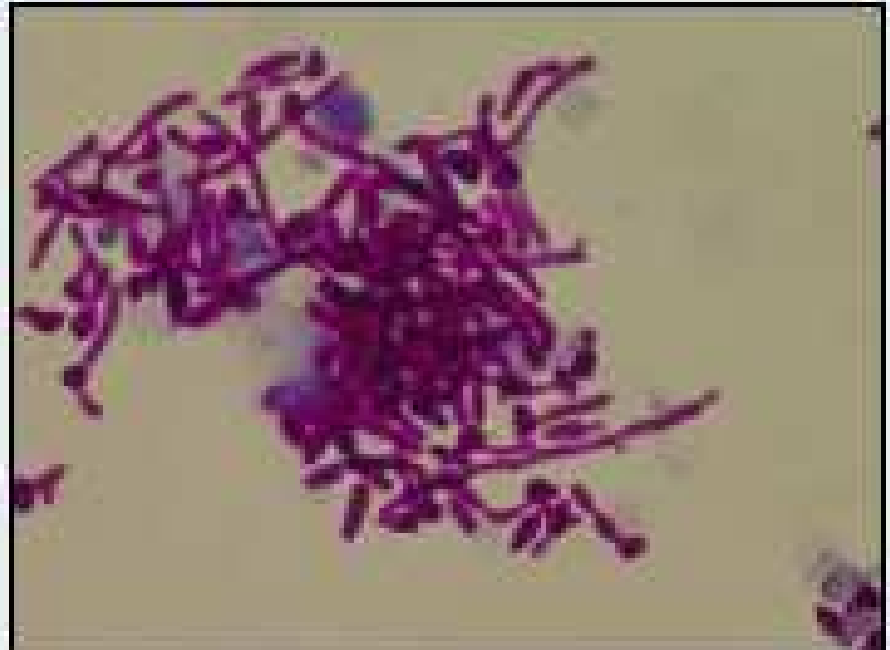
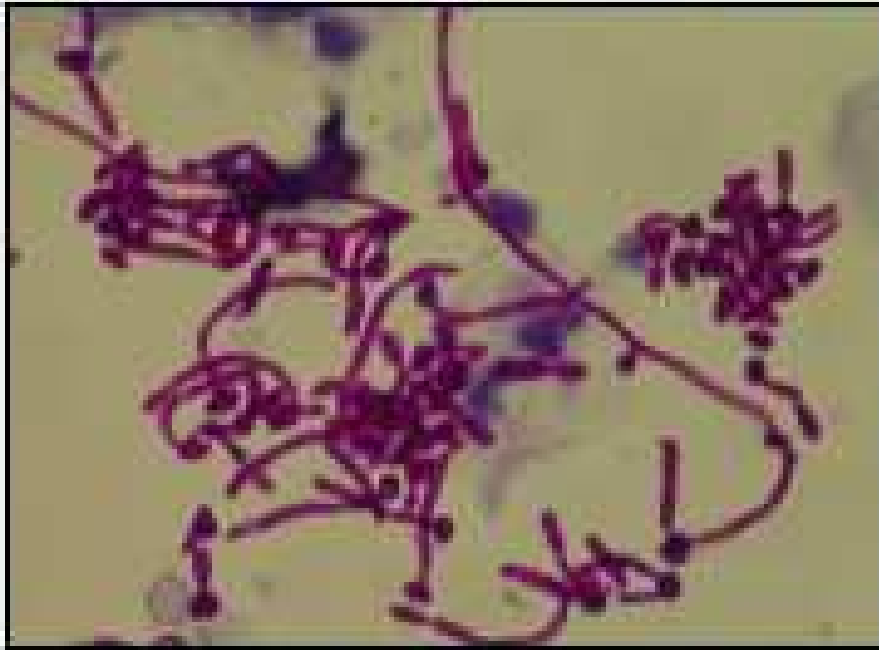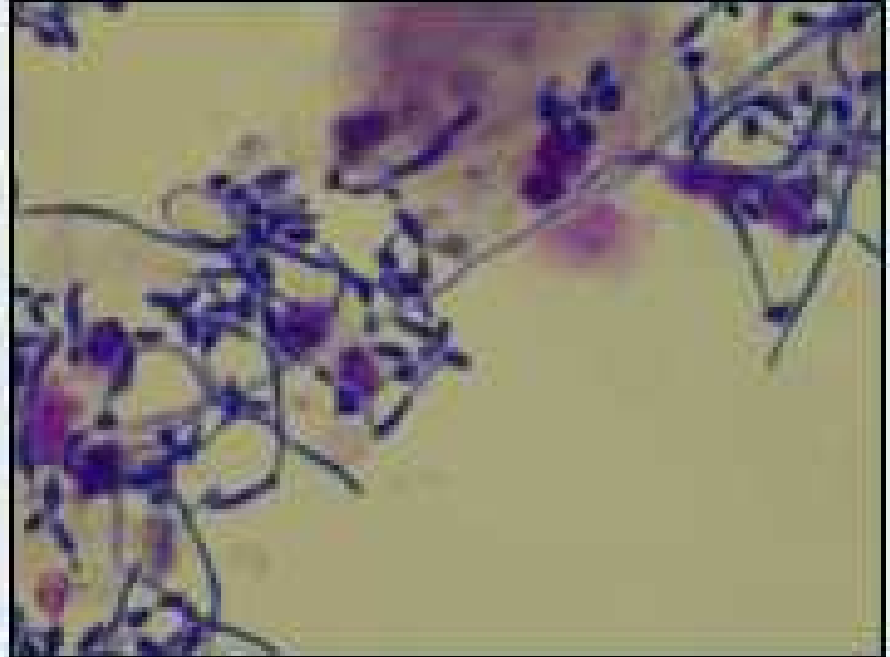
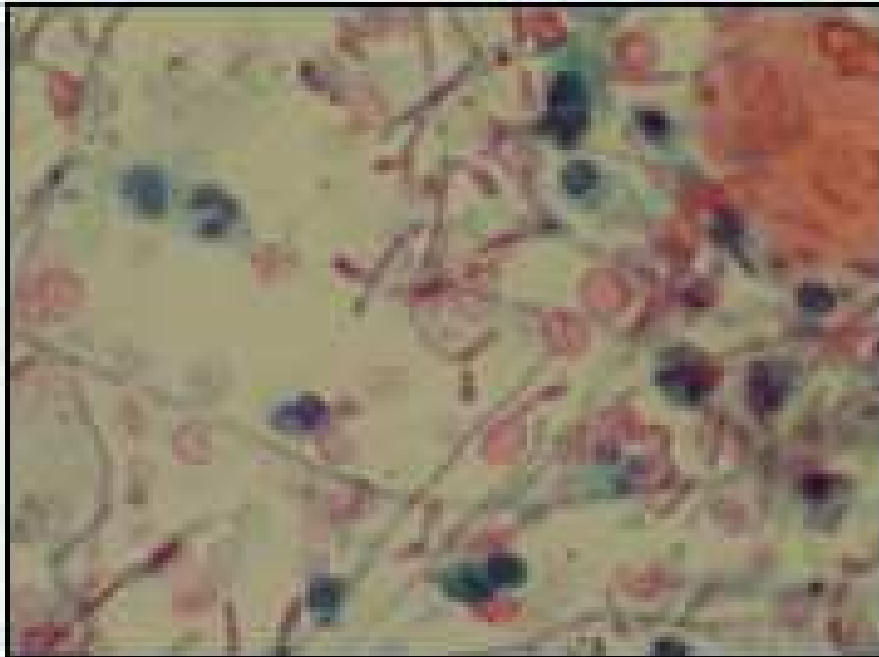


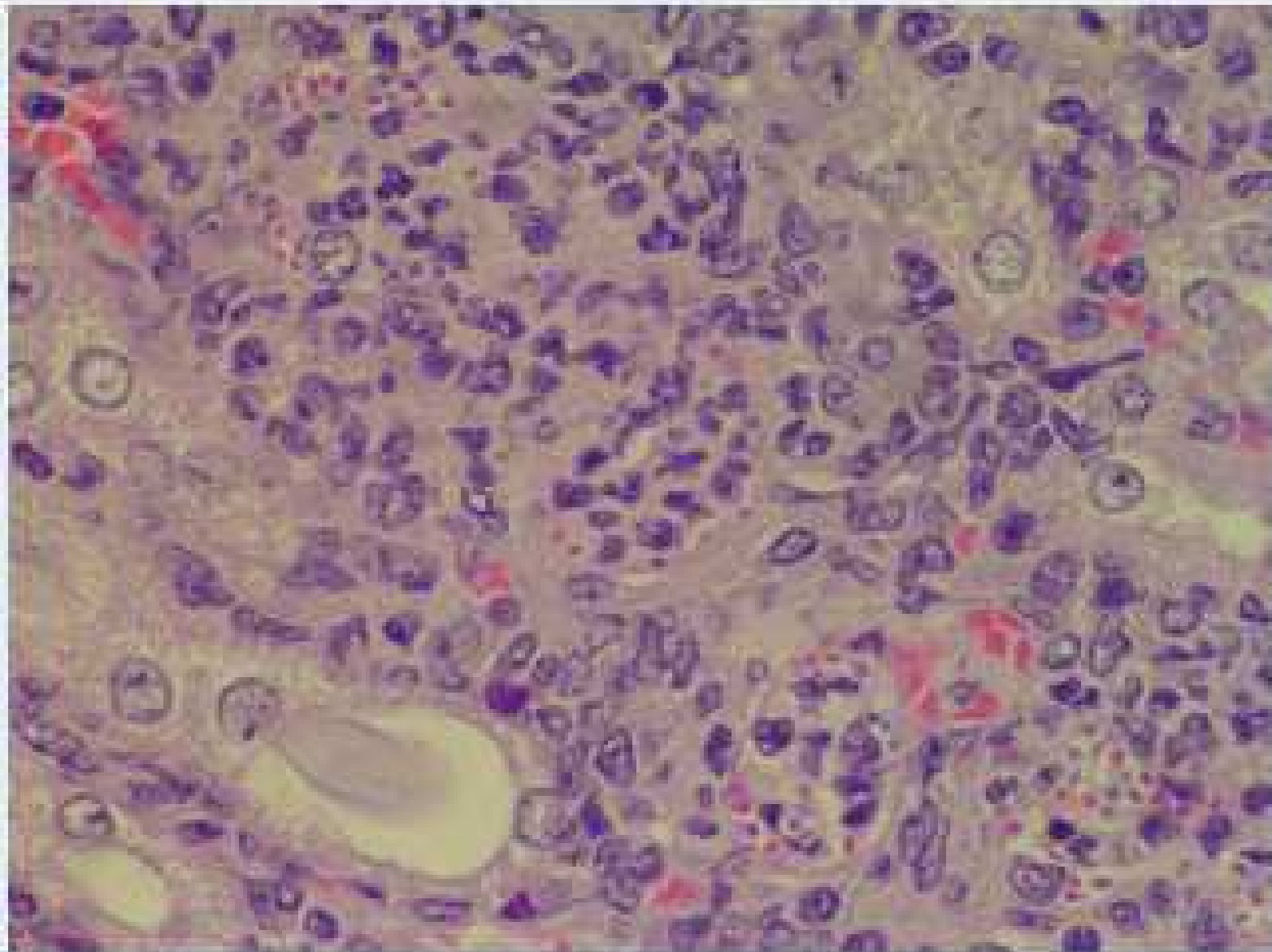


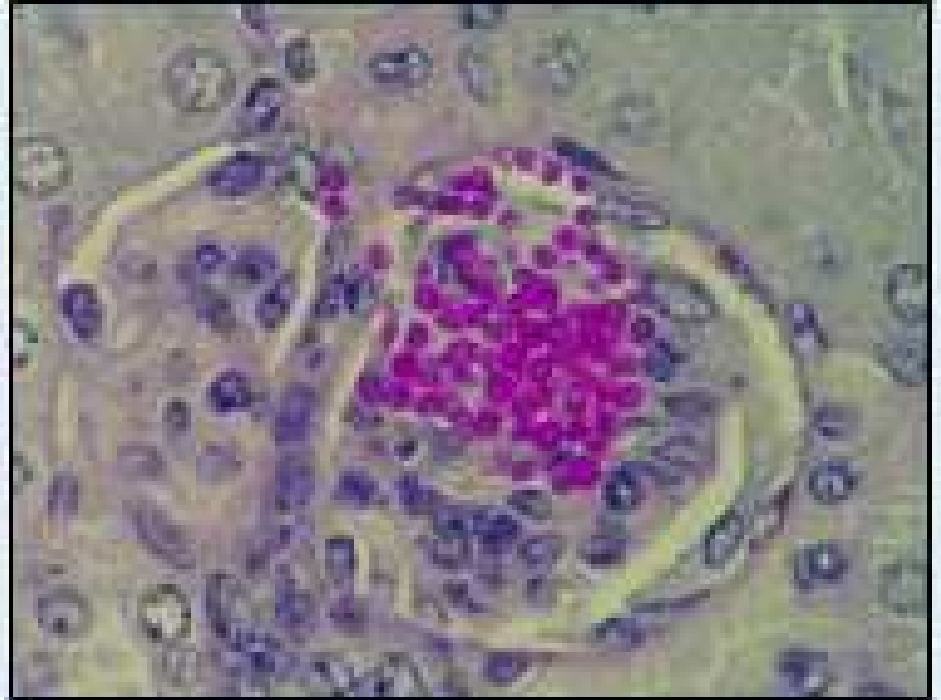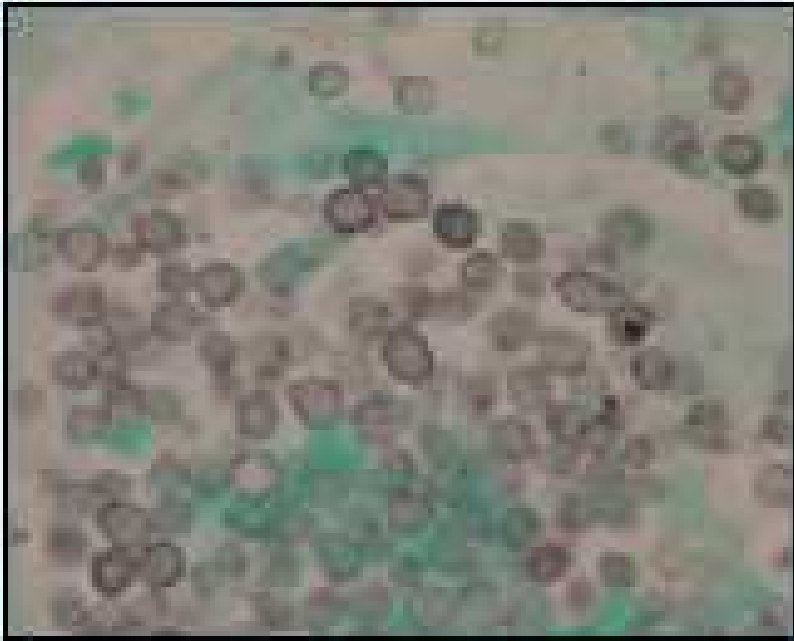
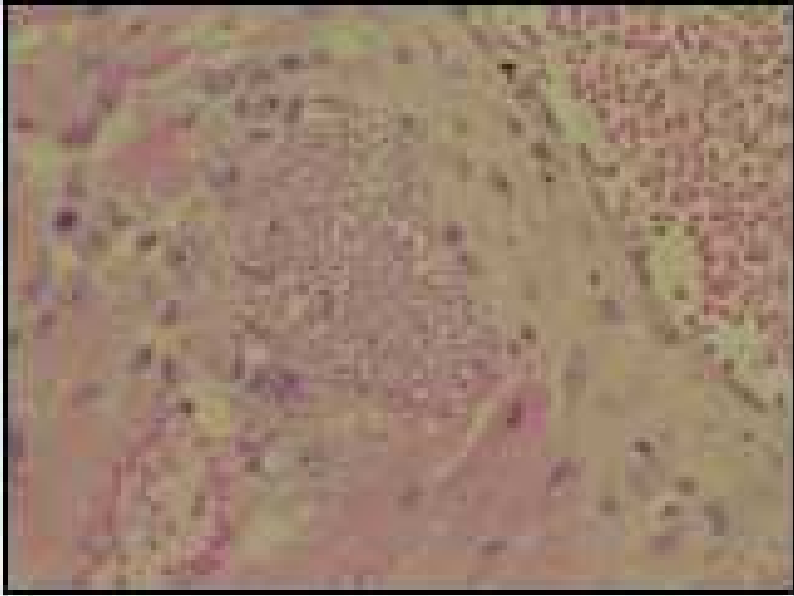






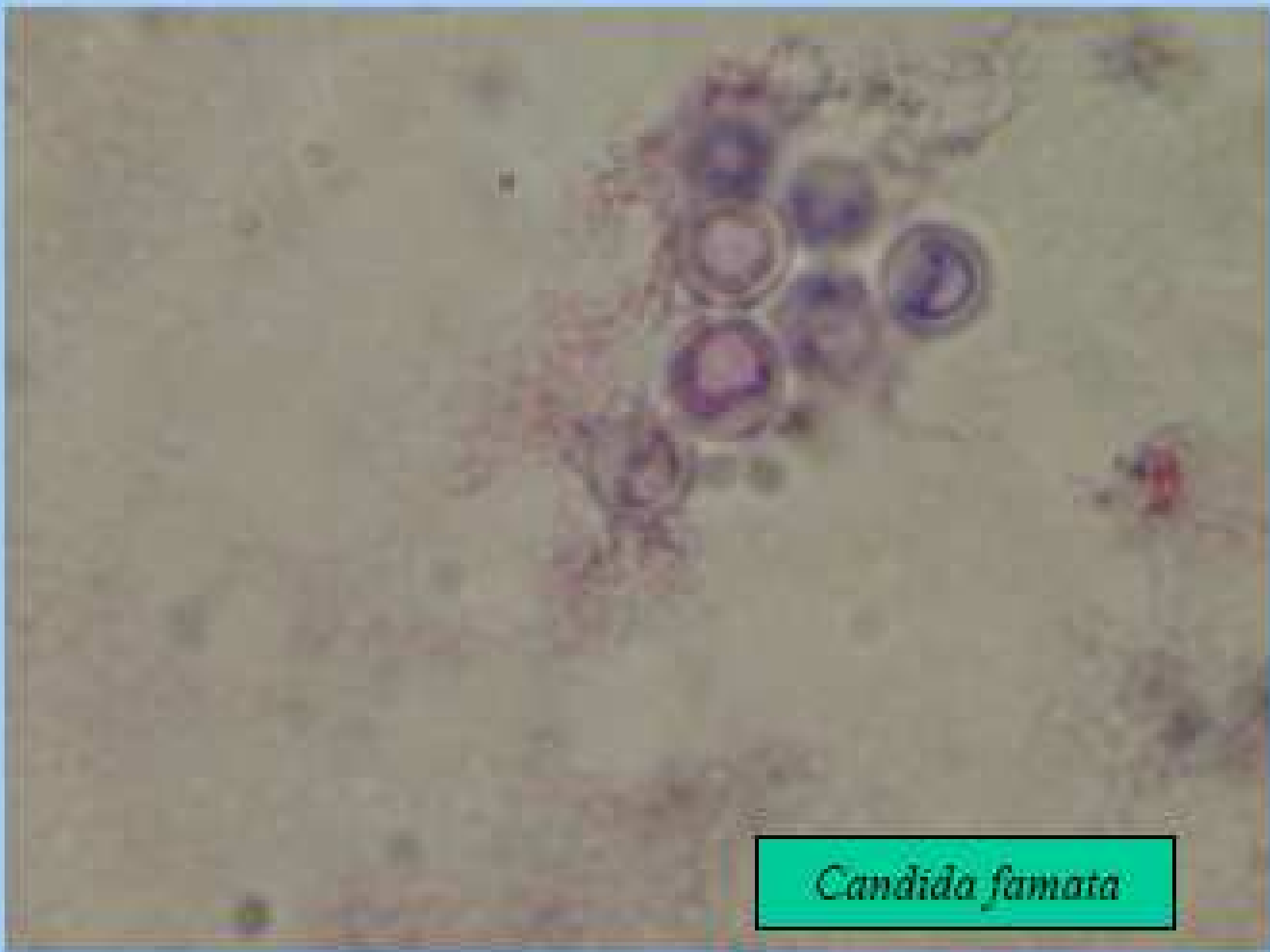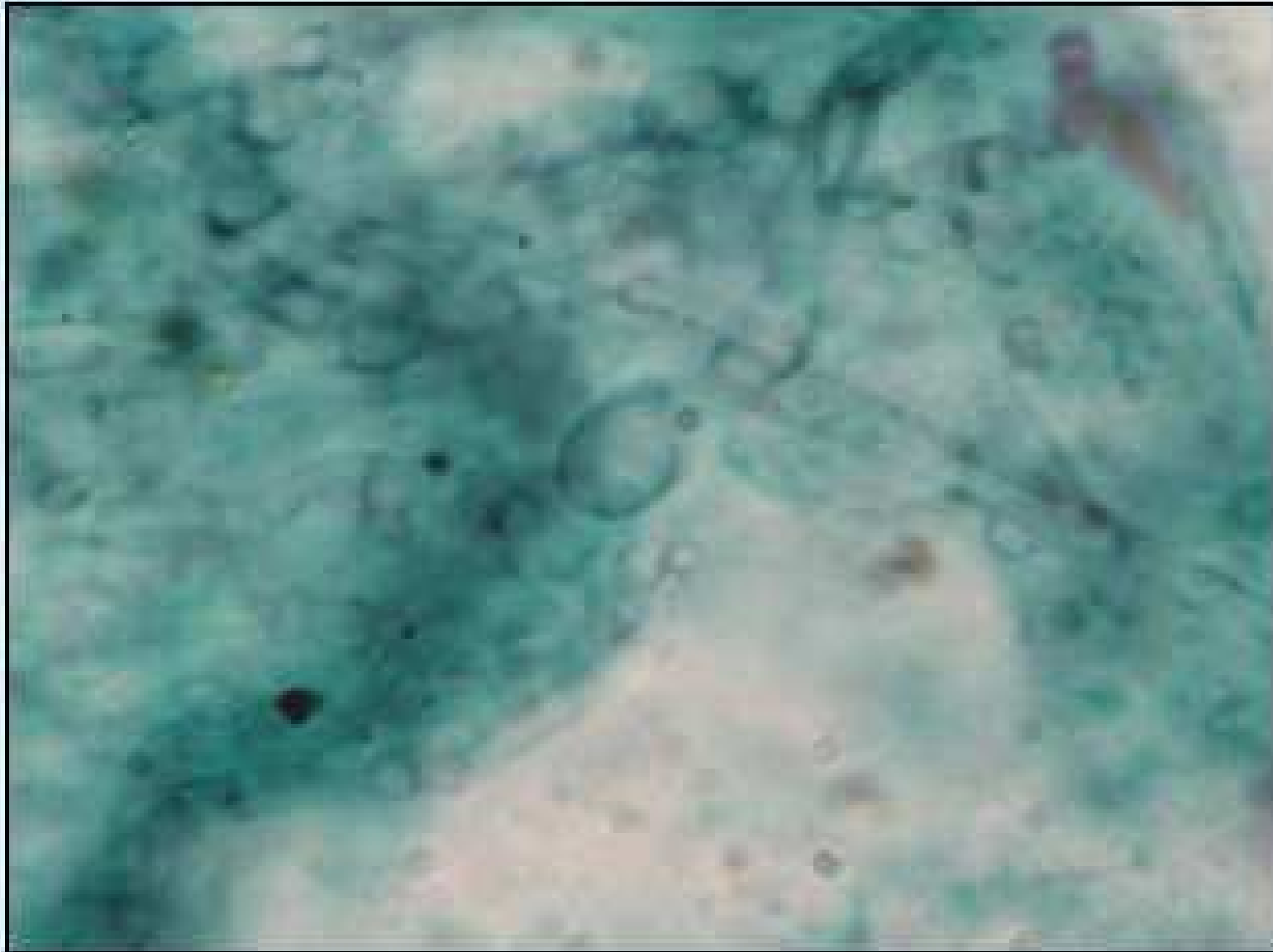


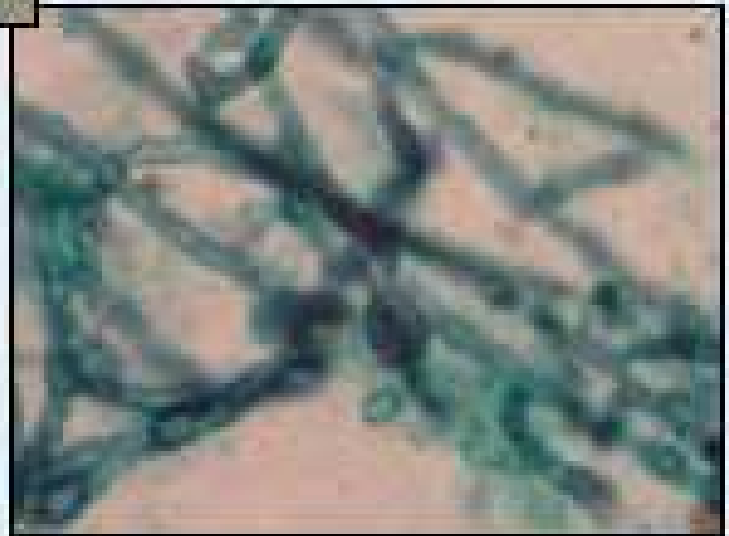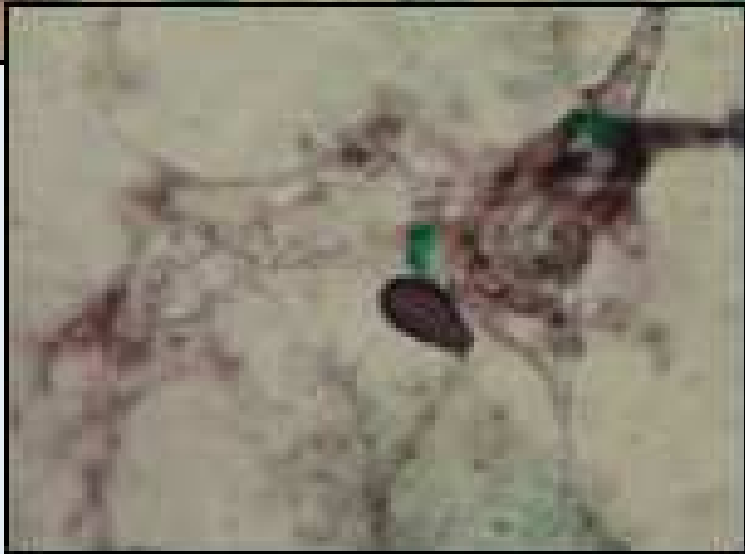
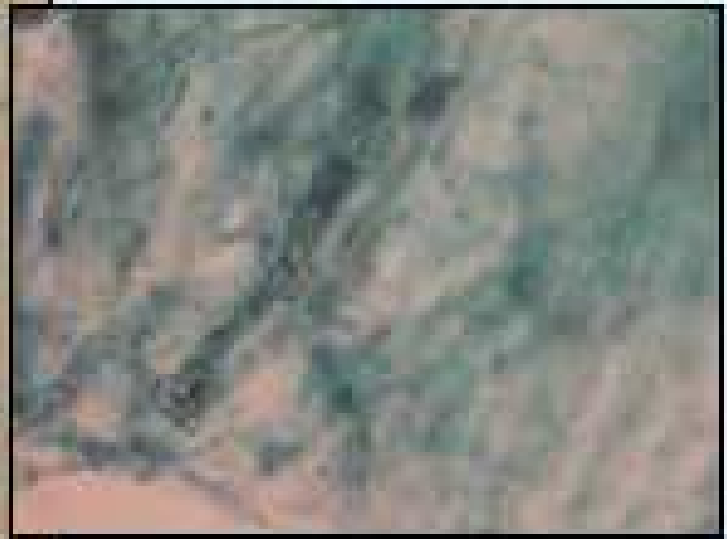
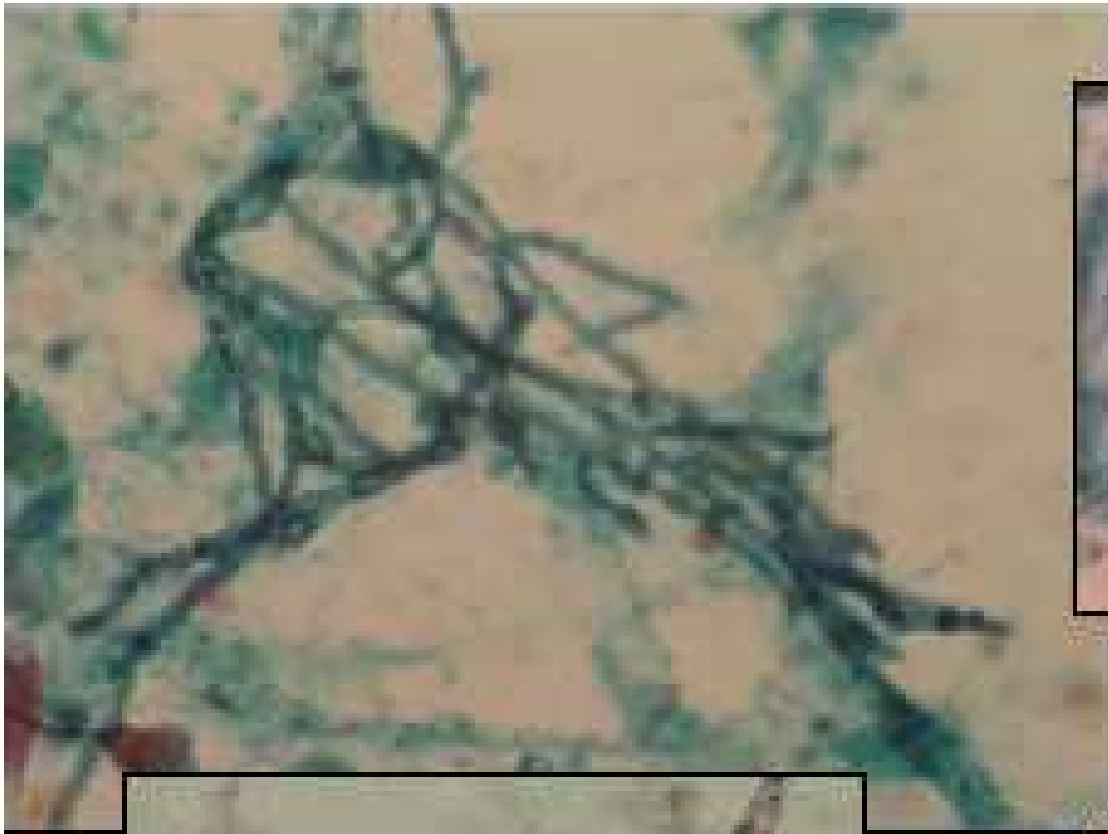




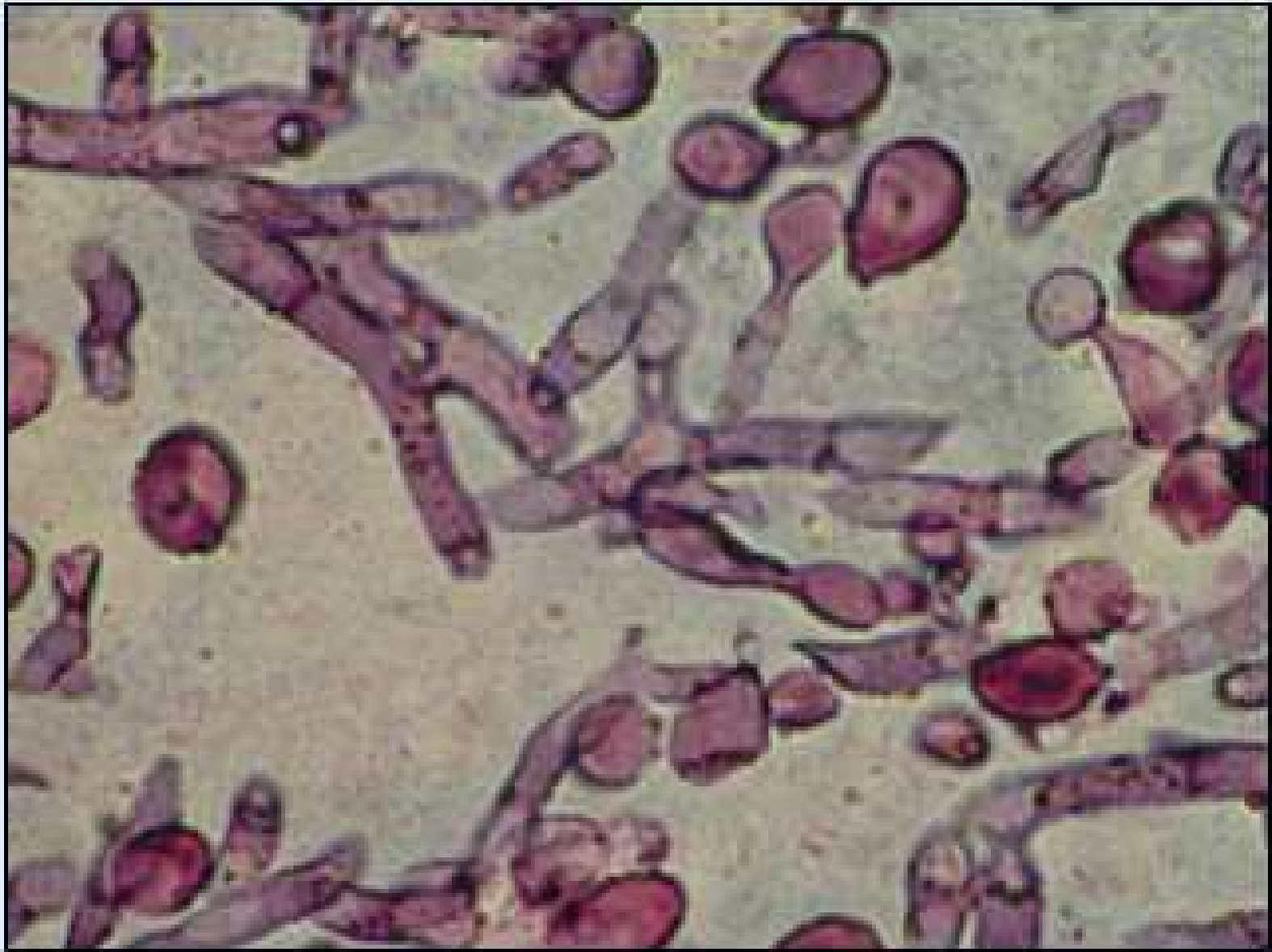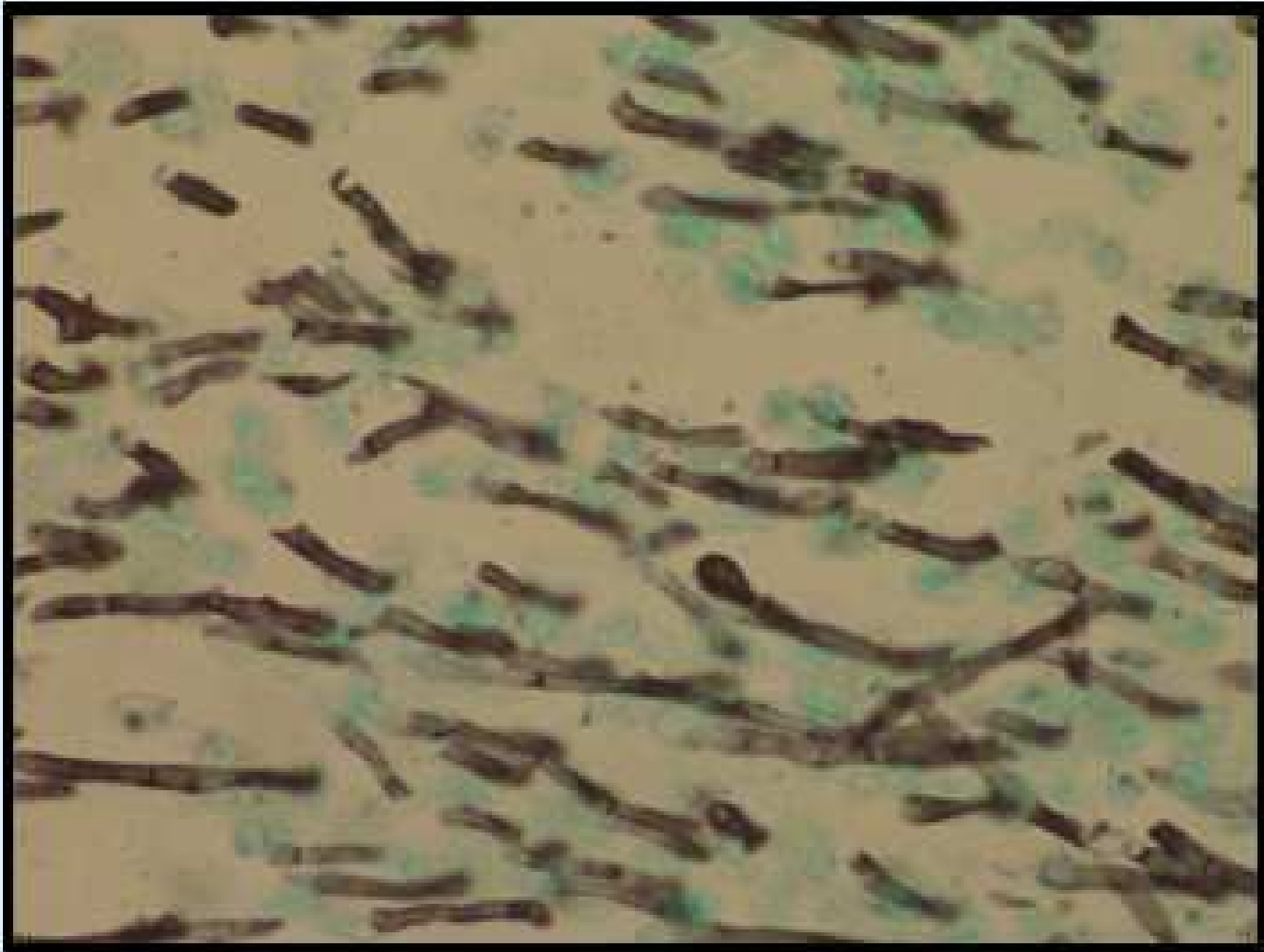


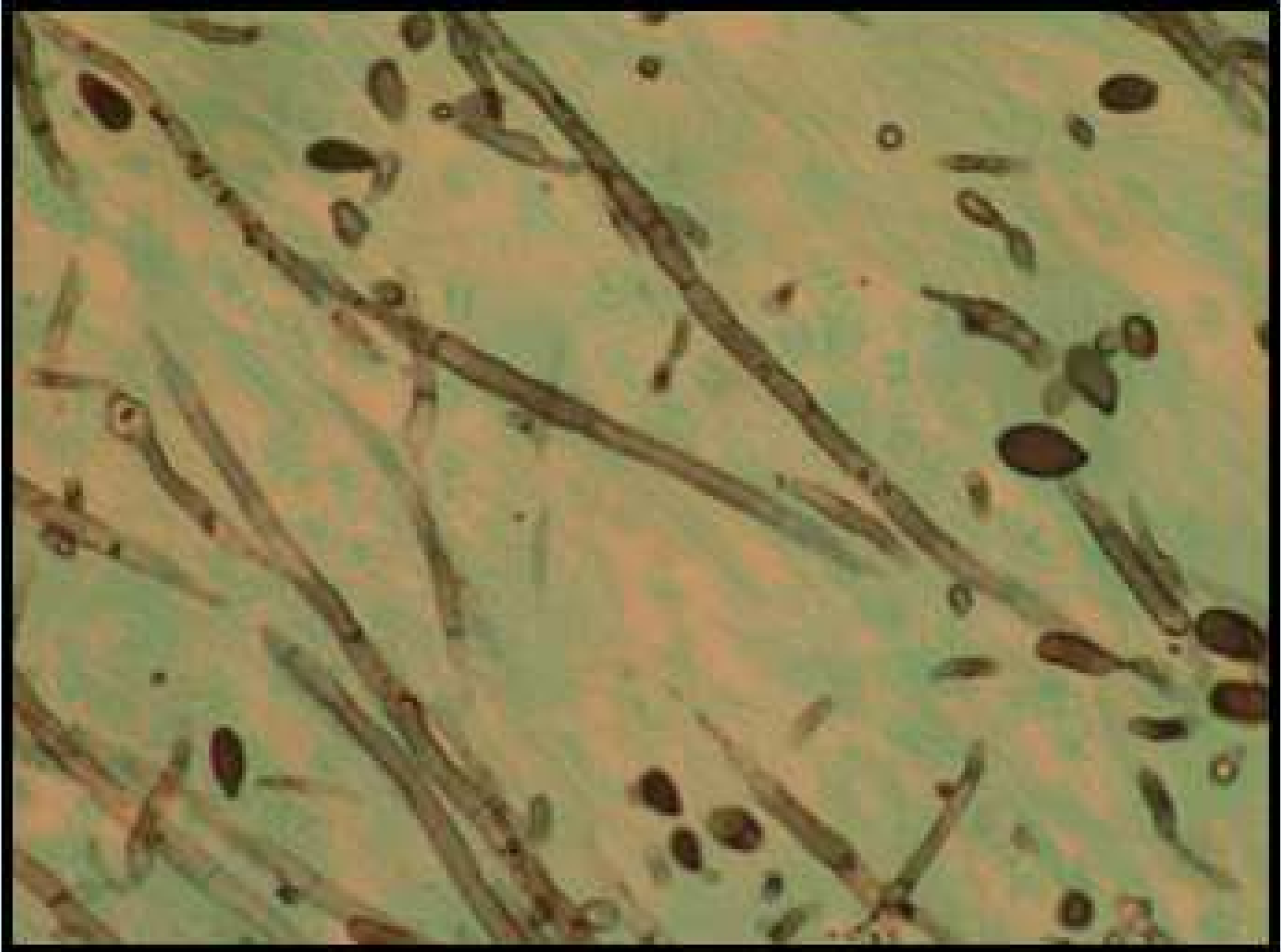
*Candida famata*

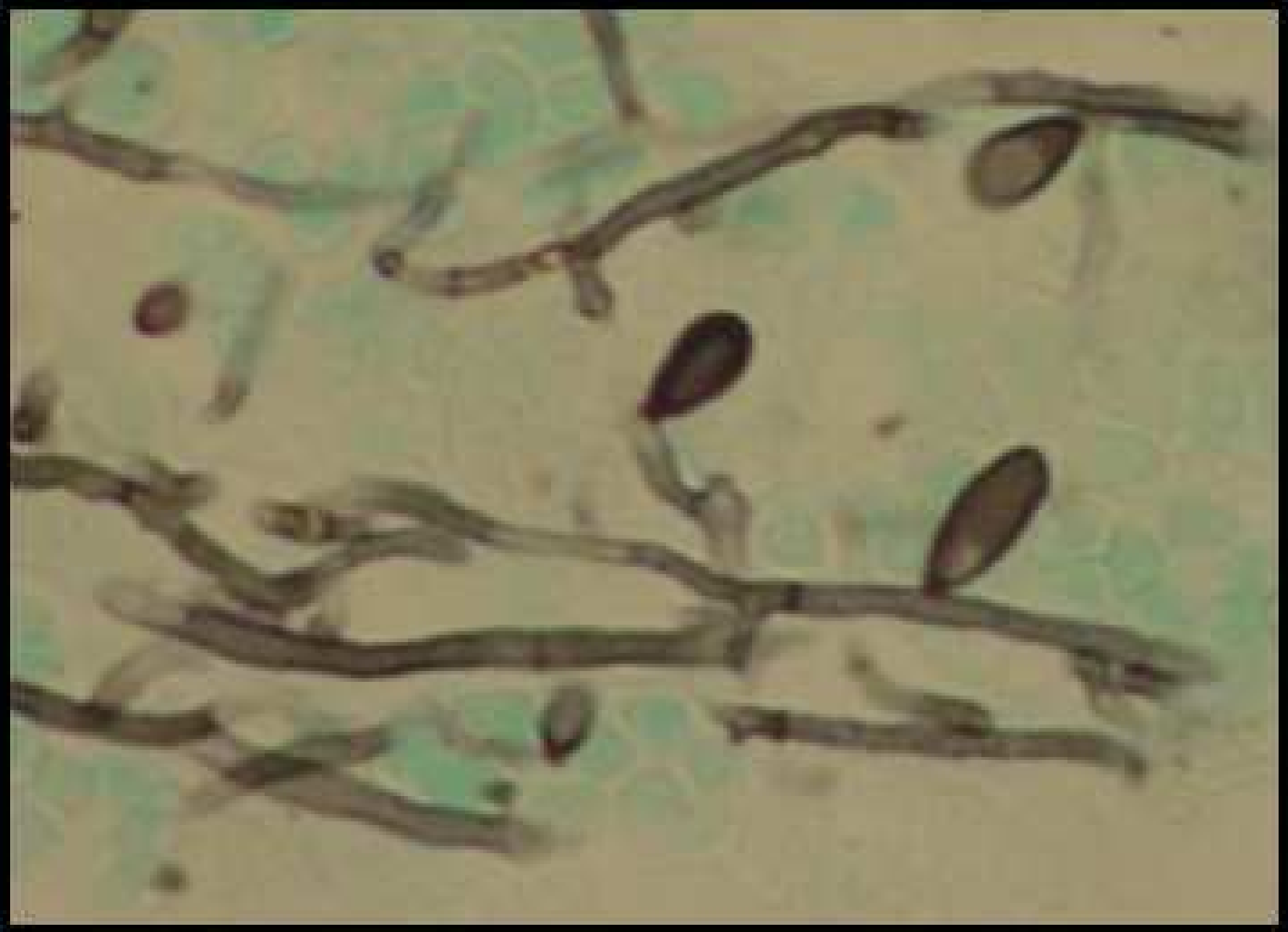

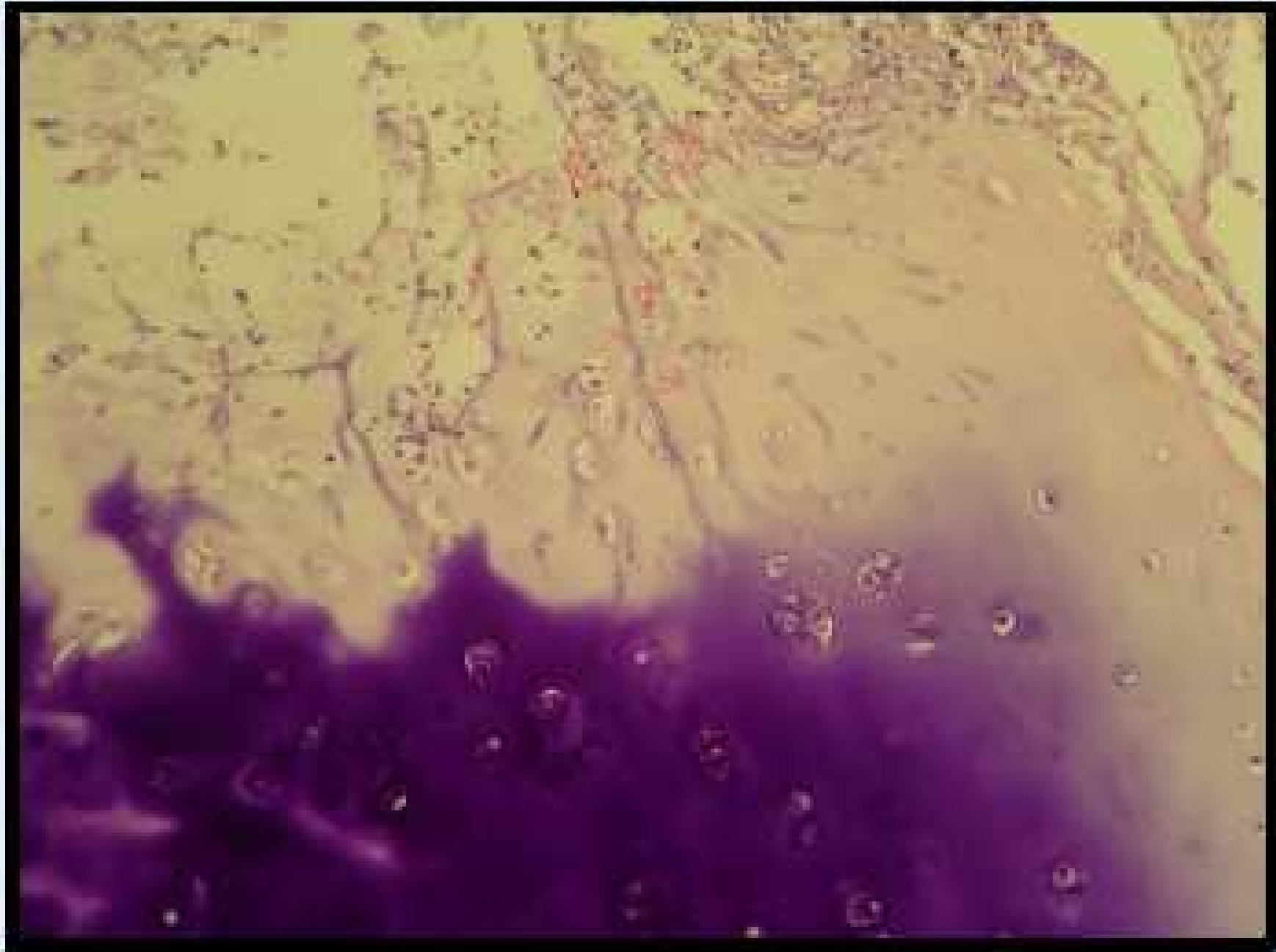


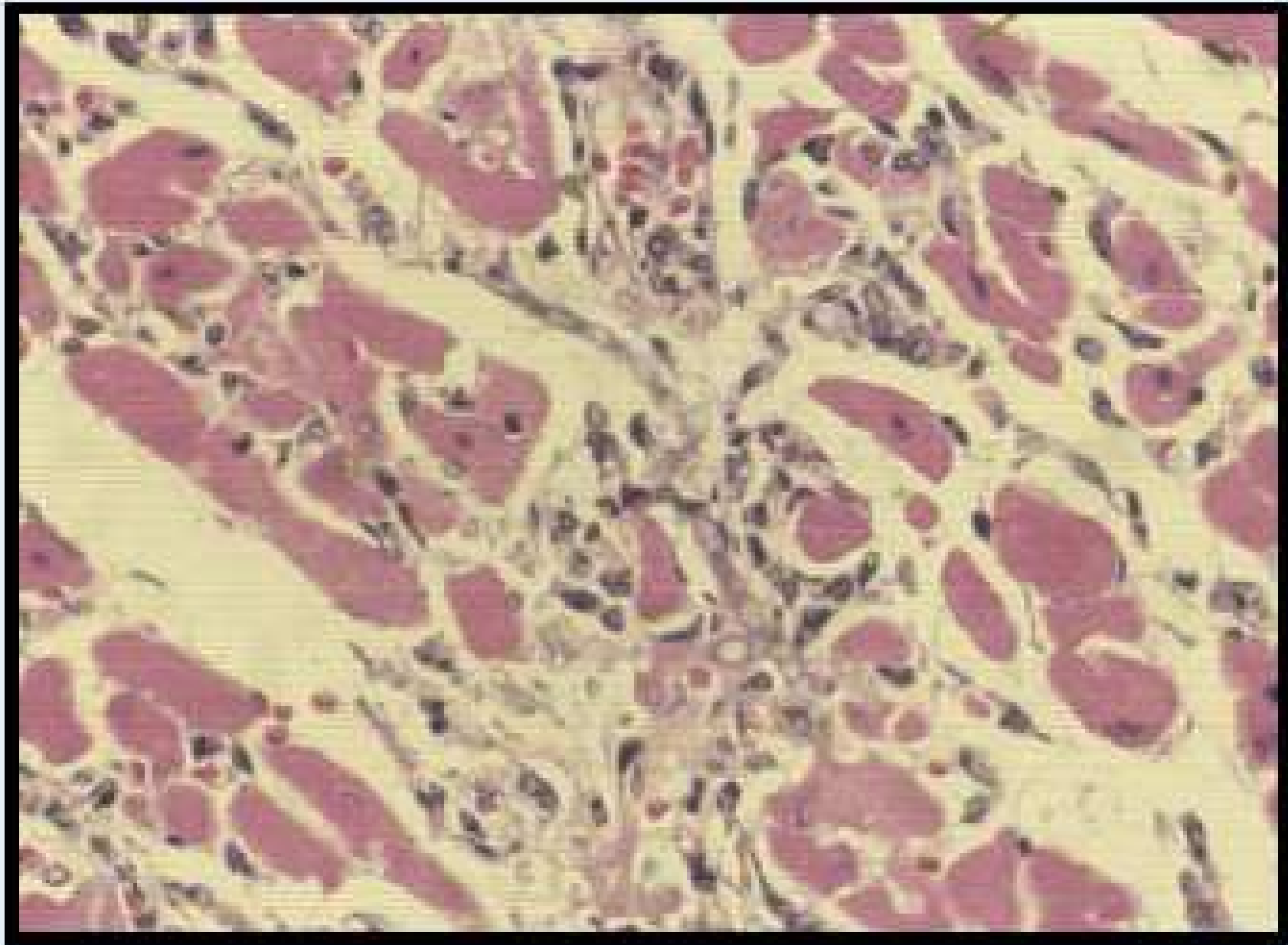


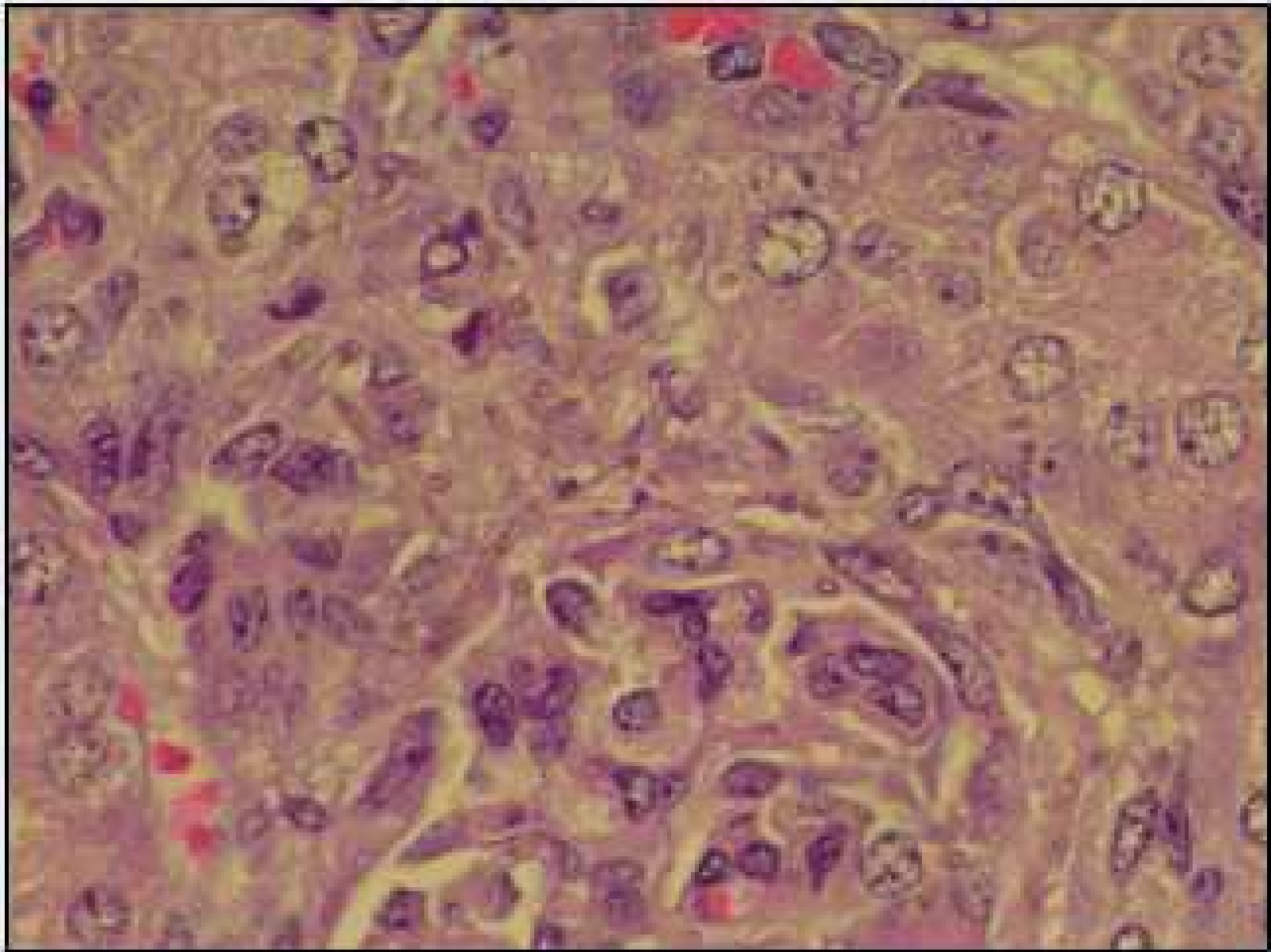


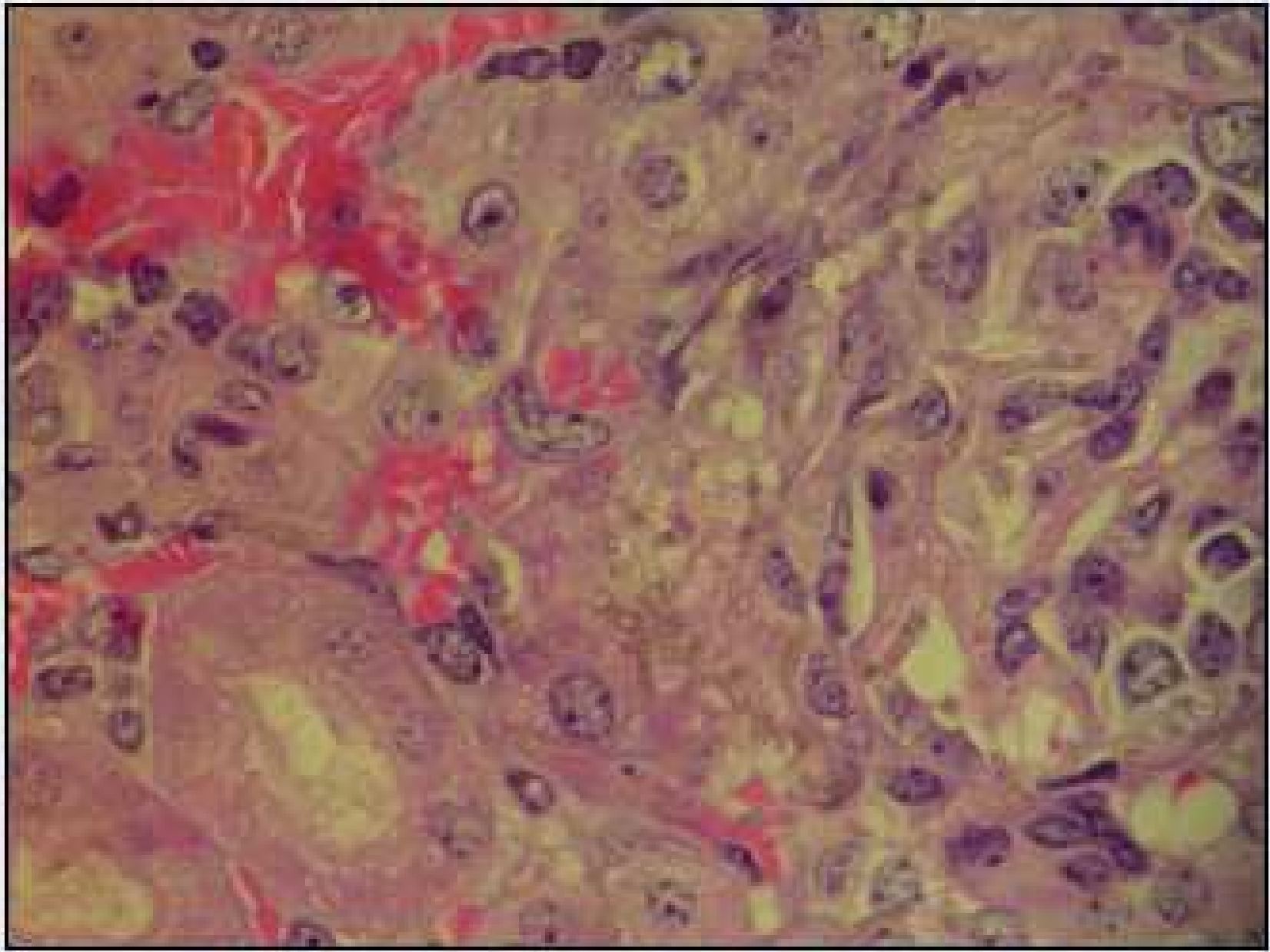


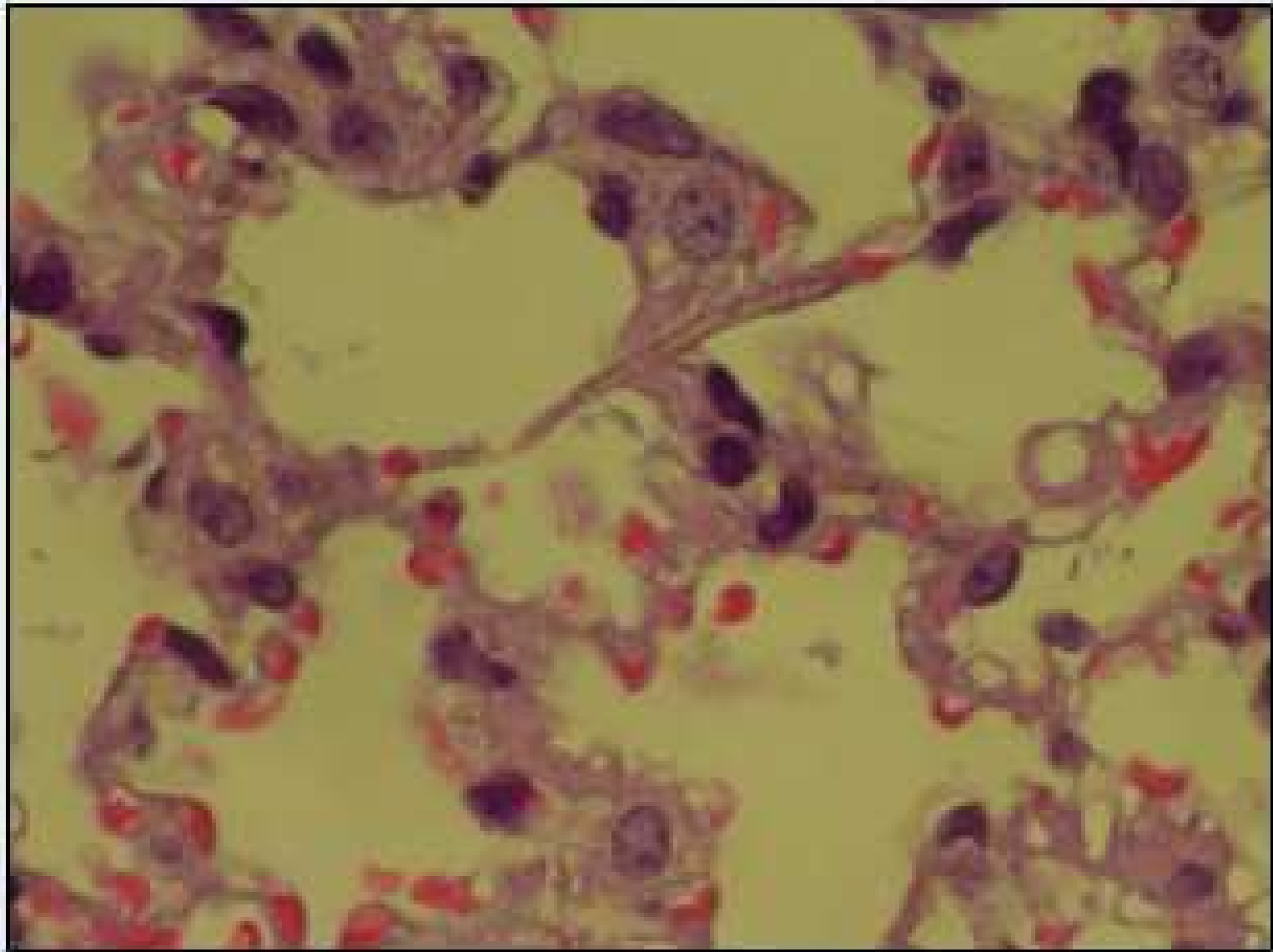


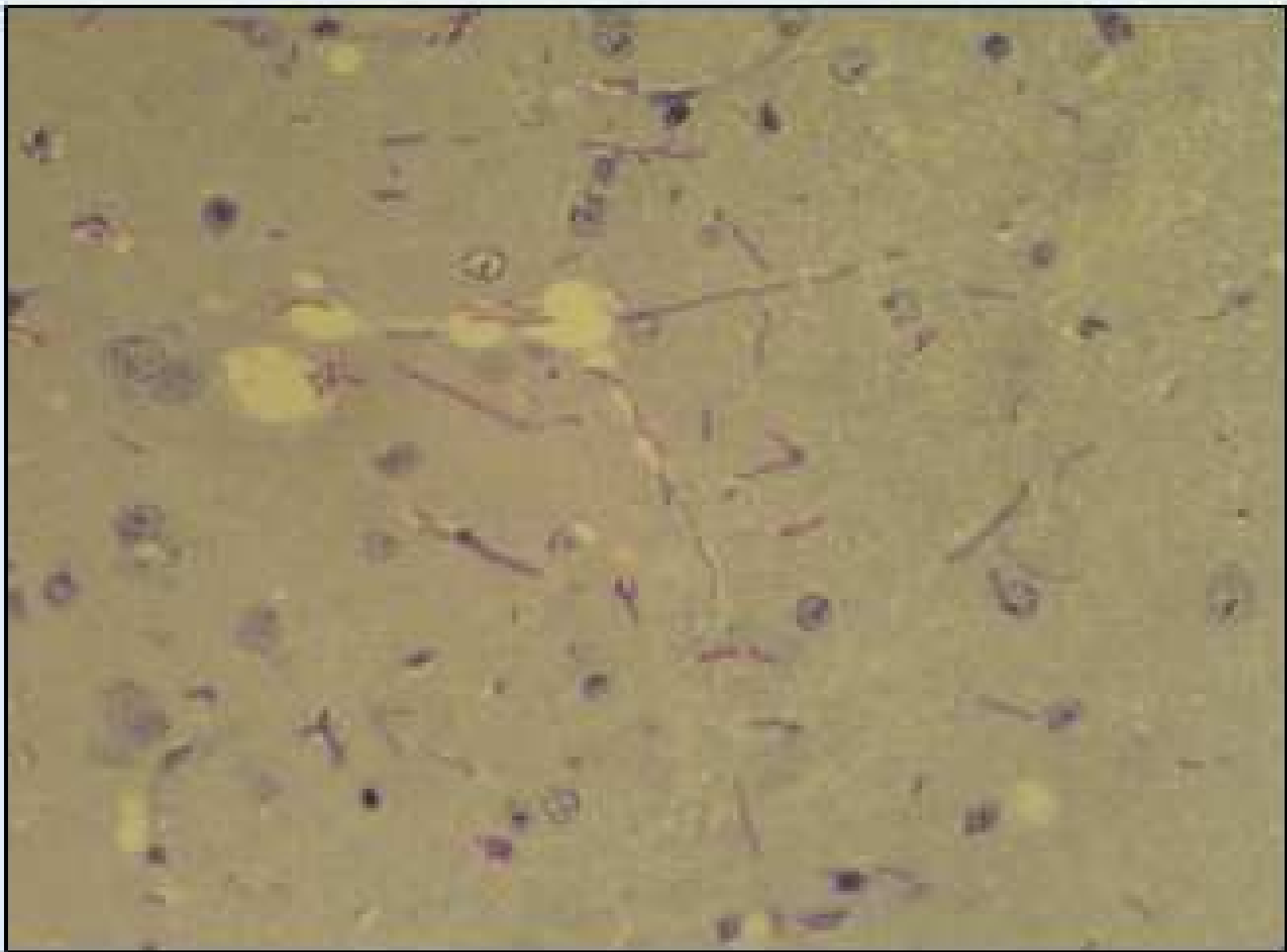


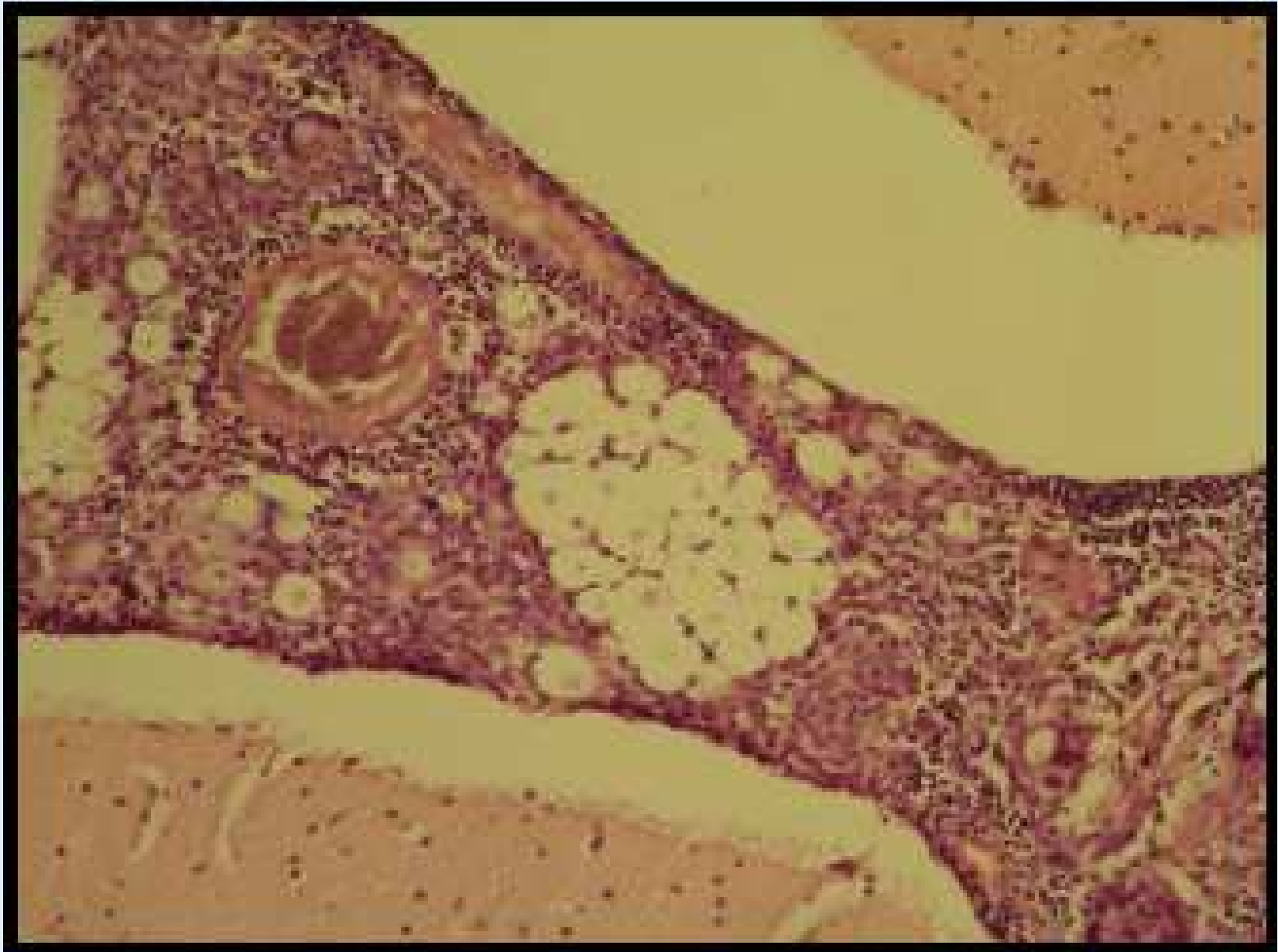


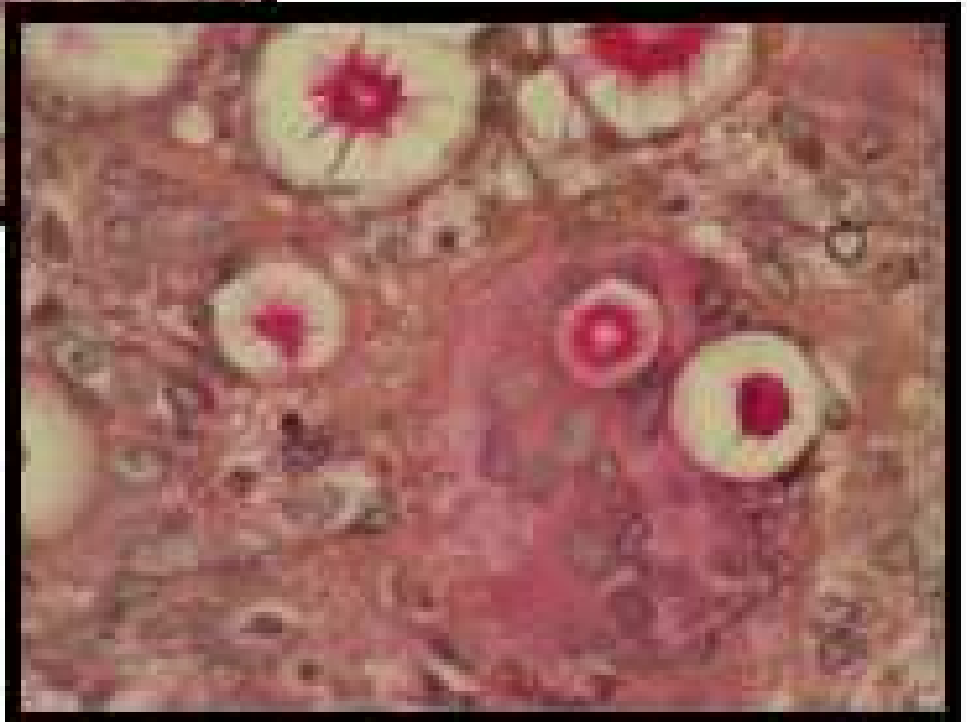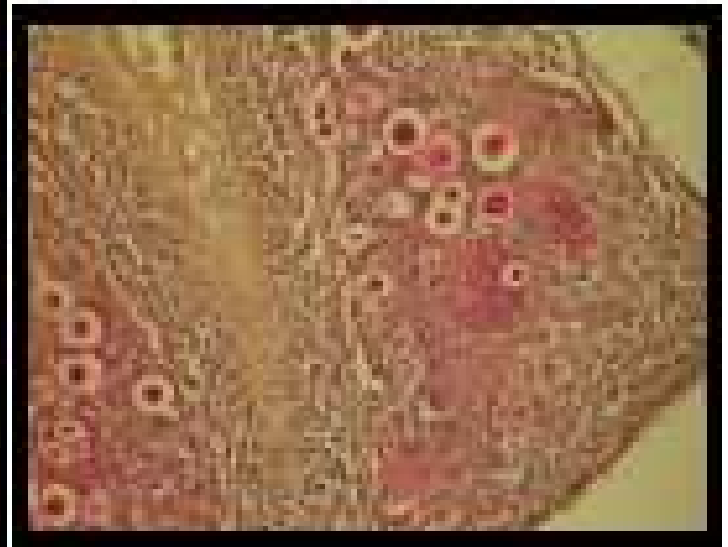
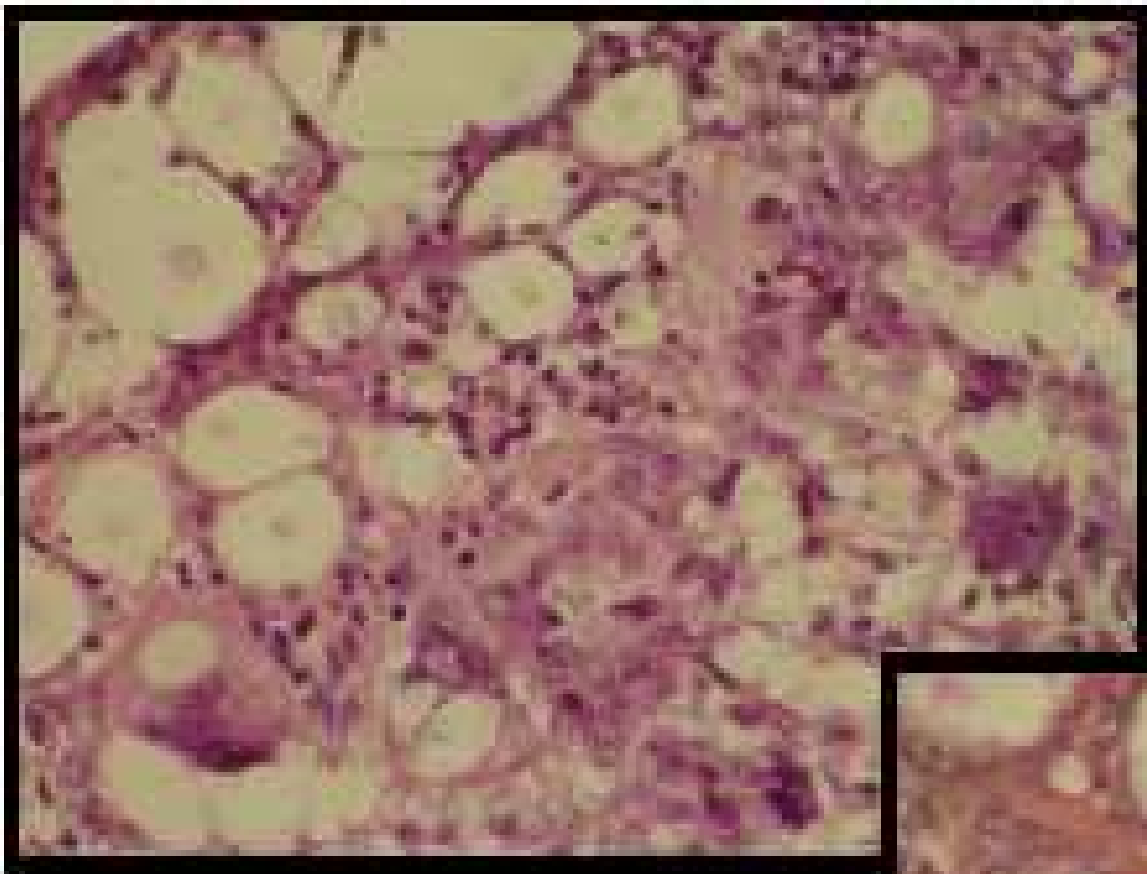


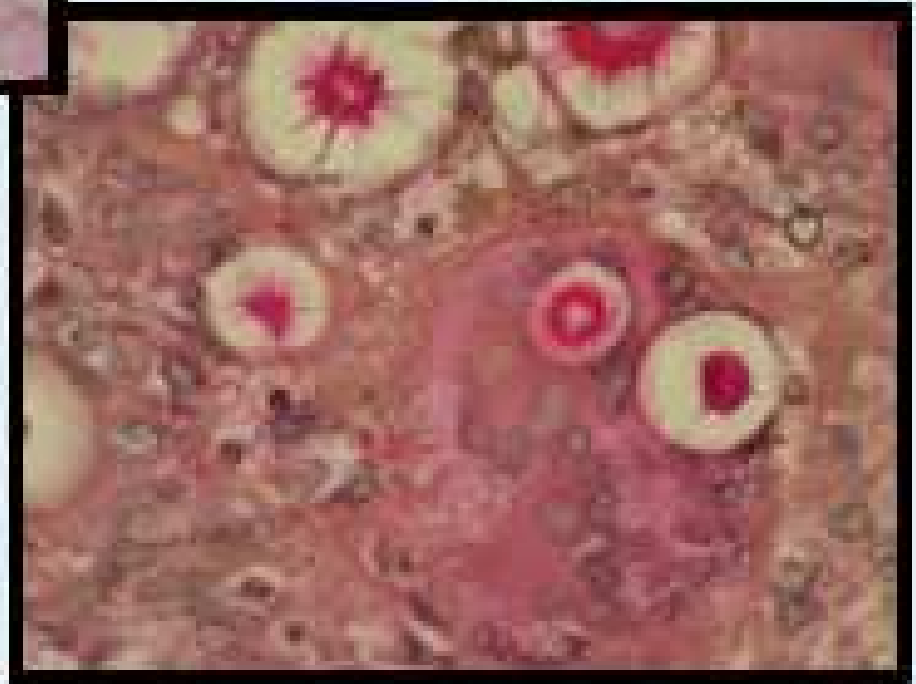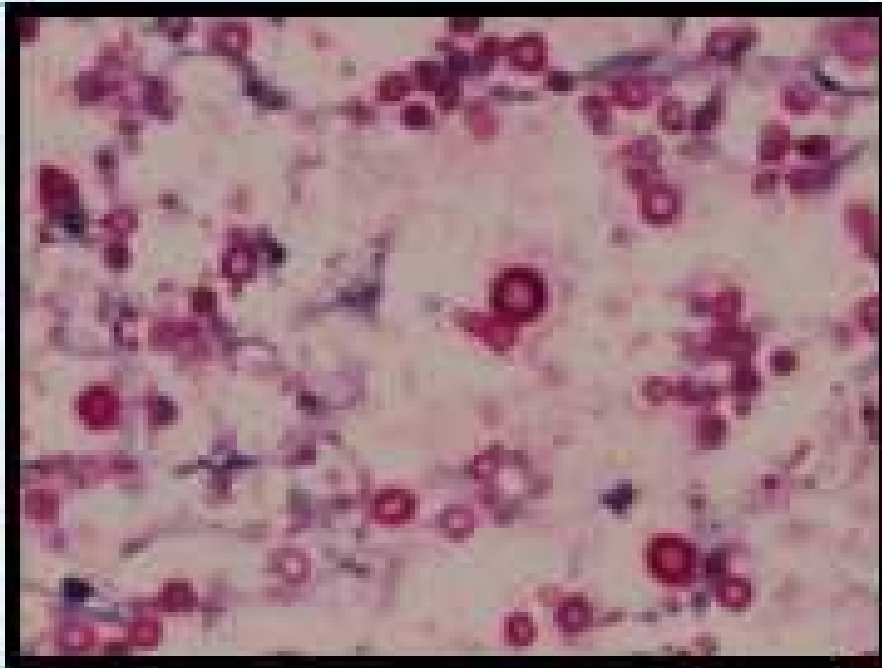


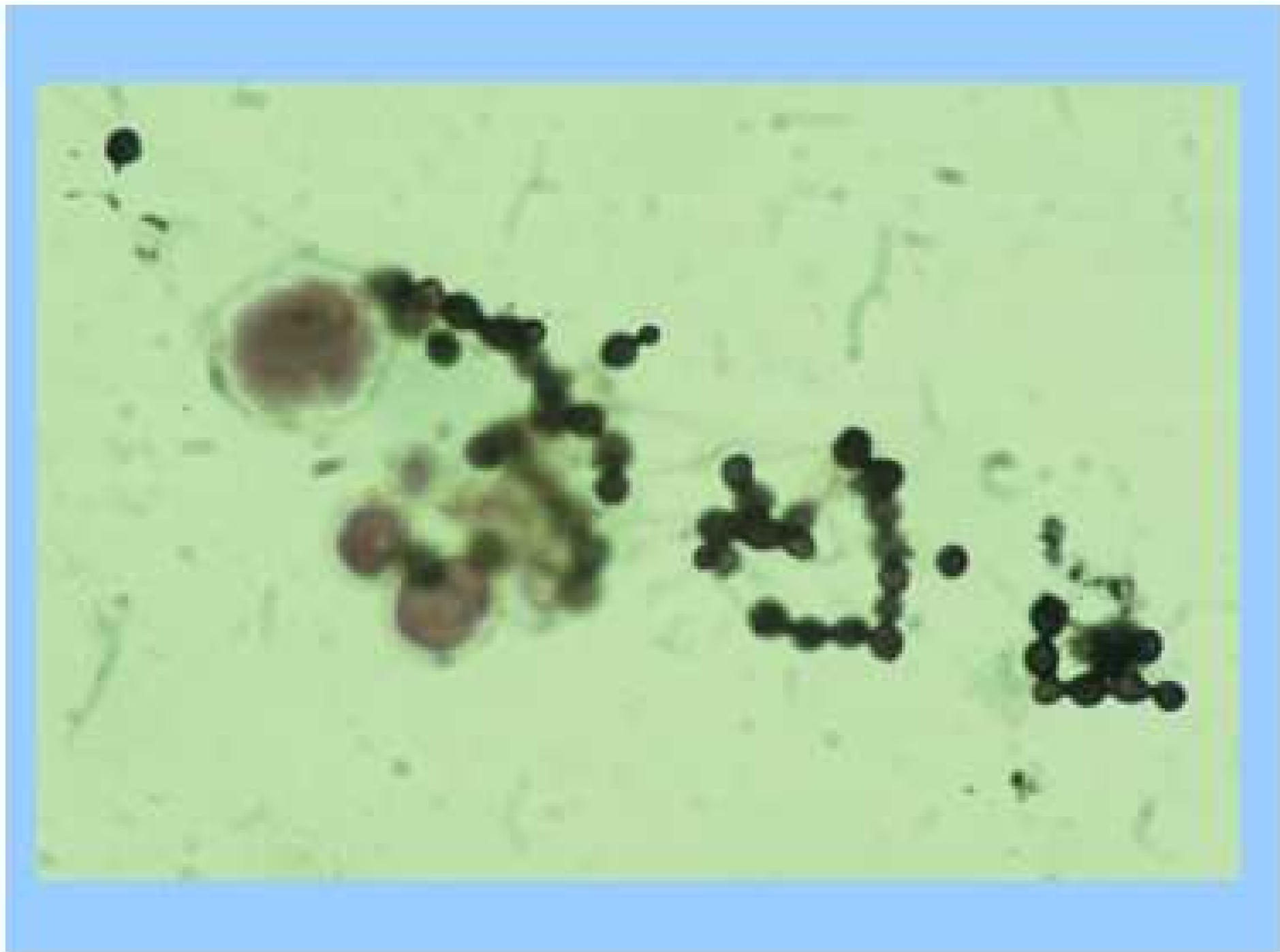


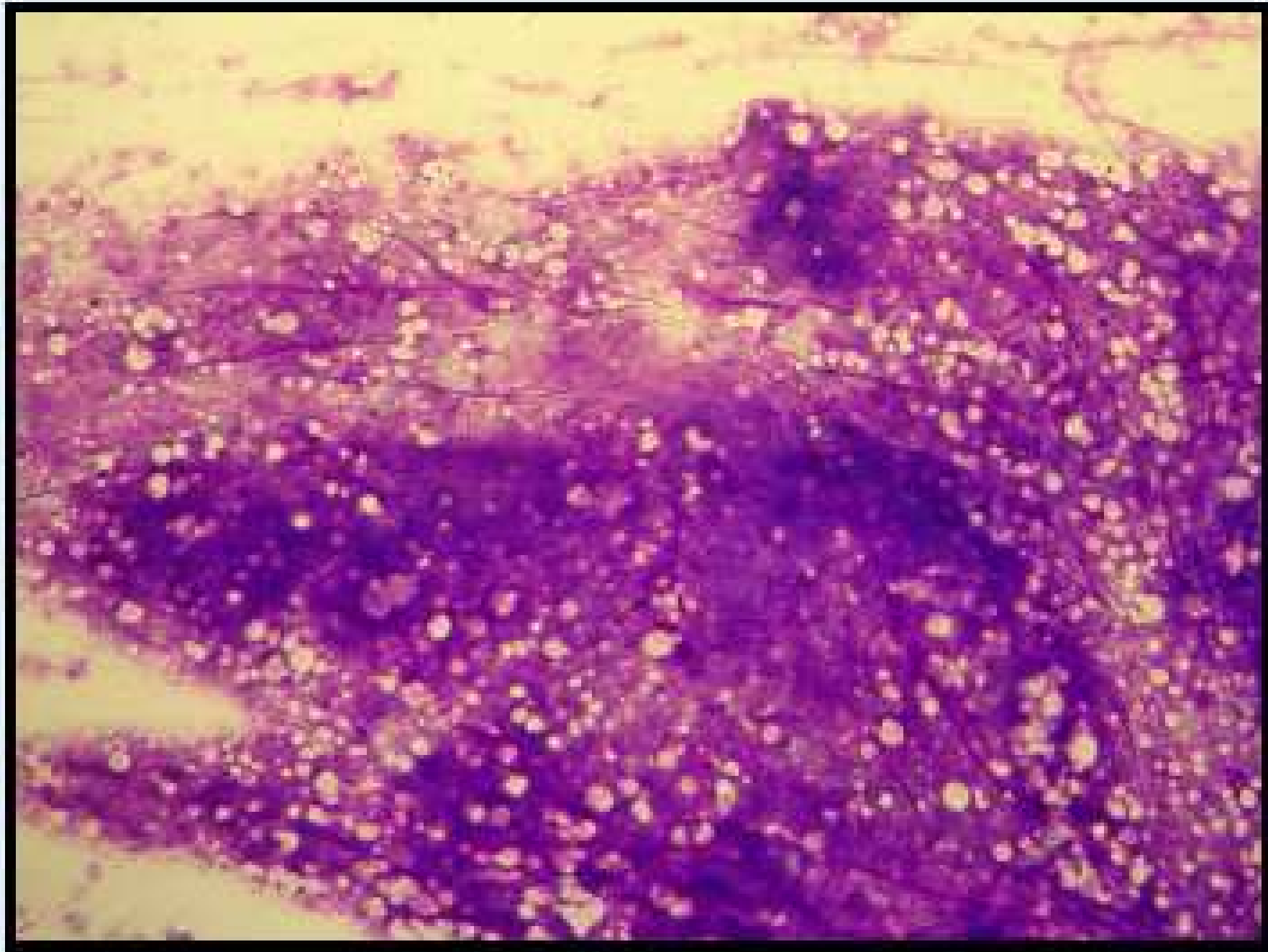


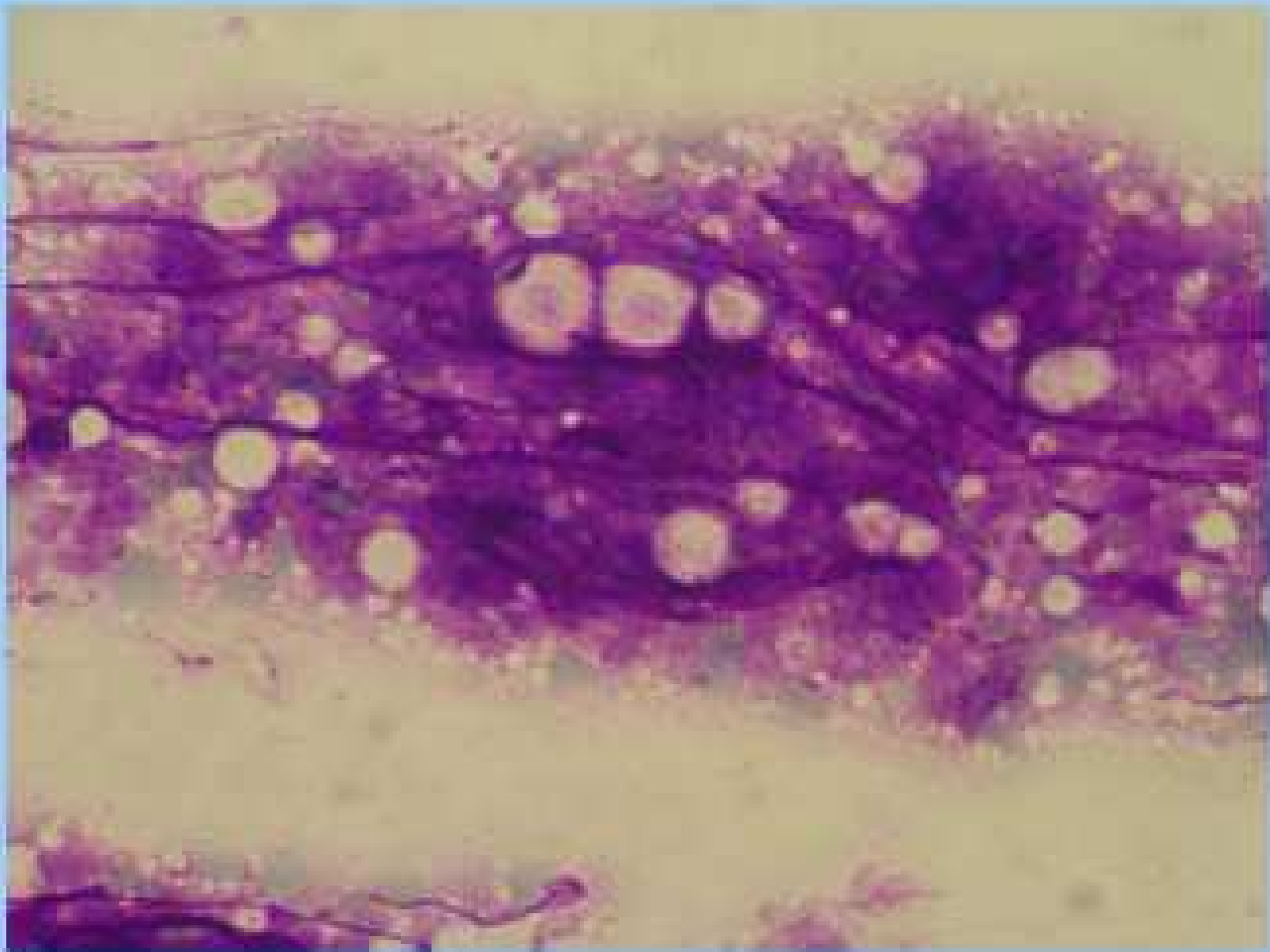


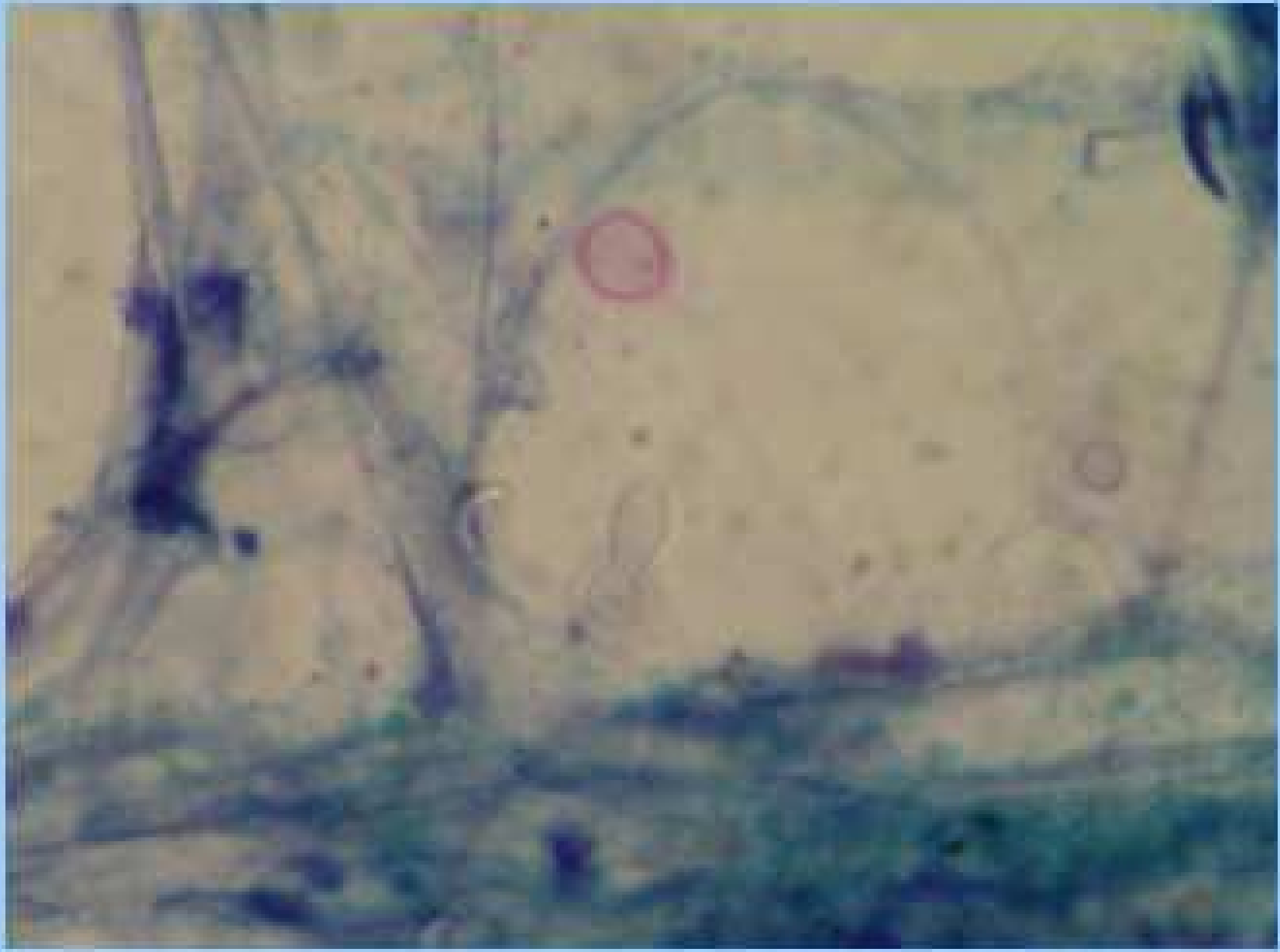


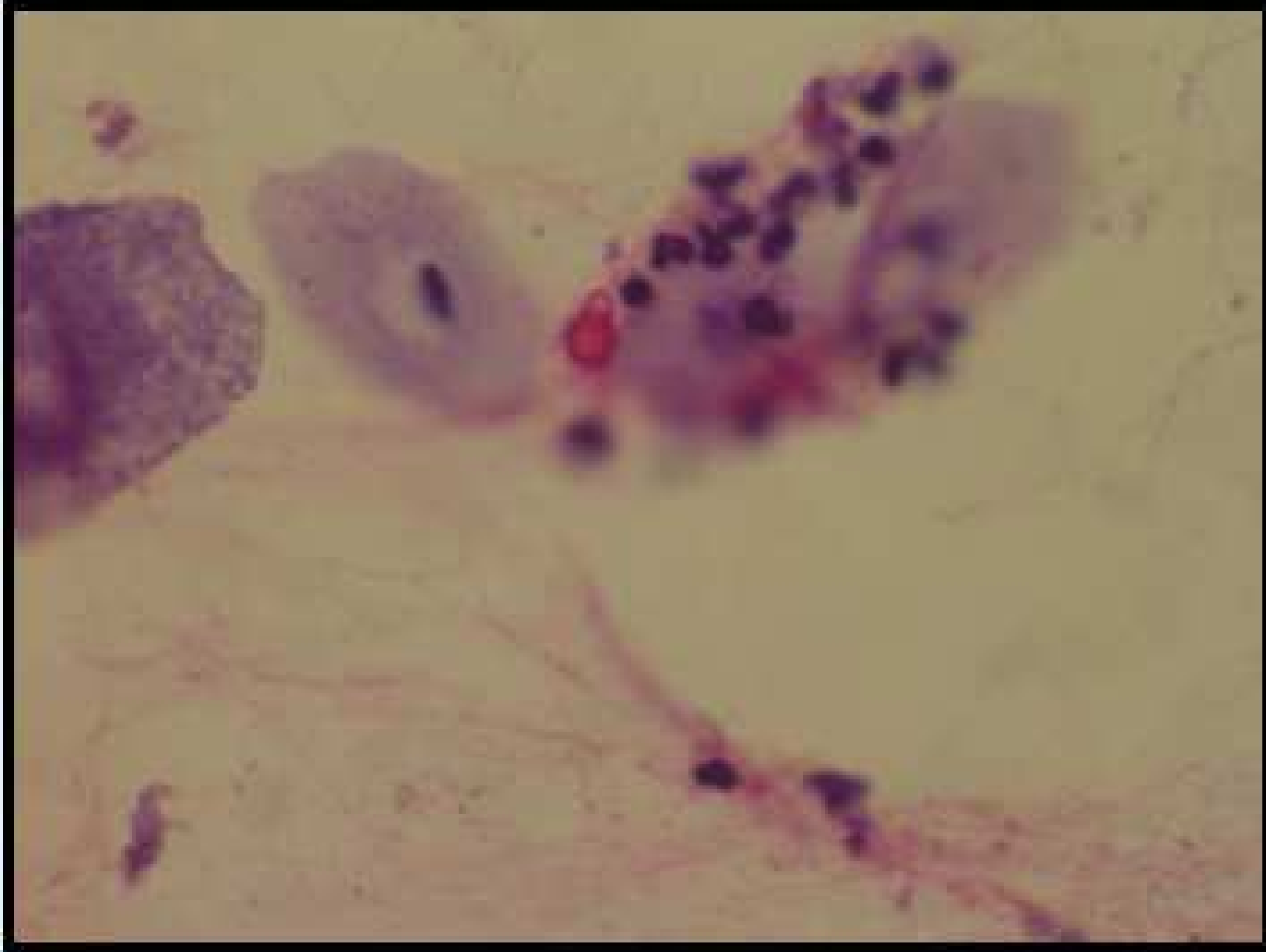


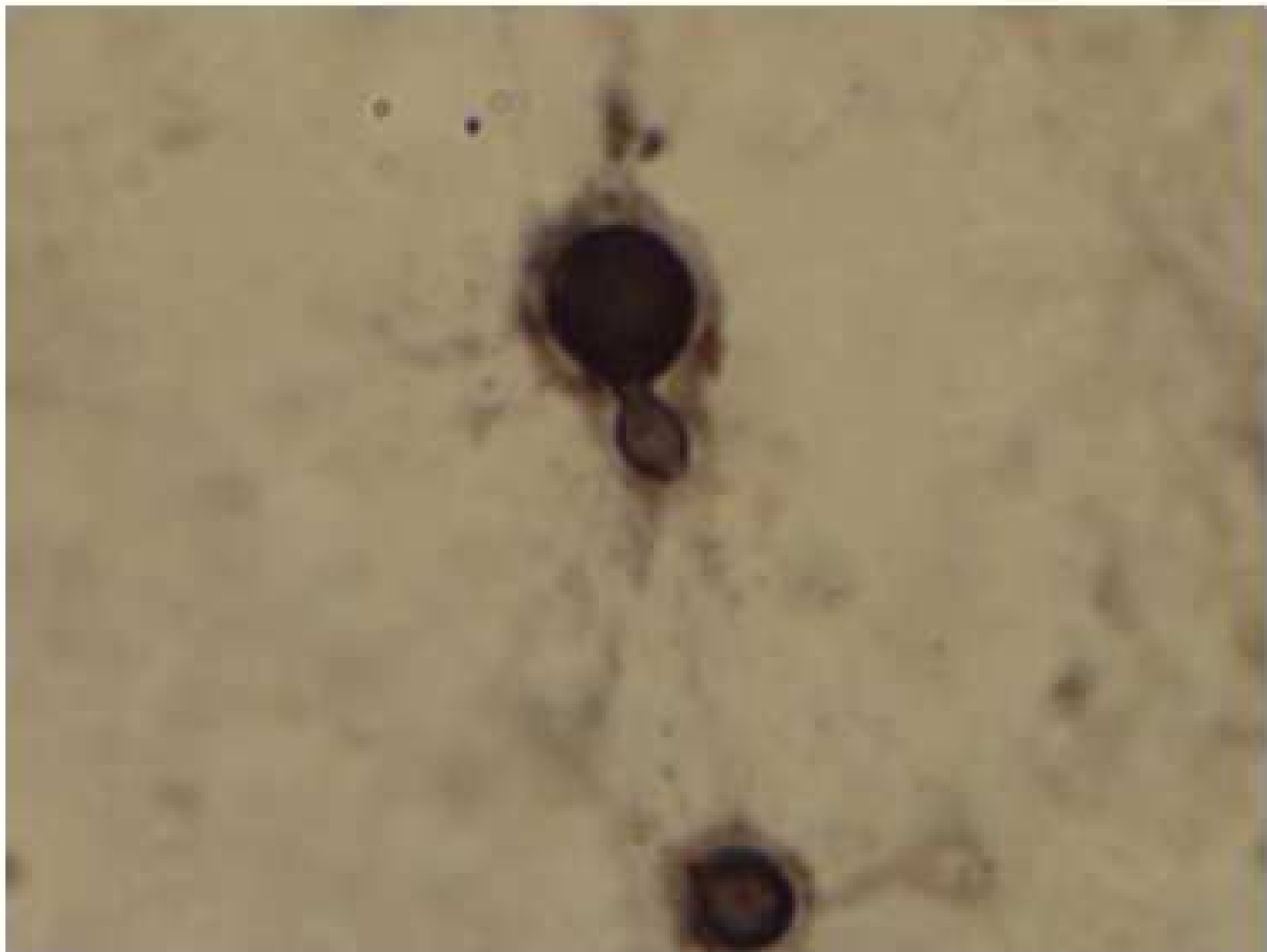


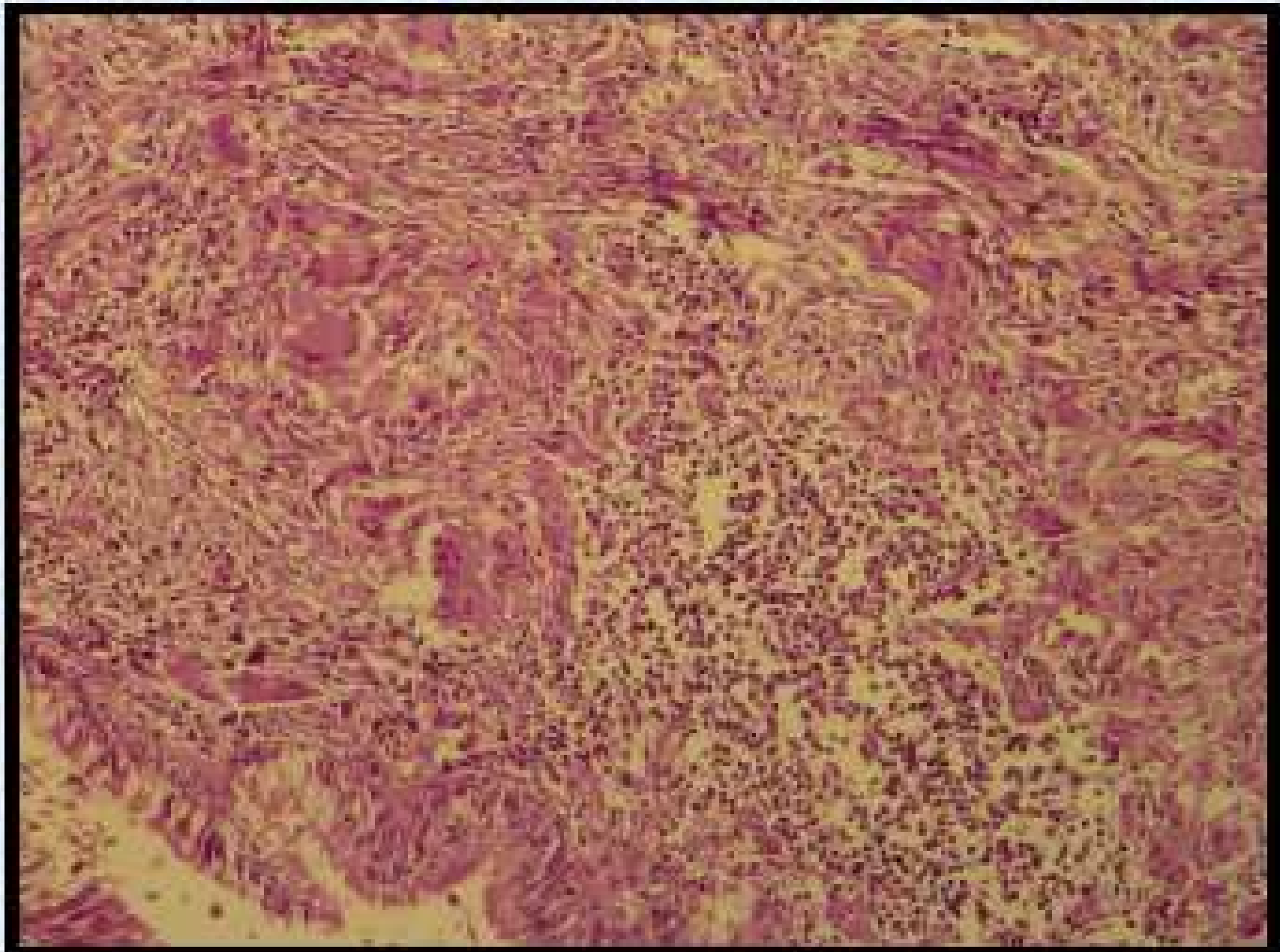


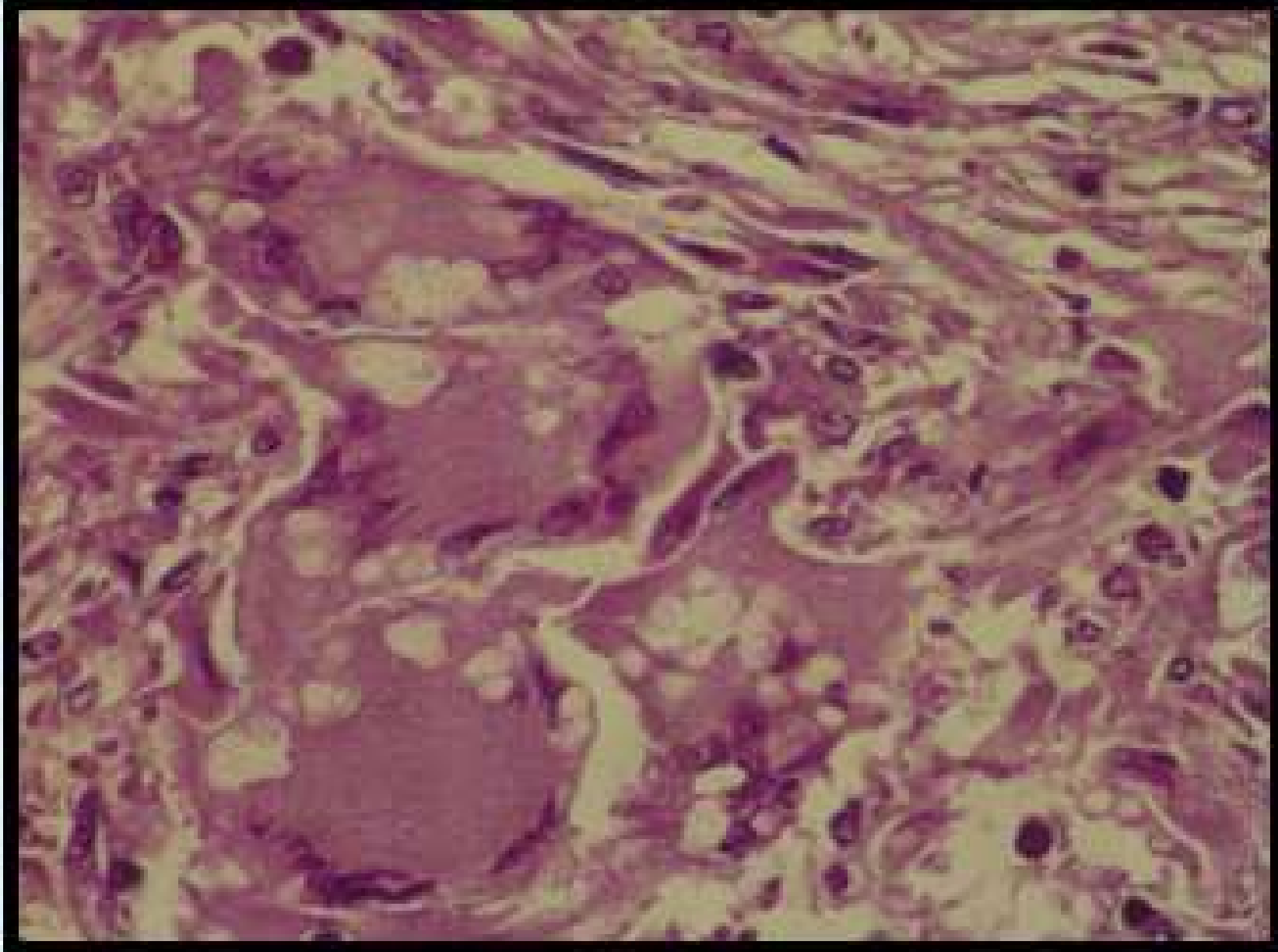





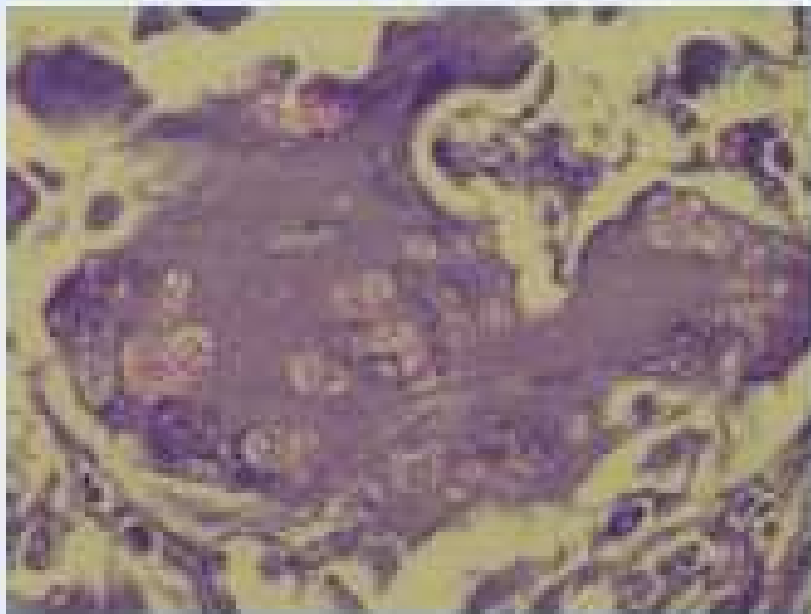








PAS

GROCOTT

